Brazilian Neurosurgery

ISSN 0103-5355

Arquivos Brasileiros de Neurocirurgia

Number 1 • Volume 40 • Pages 1–112 • March 2021

Evandro de Oliveira, 1945–2021

SBN
Sociedade Brasileira de Neurocirurgia

OPEN ACCESS

CELEBRATING 40 VOLUMES

Thieme

ISSN 0103-5355

Brazilian Neurosurgery
Arquivos Brasileiros de Neurocirurgia

ISSN 0103-5355

Brazilian Neurosurgery
Arquivos Brasileiros de Neurocirurgia

Volume 40, Number 1/2021

Brazilian Neurosurgery
Arquivos Brasileiros de Neurocirurgia

Editorial

Special Articles | Artigo Especial

Thieme Revinter Publicações Ltda

online www.thieme-connect.com/products

Case Reports | Relatos de Caso

The colored content of this issue is available online at www.thieme.com/bns.

Cover design: © Thieme
Cover image source: © Sociedade Brasileira de Neurocirurgia
(Polverini AD, Sola RAS, Bortoluzzi GF, et al. Meningioma of the fourth ventricle: literature review. Arq Bras Neurocir 2020; 39(1):5–11)

 Arquivos Brasileiros de Neurocirurgia is published four times a year in March, June, September, and December by Thieme-Revinter Publicações Ltda, Rua do Matoso, 170, Rio de Janeiro, 20270-135, Brazil.

Editorial comments should be sent to **journals@thieme.com**. Articles may be submitted to this journal on an open-access basis. For further information, please send an e-mail to openaccess@thieme.com. The content of this journal is available online at **www.thieme-connect.com/products**. Visit our Web site at **www.thieme.com** and the direct link to this journal at w**ww.thieme.com/bns**.

Arquivos Brasileiros de Neurocirurgia is an official publication of the Brazilian Neurosurgery Society (Sociedade Brasileira de Neurocirurgia) and the Portuguese Language Neurosurgery Societies. It is listed in LILACS and LILACS-Express (Latin-American and Caribbean Center on Health Sciencies Information), and Latindex (Regional Cooperative Online Information System for Scholarly Journals from Latin America, the Caribbean, Spain and Portugal). Thieme Medical Publishers is a member of the CrossRef initiative.

ISSN 0103-5355

Editorial

Tribute to Evandro de Oliveira

Eberval Gadelha Figueiredo[1]

[1] Sociedade Brasileira de Neurocirurgia, São Paulo/SP, Brazil

Arq Bras Neurocir 2021;40(1):1.

Eberval Gadelha Figueiredo
President of Brazilian Society of Neurosurgery
Editor in Chief, Brazilian Neurosurgery

"*Be not afraid of greatness; some are born great, some achieve greatness and others have greatness thrust upon them*." —William Shakespeare
"*We are what we repeatedly do. Excellence, then, is not an act, but a habit.*" —Aristotle
"*No man is truly great who is great only in his lifetime. The test of greatness is the page of history*." —William Hazlitt

In its edition of December 2019, *Brazilian Neursourgery* paid a homage to Evandro de Oliveira,[1] some of the words said by then will be repeated now when the entire neurosurgical community worldwide has been mourning this inestimable lost. In the current edition *Brazilian Neurosurgical Society* and *Brazilian Neurosurgery* pay its Tribute to one of the greatest neurosurgeons of all time, Dr. Evandro de Oliveira. The next pages will bring beautiful, sentimental and erudite reports that illustrate what Evandro de Oliveira represented for his family, friends and colleagues.

Evandro's work and personality inspired several young and experimented neurosurgeons thorough his life. Surgical technique and art were amalgamated in Evandro's hands. His unique surgical technique was the perfect summary that reunited art and technique in the operative treater. However, as said before, rather than art, the Evandro's School of surgery was Philosophy, as well.

Nothing less than perfection was tolerable to him. Perfect positioning, bloodless surgical field, precise microsurgery with no parasitic movements, stepwise revelation of the beauty of the brain anatomy, these were the Evandro's commandments. These facts imposed upon his pupils a great amount of pressure, whereas solidified a powerful mindset and established his surgical school. Many neurosurgeons in the world have been educated with this kind of surgical philosophy. His work put the Brazilian neurosurgery in a new and higher standard, that might be unreachable without his contributions. Our all gratitude to him. The next pages will tell more and better, nonetheless the Evandro's surgical school and achievements will echo for years to come. As an English essayist said: the test of greatness is the page of history.

Conflict of Interest
None.

Reference

1 Figueiredo EG, Rotta JM, Teixeira MJ. Evandro de Oliveira, "The brain whisperer". Brazilian Neurosurgery- Braz Neurosurg 2019; 38(04):253–253

Address for correspondence
Eberval Gadelha Figueiredo, MD, PhD, Sociedade Brasileira de Neurocirurgia, São Paulo/SP, Brazil
(e-mail: ebgadelha@yahoo.com).

DOI https://doi.org/10.1055/s-0041-1730265.
ISSN 0103-5355.

Thieme Revinter Publicações Ltda., Rua do Matoso 170, Rio de Janeiro, RJ, CEP 20270-135, Brazil

Special Article

Tribute to our Father, Evandro de Oliveira

Romina Leite da Costa de Oliveira[1] Sabrina Leite da Costa de Oliveira[1]

[1] Sociedade Brasileira de Neurocirurgia

Arq Bras Neurocir 2021;40(1):2–3.

Evandro de Oliveira was a great father. He lived his life based on two pillars: family (►**Figs. 1**, **2**, **3** and **4**) and work. He always succeeded in finding a balance between the two. He put in place what he taught us to: living with love; that would be the only way to achieve excellence in anything we do. And the outcome would be having more chances to experience the path of happiness.

The giant of his specialty – so tough, so demanding, so determined, so strong-willed – was a tolerant, generous, sensitive, sweet, loving, and warm father to his daughters. He was the inspiration of our lives!

Although he was the great master of Neurosurgery, so absorbed in his art, he found time and space throughout his life to be a wonderful father to Romina and Sabrina. Always close and present, he was ready to help solve any trouble we faced. He always got ahead of us and presented solutions to any problem he thought could harm or hinder us.

Fig. 1 Evandro and his family: Marina, Romina e Sabrina, Gainsville, Florida 1981.

Fig. 2 Evandro during New Year Celebration party with his family in Florianopolis, the city in which he was born (2006).

Committed to doing his best, to giving his best, to being his best, he wanted to see us fulfilled and happy the way we

Fig. 3 Evandro and Marina in his 73th anniversary. Sao Paulo.

Address for correspondence
Romina Leite da Costa de Oliveira, Sociedade Brasileira de Neurocirurgia
(e-mail: sergio.curcio@gmail.com).

DOI https://doi.org/10.1055/s-0041-1730266.
ISSN 0103-5355.

Thieme Revinter Publicações Ltda., Rua do Matoso 170, Rio de Janeiro, RJ, CEP 20270-135, Brazil

Fig. 4 Evandro in his microsurgical laboratory at Hospital Beneficencia Portuguesa de São Paulo (2019). From left to right: Sergio Curcio (his son-in-law), Romina, Marina and Sabrina.

chose to be and live. Evandro was even greater as a father than as a neurosurgeon. He achieved the purpose he established for himself when he was a boy: to be the best father to his kids. He gave himself to us with unconditional love. He was a friend, an accomplice, and a partner. Always attentive and open to the choices we made, he allowed us to be free. His only wish was that we were happy. No matter when or how, he accepted us even if he thought we were wrong. He was torn up just imagining that we could be suffering for any reason.

In his likewise grand way of demonstrating his love and affection, he was always with us. And this connection ensured that we have never felt in our lives his absence, as it would be expected considering his intense dedication to medicine.

He took pleasure in always giving us the best of everything. He knew us as no one else did! He nourished us with love, care, and gifts; he filled our house with flowers, delicacies, and above all, with his generosity to welcome and gather people.

While he loved operating and traveling the world sharing and exchanging experiences at uncountable medical conferences and symposia, he was happy to come home.

When he traveled alone for work, he limited himself to completing his professional commitments with excellence, and whenever he had a break, however small, he managed to fill his suitcases with gifts, showing us what we already knew: he was always connected to us. He always preferred to travel, however, with our mother by his side. Only then was he able to turn off the physician to be simply Marina's Evandro. Only with his wife beside him he fully enjoyed the places he traveled to.

When in São Paulo, he used to spent time just relaxing with us. Resting in a chair on the patio and smoking a cigar, was enough to recharge him.

When in Florianopolis, he enjoyed looking at the ocean as far as his eyes could see. "*Ingleses* beach" was a place he liked so much. He relaxed there enjoying a typical barbecue after a sea bath, savoring a dozen fresh oysters, petting his dogs, laughing with old friends and local family, and above all, enjoying the company of his life partner, our mother, Marina. He could spend months and months that way. And it was how he wished to live the last days of his life.

How privileged and lucky we are for having Evandro as our daddy.

How privileged and lucky our mom is for having Evandro as her husband.

Thank you for giving us life, dad!

We love you forever.

Conflict of Interest

None.

Special Article

Evandro de Oliveira and his Influence on Neurosurgery Worldwide and the US in Particular

On Behalf of Congress of Neurological Surgeons, CNS

Clemens M. Schirmer[1] Brian L. Hoh[2]

[1] Dept. of Neurosurgery, Geisinger & Geisinger Commonwealth School of Medicine, Danville, Pennsylvania, United States
[2] Department of Neurosurgery, University of Florida Gainesville, Florida, United States

Arq Bras Neurocir 2021;40(1):4–5.

Clemens M. Schirmer.

Brian L. Hoh.

Neurosurgery is a field where unwavering dedication to patient outcomes is the basis for success. We recently lost another giant in the field with Prof. Evandro de Oliveira. Every neurosurgery trainee at some point feels humbled by the complexity of performing surgery on the structures of the nervous system and achieving good outcomes. It is in these moments that we both remember the household names in neurosurgery and wonder how they went about achieving the confidence and skills that we now hear about.

Just like we associate Harvey Cushing and Walter Dandy with specific achievements, we connect Dr. Evandro de Oliveira with mastery of skull-base and intrinsic cerebral anatomy. Neurosurgical mastery is not a gift and merely builds on the incessant pursuit of knowledge and perfection. Pursuing multiple years of advanced training in neuroanatomy both in Florida (►**Fig. 1**) and Switzerland, he crafted a foundation for his career to come. In addition, he spent time as a clinical fellow with the luminaries of the time. Since then, he built his reputation as one of the preeminent surgeons in Brazil, attracting students and training other surgeons. From our perspective in the United States, we would only every so often get a glimpse of these achievements when Dr. de Oliveira would join us at our meetings and critically analyze his outcomes during numerous presentations and talks. Over the years, he published several highly cited papers on the microsurgical anatomy of the cavernous sinus, the temporal lobe, and the insula, giving the reader invaluable insights that readily translate to one's own practice and reveal the deep level of experience behind the work. The microsurgical laboratory that he founded in Sao Paulo was world-renowned in its own right and attracted thousands of colleagues from all around the world.

It cannot be overemphasized how much trainees and surgeons in the US would benefit from his presentations. The spectrum and advanced stages of disease he successfully tackled were awe-inspiring and setting a bar for trainees and practicing surgeons alike.

However, Dr. de Oliveira's premature passing points to another pressing issue – how do we pass on knowledge most effectively. Especially in the times of COVID-19, we have been both reminded that traditional ways of learning and knowledge-sharing will not be feasible but have also discovered other ways. Partnerships between the Sociedade Brasileira de Neurocirurgia (SBN) and the Congress of Neurological Surgeons (CNS) take shape for example in the highly successful joint webinar series allow master surgeons to reach unprecedented numbers of attendees and, in turn, enable surgeons from all over the world to attend and learn from different experiences and viewpoints. Finding new ways of collating and disseminating these unique experiences is the noblest of goals that our professional societies have. This shared goal is the main reason for CNS to partner with SBN in a variety of way ranging from our annual meeting to other

Address for correspondence
Clemens M. Schirmer, MD, PhD, Dept. of Neurosurgery, Geisinger & Geisinger Commonwealth School of Medicine, Danville, PA, USA
(e-mail: cmschirmer@gmail.com).

DOI https://doi.org/10.1055/s-0041-1730267.
ISSN 0103-5355.

Fig. 1 Evandro in one of the various hands-on training he did in the United States.

education endeavors. Hopefully, it would be aligned with the plans that Dr. de Oliveira visibly set for himself decades ago when he embarked on his journey as a neurosurgical educator.

Conflict of Interest
None.

Special Article

In Honor of Evandro de Oliveira, MD
"Thanks for having brought us to the future"

Guilherme Carvalhal Ribas[1]

[1] Department of Neurosurgery, Neuro Ribas, São Paulo/SP, Brazil

Arq Bras Neurocir 2021;40(1):6–7.

Guilherme Carvalhal Ribas, MD, PhD

Evandro was graduated at the Faculdade de Medicina da Universidade Federal de Santa Catarina, and did his neurosurgical residency in Montevideo, Uruguay, with Prof. Ramon Arana, in a neurosurgical unit famous for its neurological and radiological backgrounds.

But it was a brief stay in Zurich with Prof. Yasargil in 1980, and his long fellowship at Prof. Rothon's lab in the University of Florida during 1981 and 1982, that defined his neurosurgical profile. These experiences happened very opportunely since they took place when Evandro already had a quite good neurosurgical experience acquired in Florianopolis, and constituted the base of all his posterior development already in São Paulo.

I had the privilege to meet Evandro in July 1982 when he was coming back from. His fellowship with Prof. Rothon in Gainesville, and I was coming from mine with Prof. John Jane at the University of Virginia in Charlottesville. We started to work together at the Hospital Beneficiência Portuguesa in São Paulo (►**Fig. 1**), where Prof. Raul Marino Jr. was starting the Instituto Neurológico de São Paulo, a very well-equipped neurosurgical center for our standards at that time due to Prof Raul efforts, and which then flourished particularly with Evandro's driving force and contributions. Subsequently we started to work together also at the Hospital das Clínicas of the University of São Paulo, also under Prof. Raul Marino Jr.

Evandro was with the dynamism of his 37 years old, and as his first 1st assistant during the forthcoming years I had the privilege to witness his initial already exquisite development. He was blooming, starting to put together Prof. Yasargil's microsurgery technique with the microanatomy he learned at Prof. Rothon's lab. I remember Evandro going back and forth always with Prof. Yasargil Microsurgery Volume I at the time, and also clearly remember one episode, after a CP angle tumor operation, saying to him that the surgery was superb, and he answering me "I also did not know I could do it this way!"

Parallel to the thousands of patients he aided with the art of his technique allied to his anatomical knowledge and scientific contributions, I understand Evandro's major legacy as having being the one who consolidated worldwide Prof. Yasargil's microsurgery philosophy and technique together with the then new intracranial anatomical universe unveiled by Prof. Rothon's fellows, of which he was his major exponent. Within our technological era, Evandro brought anatomy back to the center of our specialty. We learned with him to think and to operate anatomically… His anatomical and surgical correlations became his trademark both in his neurosurgical practice and his publications and lectures.

But his main tools were not his magnificent anatomical knowledge or his finest skills, his main tools were his endless pursuit of excellence and, above all, his passion for neurosurgery. His achievements definitely came through his strong personality: Evandro was very charming and friendly, but also tough and difficult… And his main sources of energy undoubtedly were his lovely wife Marina, his daughters Romina and Sabrina and, more recently, his granddaughter Maria Eduarda.

Evandro, in the name of all our community, thanks for having brought us to the future of Neurosurgery you devised and were able to build!

- Professor Livre-docente of Surgery, Department of Surgery, University of São Paulo Medical School
- Full Professor, Albert Einstein Medical School, São Paulo, Brazil

Address for correspondence
Guilherme Carvalhal Ribas, MD, PhD, Department of Neurosurgery, Neuro Ribas, São Paulo/SP, Brazil
(e-mail: guilherme@neuroribas.com.br).

DOI https://doi.org/10.1055/s-0041-1730268.
ISSN 0103-5355.

Thieme Revinter Publicações Ltda., Rua do Matoso 170, Rio de Janeiro, RJ, CEP 20270-135, Brazil

Fig. 1 Profs Evandro de Oliveira and Guilherme C. Ribas at the Microsurgical Laboratory at Beneficencia Portuguesa de São Paulo, the place he built and loved.

- Visiting Professor of the Department of Neurosurgery of the University of Virginia, USA
- Co-Diretor of the annual Cambridge Lectures in Neurosurgical Anatomy, Cambridge, UK
- Neurosurgeon at the Hospital Israelita Albert Einstein, São Paulo, Brazil

Conflict of Interest
None.

Special Article

Evandro's Tribute

Helmut Bertalanffy[1]

[1] Department of Vascular Neurosurgery, International Neuroscience Institute, Hanover, Germany

Arq Bras Neurocir 2021;40(1):8–11.

Helmut Bertalanffy
Hannover, March 2021

With sorrow and grief in my heart am I writing these lines, and my thoughts are now with Evandro's family, especially with Marina.

I met Evandro more than 2 decades ago, when I already knew about him from my friend Toshio Matsushima, Japan. Many years ago he spent with Toshio a certain time period in Florida at Dr. Al Rhoton's neuroanatomical lab. Both lay there an important foundation stone for their future work.

Thereafter, I had the opportunity of meeting Evandro what seems countless times at various neurosurgical congresses and workshops in many parts of the world. This surely created quite strong friendship ties between us. However, as we used to live quite far away from each other, not meeting personally for even a longer period of time did not have much significance because it was expectable that we might see each other again on some occasion in the future. The recent information about his passing away deeply moved me because I realized that there will be no such future occasion, and I will never have the chance to meet Evandro again. Together with many other international colleagues I lost a good friend for ever. Such a painful experience!

I am sure that other colleagues who knew Evandro better than me will adequately evaluate and appreciate his

Fig. 1 Professors Helmut Bertalanffy, Evandro de Oliveira and Ossama Al- Mefty in St Louis – USA, 2008.

Address for correspondence
Helmut Bertalanffy, MD, Department of Vascular Neurosurgery, International Neuroscience Institute, Hanover, Germany
(e-mail: bertalanffy@ini-hannover.de).

DOI https://doi.org/10.1055/s-0041-1730269.
ISSN 0103-5355.

Thieme Revinter Publicações Ltda., Rua do Matoso 170, Rio de Janeiro, RJ, CEP 20270-135, Brazil

Fig. 2 Evandro scrubbing, Braga- Portugal, 2010.

Fig. 4 Evandro working during a travel in Japan.

Fig. 3 Professors Helmut Bertalanffy and Evandro de Oliveira in Foz do Iguaçu, Brazil, 2008.

Fig. 5 Professors Helmut Bertalanffy, Evandro de Oliveira, Carlos Alegria and Guilherme Carvalhal Ribas, Braga – Portugal, 2010.

academic and professional life-time achievements and his extraordinary contributions to neurosurgery that cannot be described in only few lines. But apart from such objective facts, Evandro will always remain in our memory for many other reasons. There is no doubt that he was a technical master of his profession and a famous representative of the „global" neurosurgical community. But what made Evandro outstanding? It was not only his high professional level, it was also his exceptional character and warm personality. Looking back into the past, I always admired Evandro for his enthusiasm and affinity for neuroanatomy, for his three-dimensional imagination, for his unique presentations from which not only young but also experienced neurosurgeons like me could learn something new, for his elegant style of presenting a certain surgical field in direct comparison with an illustrative anatomical dissection, for his constant wish to share his profound experience with others, for his technical skills exemplified by the clearly structured and bloodless way he carried out his neurosurgical procedures, for his qualities as clinician and teacher, and for his prudent way of communication mixed with humor, just to name a few of his strong points.

I enjoyed sharing with Evandro the membership in the World Academy of Neurosurgery (WANS) and in the Nominating Committee of the World Federation of Neurosurgical Societies, among others. I will not forget our many meetings in various places of Japan, in the USA (e.g. New Orleans, St. Louis), in Argentina (with our families), in Portugal (Braga, together with Guilherme Ribas), in France (Paris) and many other places, and of course in Brazil, for instance 2008 at the neurosurgical meeting organized by Evandro in Iguassu.

If I could tell Evandro directly some farewell words, these would perhaps be: "it was a privilege knowing you, my friend Evandro; I will miss you; I will miss your contagious smile; I will miss your professional inspiration; you were a great man, a superb and energetic neurosurgeon; we will not forget you; be sure that people will always hold you in the highest regard!" (►**Figs. 1–6**).

Fig. 6 Helmut Bertalanffy, Evandro de Oliveira and spounses, Marina and Atsuko, Argentina, November 2010.

Conflict of Interest
None.

Special Article

My Tribute to Evandro de Oliveira

Hung Tzu Wen[1]

[1] Faculdade de Medicina da Universidade de São Paulo, São Paulo/SP, Brazil

Arq Bras Neurocir 2021;40(1):12–13.

Hung Tzu Wen

When I think of Dr. Evandro de Oliveira, the overwhelming feeling is gratitude, as he changed my career and my life to beyond my wildest expectations.

I met Dr. Evandro in 1990 when he joined the Division of Neurosurgery of Hospital das Clínicas at University of São Paulo Medical School as head of vascular neurosurgery, and I was a 3rd year resident. He was the rising star in neurosurgery, that was all I knew about him at that time. Soon, everything we used to do in the operating room changed, starting from the layout of the tables, the position of the surgical personnel and the microscope, a plastic bag was added to make the patient draping waterproof, hemostats for stopping the bleeding from the skin were replaced by meticulous coagulation using bipolar forceps; interfascial dissection for preserving frontal branch of the facial nerve, the use of fish hooks for retraction, the location of each burr hole and the standardized pterional approach were presented. Sharp dissection of the sylvian fissure and basal cisterns, and the use of bipolar forceps, microscissors, and suction tubes of different lengths became routine practice. Foot and mouth switches for surgeon were introduced to control the microscope without withdrawing the hands from the surgical field; hydraulic surgical stools became part of surgeon's armamentarium. It was the beginning of the era of anatomy-based microsurgery in our institution, a mesmerizing experience for me.

He was the neurosurgeon who best understood and applied the philosophies of two giants in neurosurgery: the neuroanatomical school of Dr. Albert L. Rhoton Jr., and the microsurgery school of Dr. M Gazi Yasargil. For him, neurosurgery is about passion and art: surgery is not merely a manual task, it is a piece of art, and depending on how you devote your attention to it, your surgery can become a masterpiece.

I soon picked him as my role model in neurosurgery; I wanted to follow his footsteps, I wanted to be like him.

After finishing my residency program, I became his fellow, and I had the opportunity to closely learn from him for 7 months. Because of his recommendation, I became research fellow of Dr. Rhoton, where I spent 2,5 years of intense learning in neuroanatomy; after 6 months of fellowship, Dr. Evandro invited me to help him to design a new course "Sulci Gyri and Ventricles"; the course turned out to be successful, but I remember the stress and the fear- I did not want to fail him.

I returned to Brazil in 1996 and I started working with him in his private practice and at Hospital das Clínicas as member of epilepsy and vascular teams, position that I hold to date.

Over the years, even after I left his private practice in 2001, he continued to give me opportunities to travel with him, to attend meetings, and to help him in his courses around the world. I always was impressed to see how respected he was, no matter where we were.

He was known for being firm and determined, he always stood by what he believed was right, but at the same time, he was very generous too. Not only did he help me, but he also helped and inspired many other disciples from different parts of the world, especially from the countries he most visited: Argentina, Bolivia, Chile, China, Colombia, Italy, Japan, Mexico, Paraguay, Portugal, Russia, Spain, South Korea, Taiwan, Turkey, Uruguay, and USA. They fully understood his philosophy e they have successfully applied it in their daily practice. He has certainly saved and changed the lives of thousands of patients, directly and indirectly.

We kept our friendship with a lot of respect for each other throughout the years. In my weekly visit to him during his illness, we talked for hours about anything – politics, future Neurosurgery meetings, the stock market, Covid-19, etc. We

Address for correspondence
Hung Tzu Wen, MD, PhD, Faculdade de Medicina da Universidade de São Paulo, São Paulo/SP, Brazil
(e-mail: wenht@uol.com.br).

DOI https://doi.org/10.1055/s-0041-1730270.
ISSN 0103-5355.

Thieme Revinter Publicações Ltda., Rua do Matoso 170, Rio de Janeiro, RJ, CEP 20270-135, Brazil

also talked about the good memories we shared from our gastronomy tours in different countries. However, he was especially happy, and in his element when I showed him some difficult cases, and he would help me with his enormous knowledge and wisdom.

It has been truly a great honor and privilege for me to be his disciple, to work under his guidance, and to have his friendship for more than 30 years. Dr. Evandro is gone, but his guiding light (as his middle name "Luz" means) remains. Please, watch over us.

With my eternal admiration and thankfulness.

Conflict of Interest

None.

Special Article

Evandro de Oliveira, the Rock of Florianopolis

Jacques J. Morcos[1,2]

[1] Cranial Neurosurgery, Jackson Memorial Hospital, Miami, Florida, United States
[2] Professor and Co-Chairman, Director of Cerebrovascular and Skull Base Surgery, Department of Neurosurgery, University of Miami, Florida, USA

Arq Bras Neurocir 2021;40(1):14–15.



Jacques J. Morcos, MD, FRCS, FAANS

Why do we exist? How did it all begin? Can we even imagine what nothingness would feel like? Generations of philosophers have pondered these questions and the mystery lingers on. Humans seem equipped with neither the necessary intellect nor imagination to understand their own fate. The inevitability of death, the tragedies of diseases and wars, the pervasiveness of suffering and injustice on this little blue planet, pull us constantly and collectively towards the abyss of despair, the darkness of existential nihilism. Billions are born and billions have died, the cycle continues, and all that *Homo sapiens* has managed to do, in its quest for meaning and its hunger for relevance, is to celebrate those few men and women among us who break the mold, achieve extraordinary things, and leave an impact. Every breath is precious and every life is sacred, yet some lives well lived simply rise above the rest and inspire the human psyche. Some lives are outliers, are memorable, are infused with such a unique mix of ingredients that they give the rest of us reason to pause, admire and reflect. These lives are the tide that lifts up all struggling boats. These lives are catalysts of human happiness, recipies for human purpose and the very essence of human hope. Most other ordinary lives are but pebbles that leave small ripples in a pond, but these special lives are giant boulders crashing into oceans. They generate an unstoppable wave of influence. On February 11, 2021, one such boulder crashed into the Atlantic Ocean, off the coast of Florianopolis. That boulder had a great life, a life worth celebrating. That rock was called Evandro.

The Evandro tsunami did not start with his death. It had started decades before, when this young gifted Brazilian neurosurgeon became an international beacon for refined microneurosurgical skill, uncompromising love for surgical esthetics, unrivalled passion, unremitting dedication, and unequalled conviction. From the first moment when Evandro stood up behind a lecturing podium, sat down at a dissecting station or braced his arms at the head of an operating table, with his eyes kissing the binoculars of a microscope, the wave started to swell. This rock, this boulder was made of great ingredients: part Yasargil and part Rhoton, yet pure originality. If Rhoton may be thought of as the quintessential neurosurgical "archeologist" who brilliantly uncovered the countless hidden treasures of the brain, Evandro, through skill, predisposition and temperament, is unquestionably the "architect" and "artist" who knew what to do with these treasures. He studied and watched other masters intensely, he refined his art, blazed a trail and founded a massive school of followers. Why did so many follow? After all, he can be dogmatic, uncompromising, even harsh on those less driven, less ambitious. Why? Because his flag is planted in a pure and fertile soil, the soil of undeniable truth and beauty: the structure and mystery of that most complex collection of matter in the universe, the brain. Because to follow him is to follow excellence, courage, the desire to heal and the irresistible impulse to share the wisdom gained along the path. The world would be indeed a much better place if these were its universal motivators, if mediocrity, selfishness and corruptibility were not so pervasive.

Marina, Romina and Sabrina have lost a husband and a father. They have witnessed this giant of a man, this boulder who crushed mountains and moved oceans conclude his earthly life in physical immobility, struck by a disease of the brain, that organ he understood so well. This is cruel and twisted irony, this is poetic injustice. Yet this prophet had done by then all the preaching he needed to do, all the operating he could have accomplished. His masterpieces live on in his writings, his operative videos, his lectures, his patients and his fervent disciples who will undoubtedly now flood the world with their beautiful eulogies. But he

Address for correspondence
Jacques J. Morcos, MD, FRCS(Eng), FRCS(Ed), FAANS, Cranial Neurosurgery, Jackson Memorial Hospital, Miami, FL, USA
(e-mail: jmorcos@med.miami.edu).

DOI https://doi.org/10.1055/s-0041-1730271.
ISSN 0103-5355.

Thieme Revinter Publicações Ltda., Rua do Matoso 170, Rio de Janeiro, RJ, CEP 20270-135, Brazil

expects more of them, of all of us. In his last days, you could see it in his eyes. Even when he could not move and could not speak, his mind was talking to us, his neurosurgical peers, and seemed to say:

"*If it is not beautiful, it is not true. If you don't do it with pride, with love and with refined knowledge, then don't do it at all. If it is just work for you, then you are missing out on life. If it is not Art, then it is not Science. Please ride the wave, but be bold and be a boulder. Go crash onto other oceans. Carry it forward. You don't have to honor me, but please don't forget what I stood for*". I hope I was not the only one listening.

Conflict of Interest
None.

Special Article

We Lost the Greatest... Our Maradona (or Pele)

Jorge Mura[1]

[1] University of Chile, Santiago, Chile

Arq Bras Neurocir 2021;40(1):16–17.

Prof. Jorge Mura, MD, IFAANS, FACS
Master of Chilean Neurosurgery.
Professor of Neurosurgery. University of Chile.
Chief of Cerebrovascular and Skull Base Surgery. Institute of Neurosurgery Asenjo.
President Elect 2021-2023. Chilean Society of Neurosurgery.

We lost one of the most gifted neurosurgeons of modern history in neurosurgery, and I am not stating that just because I happened to be one of his Fellows (year of 1998), but because I really knew him in and out of scrubs. I remember him being difficult and distant at times, and extremely demanding. He had a good and bright side which was known by most, but he also had his dark days, which only a few of his inner circle knew. However Dr. Evandro de Oliveira was a necessary person for his time, worked all of his life for neurosurgery and left us while fighting heroically against a terrible disease such as amyotrophic lateral sclerosis, which left him without one of his most precious virtues, his voice. With the power of the spoken word, he was able to convince anyone easily. When in 1996 I heard him speaking about the beauty of vascular neurosurgery, microsurgical anatomy and micro-neurosurgery I felt the calling from within my soul, which continues to be true now 20 years later.

We had worked continuously with Dr.Evandro throughout my career which started in 1998. Shortly after coming back from Brazil we kept our collaboration active with more than 100 article reviews and some original research articles I had the honor to co-author with him. Dr de Oliveira came to Chile in the year 2000, at the time that I was presenting my candidacy to enter the Chilean neurosurgical Society. He was a frequently invited as honored guest in our Chilean neurosurgical Congress, which we acknowledged with a *foreign honorary member* distinction in 2007. I vividly remember when he came to Chile for the Latinamerican Neurosurgery Congress in 1998. During the Congress I felt blessed to make a connection with him which finally brought me to Brazil with him for a few months: an experience that would change my life.

Dr. de Oliveira was an extremely generous man, a person that knew how to help those who had passion to improve themselves within neurosurgery. He was also intolerant to mediocrity and conformism. His excellence and body of work became the beacon of Latin American neurosurgery in the world's map.

His passing leaves a huge void in me. There are great friends that are suffering much more than myself however, such as Pablo Rubino. Dr Rubino was one of his closest disciples and his" neurosurgical son". My thoughts also go for his great collaborators such as Helder Tedeschi and Wen Hung Tzu.

Dr. de Oliveira was able to combine the microsurgical mastery of Dr. Yasargil with the exceptional neuroanatomy teachings of Dr. Rhoton, a combination I consider the core of neurosurgery.

He left an incredible legacy of Latinamerican neurosurgery as well as worldwide neurosurgery and it is the duty of all of us, but specifically of his disciples, to honor his memory. I would urge anyone that is passionate about microneurosurgery, vascular neurosurgery, skull base or even those who, from other subspecialties, love *good* neurosurgery to not settle for less than perfection. I urge you to strive for surgical excellence and to respect and treat our field the way Dr de Oliveira taught us to: be righteous, prepare well for surgery, know how to defend a surgical strategy, a novel idea, respect for our colleagues and our discipline, be passionate, and above all, to love neurosurgery.

Dr de Oliveira was an extremely charismatic figure, and even though at the end he lost his voice, he continues alive within the field he so well helped developed. We recently honored him through a symposium of the American society of neurosurgery in San Diego, and through the creation of the microsurgical laboratory of the "Beneficiencia Portuguesa de Sao Paulo", which is named after him. In all of these events, we - his colleagues and

Address for correspondence
Jorge Mura, MD, IFAANS, FACS, University of Chile, Santiago, Chile
(e-mail: jorgemuramd@gmail.com).

DOI https://doi.org/10.1055/s-0041-1730272.
ISSN 0103-5355.

Thieme Revinter Publicações Ltda., Rua do Matoso 170, Rio de Janeiro, RJ, CEP 20270-135, Brazil

disciples- as well as all the souls he touched directly or indirectly gave him a deeply felt acknowledgement and kept his voice alive.

I would like to underline one of Dr de Oliveira's greatest obsessions: teaching. He had the habit of recording all of his surgeries to evaluate all his surgical mistakes (even in his most perfect operations), which he then would use during his famous courses. I was lucky enough to attend several of his courses, which taught me greatly. I have adopted his passion to teach, which I have applied towards my Fellows, residents and trainees. I am profoundly grateful to Dr de Oliveira for showing me the power behind teaching and investing in future generations. I am convinced that this valuable lessons were fundamental in my professional development, and especially in my last recognition as "Maestro de la Neurocirugia" of Chile last year… thank you Dr de Oliveira.

Dr de Oliveira's legacy is international. Here in Chile we have a deeply rooted influence from him, not only in the way we think about neurosurgical technique but also in the form of fellowships inspired after him, through which I trained close to 50 neurosurgeons since 2000.

I believe his passing is an enormous loss. However Dr de Oliveira is immortal in neurosurgery, as his teaching will pass over generations and we, his trainees, will make sure his name and memory stand proud for the generations to come.

The day I knew of Dr de Oliveira's passing was especially heartfelt for me. I happened to be operating an arteriovenous malformation, which was one of Dr de Oliveira's preferred surgeries. During surgery I had vivid memories of the surgical moves he had taught me, which guided me during the operation, just like if he himself would speak to me from above. He used to call me one of *"Evandro's Boys"* and now I feel a huge responsibility to persist in my strive for teaching and technical perfection as these were the fields he taught me the most. His generosity is unparalleled. Although I know this quality of him will be declared by many, I had the opportunity to experience his human qualities and generosity during a very hard situation back in 1998, which brought me very close to him, and helped develop myself as the neurosurgeon I am.

I'd like to conclude by expressing my most heartfelt and sincere gratitude for Dr de Oliveira, and for all the good and tough moments I shared with him, which equally made me better as a person and neurosurgeon. In summary Dr de Oliveira was an absolute master, a giant neurosurgeon, great person and embodied that which in our culture like to call "an Imprescindible"… He is our Maradona, our Pele… the greatest of all is gone.

Conflict of Interest

None.

Special Article

Evandro de Oliveira Son of Kings, Leader of Leaders

José-Antonio Soriano-Sánchez[1]

[1] President of the Latin American Federation of Neurosurgery Societies

Arq Bras Neurocir 2021;40(1):18.

José-Antonio Soriano-Sánchez. President of the Latin American Federation of Neurosurgery Societies

Any set of phrases or speeches run the risk of being insufficient or incomplete when the intention is to describe the greatness of Professor Evandro de Oliveira and even more so when it comes to dimensioning the enormous legacy he has left for Latin America.

Outstanding human qualities, such as assertiveness, inquisitive personality, humility, born talent, dedication, and exceptional intelligence, allowed him to be adopted by some of the Fathers of history, such as Gazi Yasargil, Alberto L. Rothon Jr., and Vinko Dolenc, among many others., personalities that not only inspired him and fostered his passion for specific fields of neurosurgery but also instilled in him that peculiar and methodical way of being and acting, on elementary bases and without secrets, but highly effective; hard work, the permanent study of anatomy feedback, patience, love of what is done, research and publications.

From Evandro de Oliveira, we can analyze multiple facets; however, a crucial one was the development and mastery of the methodology of teaching and learning of vascular and skull base surgery and the foundation of his school, from which they have emanated innumerable amount of outstanding students from practically all the countries of Latin America who today are leaders of positive action in their localities and who impact the prognosis of millions of patients every day. Therefore, we could conceptualize Evandro as a son of kings and leader of leaders, speaking of neurosurgical lineage.

On behalf of the Latin American Federation of Neurosurgery Societies, our eternal recognition for Evandro de Oliveira, undoubtedly an immortal of Neurosurgery who will always live in our memories.

Conflict of Interest
None.

Address for correspondence
José-Antonio Soriano-Sánchez, President of the Latin American Federation of Neurosurgery Societies
(e-mail: neurojass@icloud.com).

DOI https://doi.org/10.1055/s-0041-1730273.
ISSN 0103-5355.

Thieme Revinter Publicações Ltda., Rua do Matoso 170, Rio de Janeiro, RJ, CEP 20270-135, Brazil

Special Article

Evandro de Oliveira

M. Gazi Yaşargil[1]

[1] Department of Neurosurgery, College of Medicine, University of Arkansas for Medical Sciences, Little Rock, Arkansas, United States

Arq Bras Neurocir 2021;40(1):19–20.

M. Gazi Yaşargil

Evandro de Oliveira skilled neurosurgeon, renowned teacher, and loyal friend.

Evandro and I met many times at congresses and symposia, where our discussions centered mainly on our professional activities. We could occasionally disagree, but the cordial and mutual respect fundamental to our relationship, always remained intact. Evandro's congenial expression and pleasant temperament always insured a relaxed atmosphere.

In the following lines I will reminisce on just a few of my memories of Evandro.

At a congress in USA I first met Evandro, where his neuroanatomy lecture, illustrated by excellent drawings and photographs, impressed me immediately. I arranged for him to lecture at the 1991 congress of the Turkish Neurosurgical Society in Çeşme, Turkey. His neuroanatomy lecture was praised and highly appreciated by the participants. Evandro was accompanied on a tour of the surrounding cultural sites, and, after the congress, we travelled together to Istanbul, where we spent one Sunday morning, very early, visiting Sultan Ahmet mosque and Hagia Sophia museum, and wandering leisurely between the pools and pillars of the Byzantine underground cisterns, to the sounds of classical music and the splash of 'rain- drops' from the ceiling as they entered the pools.

Before returning to Brazil, Evandro spent one day with us in the department of neurosurgery, University Hospital Zurich, observing surgery and meeting with faculty and residents. I encouraged him to also visit Professor Dolenc in Ljubljana, to observe skull base surgery.

After moving to Little Rock, Evandro invited me to San Paolo as guest speaker, where I toured his well-equipped training laboratory (►**Fig. 1**) and observed his skills at a cerebral AVM surgery. Dianne and I were welcomed by Evandro and Marina to their home, and enjoyed relaxing conversations and discussion during a delicious dinner, especially prepared by Marina.

We have met on many occasions since, most frequently in Brazil, USA, and in Istanbul. The last time I saw Evandro was in August 2017, in Istanbul, at the congress of the World Federation of Neurosurgical Societies. Over the years, each encounter roused in us stimulating discussion and exchange of experiences and ideas.

I recognize in Evandro his dedication to microneurosurgery, and his aspirations to teach the fine elements of micro-techniques. To be inflicted with such a debilitating



Fig. 1 Profs Evandro de Oliveira, M. G. Yarsagil and Raul Marino Jr at the Microsurgical Laboratory of Hospital da Beneficencia Portuguesa, São Paulo, with Evandro's fellows.

Address for correspondence
M. Gazi Yaşargil, MD, Department of Neurosurgery, College of Medicine, University of Arkansas for Medical Sciences, Little Rock, AR, USA
(e-mail: drture@yahoo.com).

DOI https://doi.org/10.1055/s-0041-1730274.
ISSN 0103-5355.

disease at a young age was a tragedy. Nevertheless, I admired Evandro's strength of character to persevere, as he surmounted barriers invading his life, and attempted to defeat his misfortunes.

His presence as a respected neurosurgeon, with his courteous character will be greatly missed at future gatherings of the neurosurgical community. His personal experiences, knowledge, and reflections will no longer heighten and augment our scientific programs.

To Marina, I convey my respect and admiration for Evandro, and offer my sincere condolences.

Conflict of Interest

None.

Special Article

Tribute to Evandro de Oliveira

Michael T. Lawton[1]

[1] Barrow Neurological Institute, Phoenix, Arizona, United States

Arq Bras Neurocir 2021;40(1):21.

Michael T. Lawton, MD
Phoenix, AZ

Lou Gehrig played major league baseball with the New York Yankees for 17 years and his streak of 2,130 consecutive games stood as monument in baseball history to strength and dedication to the game despite injury and adversity, earning him the nickname "The Iron Horse." He was diagnosed with amyotrophic lateral sclerosis and retired from the game after noticing loss of strength, slipping and falling, and dyscoordination. It seems that Evandro's passing was from the same or a similar progressive neurodegenerative disease, which is not only undeserved but also tragically cruel for a man so gifted with motor control, dexterity, and grace. Who among us wasn't mesmerized by his operative dissections that seemed almost cadaver-like in their cleanliness and perfection? It is difficult to lose Evandro under any circumstances and feels wrong to lose him in this way.

A decade ago, Evandro invited me to teach a course with him in Valencia, Spain. We spent an entire week together lecturing on aneurysm surgery and performing cadaver dissections in the lab. We had not worked together previously. I was never his trainee and had gotten to know him only through meetings and shared interests, particularly on the topic of AVMs. He seemed to take a liking to me as someone who also loved mincroneurosurgery and would take up the crusade to preserve it in the face of endovascular attack and relentless market forces. The week in Valencia became my unofficial fellowship with Evandro. He taught me the transcavernous approach, which I never learned as a resident; he sold me on supracerebellar-transtentorial approaches to temporal lobe lesions in the sitting position; he shared his ideas on paraclinoidal aneurysms and his vast experience with brain AVMs. He lectured for hours every day in a language that I could not understand, but I absorbed it through his slides, videos, gesticulations, and the occasional words in English.

The last time I saw Evandro was at the de Oliviera Symposium in April 2019 in San Diego. Unable to finish dressing himself and not wanting to miss any talks, he wandered into the lobby of the hotel en route to the conference room holding his untied tie in his hand. I pulled him aside and tied it for him. My first thought was that this disease had our beloved Evandro squarely in its merciless grip and there would be no escape. My second thought, as I entered the conference room with Evandro and saw countless faces light up at the sight of him, was that this man was deeply loved by his peers. Evandro had a hard time speaking at the time of his Symposium and could not articulate the depth of his emotions, but I was reminded of what Lou Gehrig said in his now famous speech at Yankee Stadium on the day he retired: "I am the luckiest man alive." Evandro must have felt lucky to have vanquished so many aneurysms and AVMs, to have earned the admiration and respect of his peers, and to have become the godfather of Brazilian neurosurgery. Like Gehrig, Evandro was the iron horse of his domain and soldiered on tirelessly with strength and dedication to make his mark on neurosurgery. Thank you Evandro for the mark you made on me, and may you rest in peace while we continue the crusade.

Conflict of Interest
None.

Address for correspondence
Michael T. Lawton, MD, Barrow Neurological Institute, Phoenix, AZ, USA
(e-mail: michael.lawton@barrowbrainandspine.com).

DOI https://doi.org/10.1055/s-0041-1730275.
ISSN 0103-5355.

Thieme Revinter Publicações Ltda., Rua do Matoso 170, Rio de Janeiro, RJ, CEP 20270-135, Brazil

Special Article

Tribute to Evandro de Oliveira

Ossama Al-Mefty[1]

[1] Brigham and Women's Hospital, Neurosciences Center, Harvard Medical School, Boston, Massachusetts, United States

Arq Bras Neurocir 2021;40(1):22–23.

Ossama Al-Mefty, MD

In the mid-80s, I was listening to a lecture on ophthalmic aneurysms and what a beautiful surgery it was. In the next 35 years, I came to know what a beautiful person the speaker Dr. Evandro was. There are not many places in this world which we have not been together (►**Fig. 1**). We did always manage to sneak behind the conference center or find a special dinner where we could with open mind and caring heart exchange deep thoughts of the meaning of life, humanity, profession, friendship, and family. I always came with a renewed hope and aspiration, he was an inspiration. I share with every neurosurgeon the admiration of Dr. Olivera's accomplishments, mastery, teaching, and leadership. We shared the passion and devotion to microneurosurgery. Our thrill of conquering Everest's top was to clip aneurysm of the basilar artery top. But I cherish the most a bond of trust. I always felt comfortable and secure with Evandro because he said what he thinks and did what he said. This

Fig. 1 Together at the beginning of a beautiful journey that has no end. Sao Paulo by Evandro Microsurgical Laboratory.

Address for correspondence
Ossama Al-Mefty, MD,
Brigham and Women's Hospital,
Neurosciences Center, Harvard
Medical School, Boston, MA, USA
(e-mail: almeftyossama@bwh.
harvard.edu).

DOI https://doi.org/
10.1055/s-0041-1730276.
ISSN 0103-5355.

Thieme Revinter Publicações Ltda., Rua do Matoso 170, Rio de Janeiro, RJ, CEP 20270-135, Brazil

bond is a lot stronger than friendship, colleagueship, or brotherhood. When I visited him at his home, it felt like I am with my family. How can I have remembrance if I do not forget? Evandro will always be with us.

Conflict of Interest
None.

Special Article

Dr. Evandro De Oliveira, Genius and Master of Neurosurgery

Pablo Augusto Rubino[1]

[1] Hospital El Cruce, Buenos Aires, Argentina

Arq Bras Neurocir 2021;40(1):24.

Dr. Pablo Augusto Rubino (collaboration Dr.Juan Santiago Bottan) Buenos Aires, Argentina.

"Doctor Evandro" was undoubtedly one of the most influential neurosurgeons of the last half century and marked a milestone in neurosurgery, not just in Brazil, but worldwide. Specifically in Argentina, we can certainly say that he revolutionized neurosurgery in our country.

His impact on Argentine neurosurgery was beyond measure, changing the way in which we tackle microneurosurgery. He was able to transmit his formidable surgical technique, which turned out to be the fruit of the perfect combination between Dr. M. G. Yasargil's microsurgical precepts and Dr. A. Rhoton's applied neuroanatomy. This, in addition to the influence received from two of his mentors, fellow pioneers Drs. Raul Carrea and Charles Drake, led to the genesis of a surgical school that made it to these shores and is meant to last over time. His legacy is not limited to his courses at the *Hospital de la Beneficencia Portuguesa* (to which more than 500 Argentine neurosurgeons attended over the years) but also to his multiple participations in our scientific meetings, (especially in *Neuropinamar*, with more than 20 attendances) and lately, in the live surgery courses held at the *Hospital El Cruce*, where we were fortunate enough to share his exceptional skills and neurosurgical wisdom.

Evandro was the one who best figured out how to transfer the "cold anatomy" of the lab to the challenging arena of real microsurgery, solving complex cases with elegance and safety and setting new standards for what can be achieved in this field. His surgeries were, therefore, the natural consummation of his high scientific knowledge and his devotion for beauty. The result, a true work of art.

Many of us were privileged to learn directly (and indirectly) from him. The most interesting things is that not only did we learn his surgical technique but also his work philosophy. Evandro always highlighted the 4 pillars on which a neurosurgeon must rely on: **passion**, for everything one does, **talent** (and he clearly had a very high dose of it), **tenacity**, to always give everything and the best of himself and **courage**, to face and solve the complex diseases of our specialty.

There are many words to define Evandro, but there are two that come to my mind first. Since Evandro is a synonym of art, I allow myself to draw a parallel and go back in time almost 500 years to arrive at the figure of Verocchio. In addition to being an outstanding painter and sculptor, Verocchio was the teacher of many other remarkable artists of the Renaissance period such as the great Leonardo Da Vinci. I think history repeats itself here: many years later these two figures meet again in the person of Evandro, as **genius** and **master**. I think these two words perfectly sum up what Dr. Evandro was for neurosurgery, and also gifted with a great deal of generosity.

In recognition to his greatness and in eternal gratitude for all that of what his surgical school stands for, we are committed to honor, maintain, and spread his legacy to the next generations of neurosurgeons.

Conflict of Interest
None.

Address for correspondence
Pablo Augusto Rubino, MD, Hospital El Cruce, Buenos Aires, Argentina
(e-mail: parubino@hotmail.com).

DOI https://doi.org/10.1055/s-0041-1730277.
ISSN 0103-5355.

Thieme Revinter Publicações Ltda., Rua do Matoso 170, Rio de Janeiro, RJ, CEP 20270-135, Brazil

Special Article

Farewell Evandro!

Raul Marino Junior[1]

[1] University of São Paulo Medical School, São Paulo/SP, Brazil

Arq Bras Neurocir 2021;40(1):25–26.



Raul Marino Jr. M.D., PhD
Professor and chairman of Neurosurgery
(Emeritus Professor) University of São Paulo Medical School, Brazil
Privat Docent Professor in Medical Ethics and Bioethics, University of São Paulo.

"He whom the gods love dies young, while he has strength and senses and wits"

PLAUTUS (Bacchides (254–184 B.C)

Doctor Evandro de Oliveira, since we have been associates for many years, reminds me of a famous quote from Sir Isaac Newton, in 1675, when he said to Robert Hooke: " If I have seen further it is by standing on the shoulders of giants". Evandro and I had the same blessing and inspiration of working among giants, one of whom was Evandro himself. Working together for many years (►**Figs. 1–3**), I found out that we both met our mission and our destiny together. Evandro and his wife Marina were my best man and best maid when I married Angela. He has also operated upon my mother and my younger son. To me that says a lot!

I started to admire the young Evandro during some of his appearances at the Brazilian Neurosurgery Society meetings, and started to correspond with him during his stay as a research fellow with Al Rhoton in Gainesville, Florida. When he returned, in 1983, we founded our private neurosurgical service together: "The S. Paulo Neurological Institute". When I was nominated Professor and Chairman of Neurosurgery of the University of São Paulo Medical School, I convinced him to start his academic career, and he soon became responsible for the vascular and tumor groups, as its chief, where many of his assistants were trained. It would be pointless to describe the many contributions he started to make in the microsurgery of complex aneurisms and AVM's. There, and in our private service at the Portuguese Hospital he operated upon thousands of cases, with a detail: they were all well documented, as Dr. Charles Drake and Yasargil used to do. In the meantime Evandro started to travel: He was with Yasargil in Zürich, with Vinko Dolenc in Slovenia, Charles Drake in Ontario, and back and forth in Gainesville perfecting his lectures. We also started a microsurgery Lab in the basement in one of the hospital houses, which soon became a large lab in the main hospital building, which started to attract participants all all over the world and

Fig. 1 Profs Raul Marino Jr, Evandro de Oliveira and M. G. Yasargil at the auditorium of Microsurgical laboratory of Hospital of Beneficencia Portuguesa of São Paulo.

Fig. 2 Profs Raul Marino Jr, Evandro de Oliveira, Albert Rhoton and Jules Hardy in one of the several meetings Evandro lectured.

Address for correspondence
Raul Marino Junior, MD, PhD, University of São Paulo Medical School, São Paulo/SP, Brazil (e-mail: marcia.dantas@institutoneurologico.com.br).

DOI https://doi.org/10.1055/s-0041-1730278.
ISSN 0103-5355.

Thieme Revinter Publicações Ltda., Rua do Matoso 170, Rio de Janeiro, RJ, CEP 20270-135, Brazil

Fig. 3 Profs Raul Marino Jr, M G Yasargil, Antonio H. de Moraes (one of the gretset business man in Brazil at the time) and Evandro de Oliveira at the Hospital Benficencia Portuguesa of Sao Paulo.

visiting professors like Yasargil himself, Dolenc, Rhoton, Al Mefty, Jules Hardy, and many others. Evandro's courses became very popular among Brazilian residents and surgeons and still active until recently, when he start to show some signs of a neurological progressive problem, which interrupted his brilliand career a few months ago.

I remember when professor Yasargil, was elected the "Neurosurgeon of the Century", in Boston, during the Congress Meeting in 1999.

Today we have our own Brazilian Yasargil, our Neurosurgeon of the century in São Paulo, where he left thousands. of disciples and worshipers that nicknamed him:" the whisperer brain surgeon" a title that makes him justice.

Conflict of Interest
None.

Special Article

My Friend, Dr. Evandro de Oliveira

Robert F. Spetzler[1]

[1] President and CEO Emeritus, Barrow Neurological Instititute, Phoenix Arizona, United States

Arq Bras Neurocir 2021;40(1):27–28.

Robert F. Spetzler, MD

While Evandro de Oliveira's heritage was Brazilian, his work and spirit belong to the international neurosurgical community. He traveled the world over, giving exquisite presentations peppered with fascinating cases and always including his beautiful anatomical specimens. Evandro was the most prominent of Albert Rhoton's fellows, and he took his anatomical knowledge a step further than his esteemed teacher by applying it directly in the operating room.

I knew and admired Evandro for decades. We crossed paths in so many continents and cities that they all blur together. His passion—whether he was in the right or not—was always evident, and no one was left in doubt as to where he stood on any topic. His exacting surgical technique coupled with his extensive anatomical knowledge gave him a platform to express his beliefs that found resonance with all neurosurgeons worldwide. Even after his disease greatly limited his physical abilities, when he attended *his* symposium at the AANS where colleagues from around the world presented lectures, he not only was present throughout the long sessions but also continued to express his opinions

Fig. 1 At the annual Spetzler/Rhoton course at the BNI with special guest Dr Evandro de Oliveira, front row, third from right.

Address for correspondence
Robert F. Spetzler, MD, President and CEO Emeritus, Barrow Neurological Instititute, Phoenix Arizona, United States
(e-mail: robert.spetzler@barrowbrainandspine.com).

DOI https://doi.org/10.1055/s-0041-1730279.
ISSN 0103-5355.

Thieme Revinter Publicações Ltda., Rua do Matoso 170, Rio de Janeiro, RJ, CEP 20270-135, Brazil

Fig. 2 Dr Evandro de Oliveira (far right) joining the laughter after Dr Albert Rhoton Jr (third from right) had challenged Dr Robert Spetzler (second from right) to a pushup contest.

with absolute certitude and enthusiasm. His physical prowess may have diminished with time, but his intellectual convictions never faltered.

Each time we met, I could count on Evandro to teach me some new caveat, something to try, or something to avoid. At Barrow Neurological Institute, we held an annual Spetzler/Rhoton course with Evandro as a special guest each year. It was there that I had the opportunity to get to know the soul of the man. We had so many professional common interests where we shared triumphs and tragedies, but having the opportunity to spend time together outside of the hospital setting discussing religion, art, and other topics provided a unique perspective that allowed me to appreciate the incredible person Evandro was (►**Figs. 1** and **2**).

Neurosurgeons tend to be intelligent, coordinated, driven, and opinionated. Among many with these traits, there are those individuals who push the envelope of our art, giving patients hitherto unknown options in their struggle with neurosurgical maladies. Evandro worked on the frontier of neurosurgery, pushing hard to develop new corridors into the brain, the most fragile of organs. He taught us that some lesions, like the most difficult AVMs, could be safely extirpated because of his exquisite anatomical knowledge. His contributions to our field will cement him among the giants of neurosurgery who allow our specialty to continually improve and provide new opportunities to those patients who desperately seek our help.

Although I know that all of us are proud of Evandro's international recognition and patients worldwide have benefited from his tremendous contributions to the art of neurosurgery, the Brazilian neurosurgical community, in particular, can take pride in producing this special man whom we will all miss greatly.

Conflict of Interest
None.

Special Article

Memories and what Evandro de Oliveira taught me

Rokuya Tanikawa[1]

[1] Teishinkai Hospital, Sapporo, Japan

Arq Bras Neurocir 2021;40(1):29.

Rokuya Tanikawa, MD

The neurosurgery giant has died. I would like to express my deepest condolence to all the family members.

I first met Evandro in 2012 at the Taipei Veterans General Hospital's microsurgery cadaver dissection and bypass hands-on course hosted by Sanford PC Sue in Taipei. I was invited by Sanford to treat a giant aneurysm at internal carotid-posterior communicating which had a direct branching of anterior choroidal artery from the dome.The live surgery was scheduled after the microsurgery course and I had two lectures about a vascular reconstruction and a microsurgical cisternal approach about transsylvian and anterior interhemispheric approach. Evandro commented several points about the advantage pterional approach to anterior communicating aneurysm based on his enormous experiences of clipping anterior communicating aneurysm with emphasizing the number of experience which is very important to achieve a successful result. That was great opportunity for me to looking back my experience of anterior interhemispheric approach to anterior communicating aneurysm, because I had just 300 to 400 cases of Acom aneurysm with anterior interhemispheric approach and the number I experienced was too small to conclude "Hundred percent of anterior communicating aneurysm can be treated safely with anterior interhemispheric approach". I humbly remember what he meant to me.

He is not only a master of cerebrovascular surgery but also one of big master of neuroanatomy, although I have been learning skull base anatomy under Professor Fukushima since 2000. The way to obtain the knowledge and skills to understand exactly is not easy and it takes long time as Evandro mentioned any time. I am still learning skull base anatomy in my daily surgeries to solve my question inside me and in a cadaver course at least once a year.

The neurosurgeons in the next generation after Evandro must continue to learn neuroanatomy and train hard themselves to achieve the knowledge and the skills to treat the patient safely. The most important what Evandro meant is a humble attitude to improve ourselves.

Conflict of Interest
None.

Address for correspondence
Rokuya Tanikawa, MD, Teishinkai Hospital, Sapporo, Japan
(e-mail: taniroku@gmail.com).

DOI https://doi.org/10.1055/s-0041-1730280.
ISSN 0103-5355.

Thieme Revinter Publicações Ltda., Rua do Matoso 170, Rio de Janeiro, RJ, CEP 20270-135, Brazil

Special Article

Evandro de Oliveira: from Anatomy to Science and the Art of Microneurosurgery

Sebastião Gusmão[1]

[1] Universidade Federal de Minas Gerais, Belo Horizonte, Minas Gerais, Brazil

Arq Bras Neurocir 2021;40(1):30–32.

Sebastião Gusmão

It is classic to state: medicine is science and art. Medicine and art go hand in hand. Hippocrates's medicine(460-378 BC) was born during Pericles century (495-429 BC), at the nadir of Greek art of Fidias (490-430 BC). Both submerged during the middle ages and reburned during the Italian renaissance.

Science can be defined like organized knowledge and be confirmed through observation and experimentation. However, it is difficult to define art because the term could mean multiple things in different places and time. The greek term tékhné, translated to latin as technique and also as art.The later meaning, whatever is well done by the man. For the greeks artwork was to perform a technique with excellence. Hence, in the first Hippocrates' s aphorism, "The life is short, the art last long."(ÓBios brakhys É dé tékhné makhré), the term tékné refers to art meaning technique acquisition, practical knowledge the execution of work in the medical field.

In all branches of knowledge, including medicine and surgery, there archaic civilizations referred to medicine as art, or better as technique based in mythical explanation. The "Greek miracle" exclude the mythical explanation and submitted the technical knowledge to the sieve of rationality, creating Science as we know. Therefore, medicine and surgery are old as art but new as science. In reality, way before the emergence of science in Greece at the 6th century B.C., the Neolithic man already had practiced the art of surgery as documented in several trephined skulls found in several different archeological sites.

The intimate relation between technique and science in the pre-Socratic Greece was ruptured by Plato is(428-348 B. C.) philosophy, which was disputed by the intellectual capacity of the technicians.

This fact determined the discredit of the manual labor, including plastic artists, during the medieval and classic period, being one of the main reasons for the dichotomy between theory and practice, science and technic, medicine (scientific knowledge) and surgery (technical knowledge). This dichotomy increased with the medieval scholars. Only during the Renaissance the artist and handcrafters recuperated their dignity and prestige.

The Vesalius"s (1514-1564) dissections depicted in De Humani Corpori Fabrica (1543), inaugurate the modern medicine. In his work, still considered the most outstanding in medicine, the narrow relation between science and art takes place.

The Vesalius' text is as important as the exquisite illustrations of Calcar (1499-1546), Tiziano's disciple. Therefore we can say that modern medicine was born in an anatomy laboratory and in the workshop of a renaissance painter.

The word surgery came from the Greek kheir, hand, and ergon, "work" .Until the XVI century, surgery was only manual labor, without scientific bases, and wasn't performed by doctors but by barber surgeons. Ambroise Paré (1510-1590) saw the new Vesalius's anatomy as the foundation of surgery. He transformed the barber-surgery art into the medieval art and science of surgery, giving the dignity and respect towards to the surgeon's work.

In the Seventeenth century, the knowledge acquired in the two previous renaissance centuries increased even more, leading to the birth of the modern science.

In this context neurosciences was born in 1664, with the work named **Cerebri Anatome** from Willis (1621-1675), in which medieval concepts regarding cerebral function were repealed. The pillars of modern neurosciences and neurology were established. As a matter of fact, in this work the word neurology was coined. Again, one more time we witnessed the narrow association between art and science, the outstanding text written by Willis was impeccably illustrated by Christopher Wren (1632-1723), the greatest british artist from all times. Sir Wren, himself, was responsible for the London's reconstruction after the devastating 1666 fire. The Saint Paul cathedral being his masterpiece. Wren's superb

Address for correspondence Sebastião Gusmão, Universidade Federal de Minas Gerais, Belo Horizonte, Minas Gerais, Brazil (e-mail: sebastiaogusmao@gmail.com).

DOI https://doi.org/10.1055/s-0041-1730281.
ISSN 0103-5355.

Thieme Revinter Publicações Ltda., Rua do Matoso 170, Rio de Janeiro, RJ, CEP 20270-135, Brazil

drawings revealed great elegance and precision, showing the brain in such detailed and realistic fashion never seen before in any publication.

Subsequently in the Nineteenth century, John Hunter applied experimental scientific method to surgery, creating modern surgery. At the end of the Nineteenth century, advances in general surgery and the better understanding of anatomy and physiology of the nervous system, made possible the creation of neurosurgery as a modern medical specialty.

The modern neurosurgery was born from the hands of an artist-scientist, Harvey

Cushing (1869-1939). The artistic talent from this neurosurgery pioneer was well portraited in his landscape drawings and pictures in his own monumental neurosurgical publications.

On the late half of the last century another scalpel genius, Yasargil, took neurosurgery to another level. Using his extensive and intensive laboratory work he created Microneurosurgery, allowing us to perform miniature art, under microscopic visualization. Indeed, that represented a true revolution in the field, debuting new surgical approaches and better treatment options. Yasargil established several steps. First, the profound and thorough knowledge in central nervous system anatomy. Second, the need of relentless laboratory training and last, but not least, to approach the pathology in the brain in as harmless way as possible through its natural pathways: the sulci and cisterns.

Another essential master to established microneurosurgery was Rhoton. He taught us, using his own exquisite anatomical preparations, to understand better tridimensional brain anatomy and microanatomy and its variations.

Rhoton created a legion of microneuroanatomists that preached their knowledge in all continents. His personal as well as his collaborators endless work constitute the unique preliminary requirement to enter into the science and art of the microneurosurgery world.

His most dear and brilliant pupil was Evandro de Oliveira. After training and conclusion of several projects with his mentor, Evandro returned to Brazil in the earlier eighties. Even before the adventof the internet, he disseminated mocrosurgical knowledge applied to neurosurgery among the Brazilian neurosurgeons. Actually, he initiated a new era of microneurosurgery in his country. To perform microneurosurgery is not just limited to the use of the microscope (which by the way was already present in ours operative rooms. Not too long after that he created the magnificent anatomy laboratory at Beneficência Portuguesa Hospital. For almost four consecutive decades this laboratory has been the main center for microsurgical training for residents and young neurosurgeons. It is for sure a sacred temple for science and art in microneurosurgery. The work of Evandro de Oliveira was without any doubt one of the main factors in the process to raise the Brazilian neurosurgery to the top of the latin-america neurosurgery and to be considered one of the best of the world.

Beyond this essential work in training the last generations of Brazilian neurosurgeons, Evandro de Oliveira developed and improved new microsurgical approaches, shown to our neurosurgery in all four corners of the world and abroad and subsequently opened the doors for many young Brazilian neurosurgeons.

With his skillful hands like a Chinese artist in porcelain from the Ming dynasty, he touched the brain like a priest touches a sacred icon, more so, with his restless brain that kept persuing the brain's misteries, he restored and gave life to thousands of brains. Without passion, life is meaningless. With passion, Evandro took his work to the edges of perfection, turning into pure art. His happiness is to find pleasure in this unique form of art.

It will never be redundant to state how important is the laboratory work in the learning process of microanatomy and surgical technique. Evandro had a fundamental role in improvement in the many generations from Brazil and other countries.

Actually, the modern medicine originated in a laboratory, when Vesalius in1543, performed magnificent dissections to better understand the human body and to illustrate his Fabrica. At the end of the nineteenth century the neurosurgery had its beginning with Horsley. He was summoned to initiate surgical treatment in the neurological patients of the famous Queen Square, due to his notorious skill to open monkey skulls in a laboratory installed in his own house. Yasargil also created microneurosurgery in a laboratory.

The Italian renaissance master painters were in fact the first anatomists. In order to place in canvas the enigmatic face of Monalisa and to carve in pure marble the harmonious lines of David, Leonardo Da Vinci e Michelangelo, they had to dissect cadavers and be aware of the representation object, the human body. In the same fashion, the similar requirements are recommended to the microneurosurgeon. Extreme dedication in studying the anatomy in the laboratory to repair the most complex organic matter ever existent in the universe, the human brain. Only by that way is possible to acquire the mastery in science and art of microneurosurgery.

Five centuries passed by and Vesalius's statement is still true: " the anatomy has to be considered the most solid pilar of the art of medicine, its preliminary essential. The central nervous system anatomy is our preliminary essential in the work field where we practice our job. The brain is the most complex and elaborated matter in our known universe. The brain named itself and creates the universe in which we realized the origin of all forms of arts. Significant art is required from someone that desires to enter in the temple of all arts.

The art has the power to emphasize and refine our senses and to stimulate our awareness in search of occult essence of life's phenomena. The antagonism between art, the daughter of inspiration, and science, originated from methodic observation of facts is only apparent. Art in the Hellenic sense of what is well done and that embroiders all mankind's achievements, including science, because the beauty is everywhere, from a mathematical equation to a Rembrandt (1606-1669) canvas.

Medicine and art complement each other. It is very superficial to imagine a conflict existent between a practical

art such as surgery, that depends of judgement, intuition and skill, and the precision of science that requires elimination of all human elements. Patient care and treatment of diseases are problems to science, but the excellence in both depends on the art that the doctor applies with scientific knowledge.

In Neurosurgery, the complex central nervous system anatomy, its low threshold for manipulation and the rigidity of the cranium osseous compartment make the challenges even worse, thus requiring refined science and art.

The surgeon in action is no longer a handcrafter that cuts, ligates, detaches or sutures. However, he is not a technician either, but a physician that carries deep knowledge in the human being and his emotional problems and precise domain regarding diseases mechanisms, its diagnostics, pathological manifestations and treatment. Such knowledge, associated with the wisdom originated with experience, it is at the fundaments of abilities in surgical judgement, which is the most difficult requirement to be acquired in the art of surgery.

Our art reflects our life, because nothing can come out from the artist if it is not in the man. Be a good neurosurgeon depends on first in being a good doctor. And what defines a good doctor? Kindness, empathy, conscience, ethics, and the ability to make sensible decisions and make proper judgements, as well as the desire in doing the best for the patient. In the nervous systems there are islands of knowledge, where science can be applied, and a vast ocean where we can only offer hope and comfort. The latter is, a major part of the art of neurosurgery, where we feel and intuit, but can not prove. Like knowledge doesn't resume life, science does not limit medicine. The art is necessary.

The accurate surgical technique, like any other ability, requires repetitive training associated with passion. We can build nothing big without passion. The passion leads to pleasure in our work and that perfects the technique until it meets the art. Therefore excellence in microneurosurgery is a matter of technique, because this originates in the brain of the technician. It is a matter of personality, attitude and character. Those qualities are present in the masters Yasargil and Rhoton. After several years of coexistence and working alongside, I could notice them well in Evandro de Oliveira. His precise microsurgical technique, reached the state of the art, and is nothing more than his character almost paranoid in chase of the truth, the essence of things, the perfect technical detail. On the foundation of all that is the respect to the brain's complexity and the love towards the human being that suffers, generating passion for his duty. According to van Gogh (1853-1890), "The essence of art is the love to the human being." The essence of medicine is the love for the human being that suffers. Only love and art can make existence tolerable, and there is the place that the art of medicine acts. A lot of dignity and humility is necessary from someone whose duty involves love, art and life.

As mentioned above, the master Yasargil, Rhoton and Evandro de Oliveira extensively contributed to the establishment of the art and science of microneurosurgery. The same way Hippocrates removed medicine from the gods temple giving to it mankind, those masters revealed upon us the safe pathways to get in all hidden compartments of the sacred temple of the human brain.

Human knowledge will continue flowing implacably, generating new technologies that probably will reinvent our specialty, that will require from us more science to dominate them and more art to apply them with wisdom in favor of our patient's life and fulfillment of our own. At last, there is only one art undebatable important: to live; everything else is secondary. To our master Evandro de Oliveira, that has helped many in the difficult and dangerous art of living, we can only to thank using the words of the genius of the Portuguese language (Camões): "E mais vos pagamos e mais vos devemos" (The more we pay you, the more we owe you)

Conflict of Interest
None.

Tubular Microdiscectomy versus Conventional Surgery for Sciatica. A Comparative Prospective Enzyme Study

Microdiscectomia tubular versus cirurgia convencional para ciática. Estudo comparativo e prospectivo de enzimas

Mandour Cherkaoui[1] Kasouati Jalal[2] Laaguili Jawad[1] Gazzaz Miloudi[1] El Mostarchid Brahim[1]

[1] Department of Neurosurgery, Military Hospital Mohammed V, Rabat, Morocco
[2] Epidemiology Laboratory and Clinical Research, Military Hospital Mohammed V, Rabat, Morocco

Address for correspondence Mandour Cherkaoui, Pr, Department of Neurosurgery, Military Hospital Mohammed V, Rabat, Morocco (e-mail: mandour1978@hotmail.com).

Arq Bras Neurocir 2021;40(1):33–36.

Abstract

Objective Muscle injury is inevitable during surgical exposure of the spine, and it is quantified by the release of creatine phosphokinase. The aim of the present study is to make a comparison between tubular microdiscectomy and conventional microdiscectomy by using the pre- and postoperative serum concentrations of creatine phosphokinase as an indicator of muscle injury.

Materials and Methods A total of 28 patients who underwent surgery for lumbar disc herniation were allocated into 2 groups: 12 patients (group A) operated by transflaval microdiscectomy, and 16 patients (group B) operated by tubular microdiscectomy. The serum concentration of total creatine phosphokinase was measured before surgery (creatine phosphokinase 1) and 1 day after surgery (creatine phosphokinase 2).

Results There were 12 women and 16 men; the mean age of the patients and the mean duration of the surgery were respectively 49.5 years and 56 minutes for group A, and 47.3 years and 60 minutes for group B. The *p*-values of creatine phosphokinase 1, creatine phosphokinase 2 and the creatine–phosphokinase ratio were respectively 0,34; 0,31; and 0,57 ($p < 0.05$).

Conclusion The present study demonstrated that there was no significant difference between tubular microdiscectomy and conventional microdiscectomy according to the analysis of the levels of creatine phosphokinase.

Palavras-chave
- enzima
- hérnia
- microdiscectomia
- ciática
- tubular

received March 30, 2020
accepted August 5, 2020
published online October 16, 2020

DOI https://doi.org/10.1055/s-0040-1718429.
ISSN 0103-5355.

Thieme Revinter Publicações Ltda., Rua do Matoso 170, Rio de Janeiro, RJ, CEP 20270-135, Brazil

Resumo

Objetivo A lesão muscular é inevitável durante a exposição cirúrgica da coluna vertebral, e é quantificada pela liberação de creatina fosfoquinase. O objetivo deste estudo é fazer uma comparação entre microdiscectomia tubular e microdiscectomia convencional usando creatina fosfoquinase sérica pré e pós-operatória como indicador de lesão muscular.

Materiais e Métodos Um total de 28 pacientes submetidos a cirurgia de hérnia de disco lombar foram alocados em 2 grupos: 12 pacientes (grupo A) operados por microdiscectomia transflaval, e 16 pacientes (grupo B) operados por microdiscectomia tubular. A concentração sérica de creatina fosfoquinase total foi medida antes da cirurgia (creatina fosfoquinase 1) e 1 dia após a cirurgia (creatina fosfoquinase 2).

Resultados Havia 12 mulheres e 16 homens; a média de idade dos pacientes e o tempo médio da cirurgia foram respectivamente de 49,5 anos e 56 minutos para o grupo A, e de 47,3 anos e 60 minutos para o grupo B. Os valores de *p* da creatina fosfoquinase 1, da creatina fosfoquinase 2, e a razão creatina–fosfoquinase foram, respectivamente, 0,34; 0,31; e 0,57 ($p < 0,05$).

Conclusão Este estudo demonstrou que não houve diferença significativa entre microdiscectomia tubular e microdiscectomia convencional de acordo com a análise dos níveis de creatina fosfoquinase.

Keywords
- enzyme
- hernia
- microdiscectomy
- sciatica
- tubular

Introduction

Unilateral transflaval microdiscectomy is the gold standard surgical procedure for the treatment of patients with symptomatic lumbar disc herniation.[1] However, minimally-invasive procedures (such as tubular microdiscectomy) have gained increasing attention over the last decade, based on the concept of lower muscle damage.[2]

The level of serum creatine phosphokinase in the postoperative period has been considered a suitable parameter to estimate muscle injury in various spinal procedures;[3] for this reason, we used this marker to compare these two surgical techniques through a prospective study.

Material and Methods

Patient Selection

Between June 2019 and February 2020, 28 patients were surgically treated for sciatica due to lumbar disc herniation diagnosed by lumbar magnetic resonance imaging.

In total, 12 patients (group A) were operated by transflaval microdiscectomy, and 16 patients (group B) were operated by tubular microdiscectomy.

The inclusion criteria for the present study were no pathological history (no medical or surgical history or medication taken that may affect the levels of creatine phosphokinase, and a single-level disc herniation requiring a one-sided approach. All cases were opereted by the same neurosurgeon.

Surgical Procedure

Surgery was performed under general anesthesia with the patient in the genupectoral position.

Group A: conventional microdiscectomy was performed after subperiosteal dissection of the ipsilateral paravertebral muscles. The herniated disc was removed by the unilateral transflaval approach with the aid of microscope magnification.

Group B: tubular microdiscectomy; the skin was retracted laterally, and the guide wire and sequential dilators were placed at the inferior aspect of the lamina under fluoroscopic control. The herniated portion of the disc was removed through the tubular retractor with microscopic magnification.

In both procedures, subtotal discectomy was intended, and bony removal was minimal, if necessary.

In the postoperative period, all patients were mobilized and discharged as soon as possible to resume their regular activities whenever possible.

Measurement of creatine phosphokinase: the serum concentration of total creatine phosphokinase was measured before surgery (creatine phosphokinase 1) and 1 day after surgery (creatine phosphokinase 2). The normal serum creatine phosphokinase concentration in our hospital is 24 IU/L to 195 IU/L.

Results

Demographics and surgical characteristics (►**Table 1**): a total 28 patients with lumbar disc-related sciatica were surgycally treated by tubular microdiscectomy and unilateral transflaval microdiscectomy. The sample was composed of 12 women and 16 men, and there were 19 cases of hernia at the L4-L5 level, and 09 cases at the L5-S1 level.

The mean of age of the patients and the mean duration of the surgery were respectively 49.5 years and 56 minutes for group A, and 47.3 years and 60 minutes for group B.

Table 1 Demographic data: age; gender; level and duration of the surgery

	Conventional microdiscectomy N = 12	Tubular microdiscectomy N = 16
Age (years)	60–28 (49.5)	63–27 (47.3)
Sex (female/male:F/M)	03 F/09 M	09 F/07 M
Mean of duration of the surgery (minutes)	56	60
Disc hernia level and number of cases	L4-L5/L5-S1 06/06	L4-L5/L5-S1 13 / 03

Abbreviations: L4, fourth lumbar vertebra; L5, fifth lumbar vertebra; S1, first sacred vertebra.

The postoperative follow-up was simple for all patients, without complications, and with a similar clinical improvement regarding the two techniques.

Serum creatine phosphokinase (►**Table 2**): the mean concentration of creatine phosphokinase 1 was of 85.81 IU/L for tubular microdiscectomy, and of 105.66 IU/L for conventional microdiscectomy; the mean concentration of creatine phosphokinase 2 for tubular microdiscectomy and conventional microdiscectomy was of 289.06 IU/L and of 36025 IU/L respectively. The mean creatine–phosphokinase ratio (creatine phosphokinase 2/creatine phosphokinase 1) was of 4.01 for tubular microdiscectomy, and of 3.58 for conventional microdiscectomy.

The statistical analysis showed no significant difference between both procedures regardinge creatine phosphokinase 1, creatine phosphokinase 2, and creatine phosphokinase ratio, because the statistical significance was set at the probability level of 0.05.

Discussion

The most common cause of sciatica is a herniated lumbar disc; even though lumbar disc surgery is frequently performed, the preferred technique was until recently an important point of debate. Based on the hypothesis that "small is better," efforts have been made to decrease tissue damage through smaller corridor approaches.[2]

The concept of minimally-invasive spine surgery comprises reduced muscle injury while achieving a good clinical outcome comparable with conventional open surgery.

The patients are expected to have less intense low-back pain, shorter hospitalization time, faster mobilization, and to recover.[4]

Several proteins have been widely used in medicine as markers of tissue damage, such as creatine phosphokinase, which is the most widely used blood parameter for the detection of striated muscle injury,[5,6] and it reaches a maximal concentration one day after surgery.[7,8]

A clear dose–response relationship between creatine phosphokinase and the extent of the surgical invasiveness has been shown,[9] as well as relationships with the pressure exerted by the retractors on the paraspinal musculature and the duration of this pressure (operating time).[10]

In the present prospective study, we performed a quantitative analysis of muscle injury measured by serum creatine phosphokinase. No significant differences were found regarding creatine phosphokinase 1, creatine phosphokinase 2, and the creatine–phosphokinase ratio between tubular microdiscectomy and conventional microdiscectomy.

This result is in line with other results published in the literature,[11,12] and we explain this non-significant difference by the fact that conventional microdiscectomy is performed through a small incision with lower muscle damage, especially in the case of single-level surgeries. Therefore, in our opinion, conventional unilateral transflaval microdiscectomy can be considered a minimally-invasive procedure as well.

The main limitation of the present study is the small sample, the lack of clinical evaluation in relation to serum creatine phosphokinase, and the lack of a postoperative evaluation of the functional outcome and pain intensity on the visual analog scale; therefore, the clinical significance of our results is not known.

Conclusion

The release of creatine phosphokinase is an indicator of muscle injury during the surgical exposure of the disc hernia. The present study showed that tubular microdiscectomy is equally invasive as conventional microdiscectomy in terms of creatine phosphokinase for single-level surgeries, with similar surgical outcomes.

Table 2 Serum concentrations of creatine phosphokinase

CPK	Conventional microdiscectomy N = 12	Tubular microdiscectomy N = 16	*p*-value (< 0.05)
Mean CPK 1	(200–57) 105.66 IU/L	(280–18) 85.81 IU/L	0.34 CPK1
Mean CPK 2	(843–123) 360.25 IU/L	(640–23) 289.06 IU/L	0.31 CPK2
Mean CPK ratio	3.58	4.01	0.57 CPK ratio

Abbreviations: CPK, creatine phosphokinase; IU/L, International unit per liter.

Conflict of Interests

The authors have no conflict of interests to declare.

References

1 Arts M, Brand R, van der Kallen B, Lycklama à Nijeholt G, Peul W. Does minimally invasive lumbar disc surgery result in less muscle injury than conventional surgery? A randomized controlled trial. Eur Spine J 2011;20(01):51–57

2 Akçakaya MO, Yörükoğlu AG, Aydoseli A, et al. Serum creatine phosphokinase levels as an indicator of muscle injury following lumbar disc surgery: Comparison of fully endoscopic discectomy and microdiscectomy. Clin Neurol Neurosurg 2016;145:74–78

3 Iglesias DL, Granell JB, Ribero TV. Validity of Creatine Kinase as an Indicator of Muscle Injury in Spine Surgery and its Relation with Postoperative Pain. Acta Orthop Belg 2014;80(04): 545–550

4 Arts MP, Brand R, van den Akker ME, Koes BW, Bartels RH, Peul WCLeiden-The Hague Spine Intervention Prognostic Study Group (SIPS). Tubular diskectomy vs conventional microdiskectomy for sciatica: a randomized controlled trial. JAMA 2009;302(02): 149–158

5 Achalandabaso A, Plaza-Manzano G, Lomas-Vega R. Tissue Damage Markers after a Spinal Manipulation in Healthy Subjects: A Preliminary Report of a Randomized Controlled Trial. Dis Mark 2014

6 Shin DA, Kim KN, Shin HC, Yoon DH. The efficacy of microendoscopic discectomy in reducing iatrogenic muscle injury. J Neurosurg Spine 2008;8(01):39–43

7 Kawaguchi Y, Matsui H, Tsuji H. Back muscle injury after posterior lumbar spine surgery. A histologic and enzymatic analysis. Spine 1996;21(08):941–944

8 Kawaguchi Y, Matsui H, Tsuji H. Changes in serum creatine phosphokinase MM isoenzyme after lumbar spine surgery. Spine 1997;22(09):1018–1023

9 Arts MP, Nieborg A, Brand R, Peul WC. Serum creatine phosphokinase as an indicator of muscle injury after various spinal and nonspinal surgical procedures. J Neurosurg Spine 2007;7(03): 282–286

10 Kotil K, Tunckale T, Tatar Z, Koldas M, Kural A, Bilge T. Serum creatine phosphokinase activity and histological changes in the multifidus muscle: a prospective randomized controlled comparative study of discectomy with or without retraction. J Neurosurg Spine 2007;6(02):121–125

11 Arts MP, Brand R, van den Akker ME, et al. Tubular diskectomy vs conventional microdiskectomy for the treatment of lumbar disk herniation: 2-year results of a double-blind randomized controlled trial. Neurosurgery 2011;69(01):135–144, discussion 144

12 Hernández-Vaquero D, Fernández-Fairen M, Torres-Perez A, Santamaría A. [Minimally invasive surgery versus conventional surgery. A review of the scientific evidence]. Rev Esp Cir Ortop Traumatol 2012;56(06):444–458

Effect of the Extent of Resection on Survival Outcome in Glioblastoma: Propensity Score Approach

Thara Tunthanathip[1] Suphavadee Madteng[1]

[1] Division of Neurosurgery, Department of Surgery, Faculty of Medicine, Prince of Songkla University, Hat Yai, Songkhla, Thailand

Arq Bras Neurocir 2021;40(1):37–43.

Address for correspondence Thara Tunthanathip, M.D., Ph.D., Division of Neurosurgery, Department of Surgery, Faculty of Medicine, Prince of Songkla University, Hatyai, Songkhla, 90110, Thailand (e-mail: tsus4@hotmail.com).

Abstract

Objective To evaluate the effectiveness of the extent of resection (EOR) on survival outcome using propensity score-based approaches.

Materials and Methods A retrospective cohort study was performed in patients with newly diagnosed glioblastoma. Propensity score matching (PSM) and propensity score regression adjustment were used in the matched and unmatched dataset, respectively. Therefore, the Kaplan-Meier survival curve and Cox's regression analyses were performed to determine the effect of the EOR on survival outcomes.

Results One hundred and sixty-eight patients were included for analyzes. The total tumor resection in the unmatched dataset was 22.6% of all cases. Using PSM, incomplete tumor resection had an unfavorable survival outcome when compared with total tumor resection (hazard ratio (HR) 2.92, 95% confidence interval [CI] 1.72–4.94). Additionally, biopsy and partial tumor resection were significantly associated with poor prognosis when compared with total tumor resection using propensity score regression adjustment (HR of biopsy 1.89, 95%CI 1.13–3.16 and HR of partial resection 1.89, 95%CI 1.28–2.80).

Conclusions Patients with total tumor resection tend to have a more favorable prognosis than patients with partial tumor resection. The propensity score-based analysis is an alternative approach to evaluate the effect of an intervention that has limitations to perform a randomized controlled trial.

Keywords
- glioblastoma
- extension of resection
- survival analysis
- propensity score

Introduction

Glioblastoma (GBM) is a malignant primary brain tumor that has a poor prognosis. Surgery is the first treatment option for histology-confirmed diagnosis and tumor burden reduction.[1,2] From large retrospective cohort studies, extents of resection (EORs) ranging from 70 to 98% are the independent factor for significantly increased survival time.[1,3–5] Moreover, Brown et al investigated in a systematic review and meta-analysis on the EOR on survival increment in patients with GBM and reported that total resection improves overall and progression-free survival.[6] However, the lack of evidence from randomized clinical trials (RCTs) on the effect of the EOR related to survival advantages. This variable—EOR—has proven to be a limitation to the conduction of RCTs regarding ethical issues and other confounders. Owing to the infiltrative character of this type of tumor, not all GBMs are amenable to total tumor resection.[7,8] From the literature review, multiple GBMs and tumor volume $\geq$ 30 ml have been reported as limitations for complete tumor removal. In

received
April 20, 2020
accepted
August 5, 2020
published online
October 16, 2020

DOI https://doi.org/10.1055/s-0040-1718424.
ISSN 0103-5355.

Thieme Revinter Publicações Ltda., Rua do Matoso 170, Rio de Janeiro, RJ, CEP 20270-135, Brazil

addition, tumors involving eloquent areas have been reported to be a limitation for total resection because neurological impairments developed after tumor resection.[9]

Because confounding factors are critical problems that need to be addressed before analysis in observational studies attempting to estimate the effect of treatments, propensity score (PS) is one of the methods used for dealing with significantly confounding factors.[10,11] From literature reviews, various techniques of the PS approach, such as matching, stratification, regression adjustment, and inverse probability of treatment weight, were effectively used in numerous studies to compare treated and controlled groups when there were limitations to perform RCT. Agrawal et al used PS-based analysis to evaluate the intracranial pressure monitoring on outcomes in severe traumatic brain injury,[12] while Cepeda et al evaluated the effect of decompressive craniectomy in the postoperative expansion of traumatic intracerebral hemorrhage using PS methods.[13]

Extent of resection is one of the variables that represents a limitation in conducting RCT. Alternatively, PS-based analysis is one of the methods that was used to evaluate the effect of EOR on survival outcomes. Therefore, the aims of the present study were to evaluate the effectiveness of EOR on survival outcomes using PS methods.

Materials and Methods

A retrospective cohort study was performed in the patients who had histologically-confirmed GBM and were newly treated between January 2000 and December 2018 in our institute. Additionally, a part of the study population was obtained from Tunthanathip et al,[9,14] whose study mentioned factors associated with the EOR and genetic factors that could influence prognosis. The exclusion criteria were as follows: 1) unavailable medical record, 2) unavailable neuroimaging for tumor volume calculation, for both the preoperative and postoperative periods, and 3) unavailable update survival status.

In the present study, the EOR was defined according to Vecht et al and Bloch et al.[15,16] Gross total resection was defined as less than 5% of residual tumor, as observed on postoperative neuroimaging. Partial resection was defined as resection of less than 95% of the tumor, as observed on postoperative neuroimaging. Biopsy was defined as an operation for tissue diagnosis only, without attempt of removing the tumor. Additionally, the percentage of resection was assessed by postoperative T1-weighted imaging with contrast.

The follow-up data were collected until June 2019 for survival outcome as update status (death or survival) or cause of death. The follow-up data were mainly collected when patients visited the outpatient clinics. Patients (or caregivers) who did not visit the hospital for appointments were interviewed by phone. Therefore, we also checked death records from the local municipality.

The present study was performed with the permission of the Ethical Committee of the Faculty of Medicine at Songklanagarind Hospital, Prince of Songkla University.

Statistical Analysis

The baseline characteristics included demographic variables, imaging , and therapeutic factors; these were obtained from studies of Tunthanathip et al that reported two variables, multiple GBMs, and tumor volume $\geq$ 30 ml, associated with the EOR.[9,14] We excluded those patients with one or more missing data before estimating the propensity score (PS).

To control selection bias, we used PS methods. We used a logit model with a binary outcome (total resection and non-total resection) to estimate the PS. Therefore, the PSs were calculated and used as a covariate to control for confounding by indication or contraindication in the final model. In detail, two PS-based methods were performed: propensity score matching (PSM) and PS regression adjustment.

Both matched and unmatched datasets as well as baseline clinical characteristics were analyzed using descriptive analysis, presented as proportions and mean $\pm$ standard deviation (SD).

In the PSM, we created a group of treated and controlled patients who were matched by the nearest neighbor matching algorithm with a ratio of 1:1. The effect of EOR on the survival of patients with GBM was analyzed by time-to-event. Survival curves were compared using the log-rank test. Cox regression analyses were performed, and the hazard ratio (HR) with 95% confidence intervals (95% CIs) was determined. In the study of Ahmadipour et al, the HR of biopsy compared with total resection was 2.33 (95%CI 1.77–3.06) for death.[17] Therefore, we calculated a sample size of 26 patients per group at 80% power and with an α level of 0.05, using the Freedman method.[18]

Propensity score regression adjustment was used to run the outcome model of the association between EOR and survival controlled by PS and posttreatment variables from the unmatched dataset. All analyses were conducted using the R version 4.0.2 software (R Foundation for Statistical Computing, Vienna, Austria) with the package MatchIt.[19]

Results

Clinical Characteristics

The 173 patients with GBM were obtained from the study by Tunthanathip et al.[9,14], but 5 patients were excluded because of missing variables. Hence, 168 patients were included for analyses, and their baseline characteristics are shown in ►**Table 1**, both unmatched and matched cohorts.

Unmatched Cohort

The unmatched cohort included 168 patients with GBM. The mean age was 51.4 years (SD 15.3), and half of the subjects were male. One-third of the GBMs commonly involved the temporal lobe, frontal lobe, and parietal lobe. Additionally, corpus callosum was found in 11.3% of the patients. The patients were divided by EOR as binary groups. Total tumor resection was observed in 38 patients (22.6%) of the unmatched cohort, whereas the remaining (77.4%) had either biopsy or partial tumor resection.

There were significant differences between total resection and non-total resection groups in several tumors and tumor

Table 1 Baseline characteristic of patients divided by the extent of resection according to full cohort and propensity score-matched cohort

Factor	Full cohort ($N = 168$)			Propensity score-matched cohort ($N = 76$)		
	Total resection n (%)	Non-total resection n (%)	*P*-value	Total resection n (%)	Non-total resection n (%)	*P*-value
Age, year			0.11			0.15
< 50	12 (31.6)	60 (46.2)		12 (31.6)	18 (47.4)	
≥ 50	26 (68.4)	70 (53.8)		26 (68.4)	20 (52.6)	
Gender			0.70			0.81
Male	20 (52.6)	73 (56.2)		20 (52.6)	19 (50.0)	
Female	18 (47.4)	57 (43.8)		18 (47.4)	19 (50.0)	
Preoperative KPS			0.11			0.10
< 80	24 (63.2)	63 (48.5)		24 (63.2)	17 (44.7)	
≥ 80	14 (36.8)	67 (51.5)		14 (36.8)	21 (55.3)	
Frontal tumor			0.33			0.81
No	25 (65.8)	96 (73.8)		25 (65.8)	24 (63.2)	
Yes	13 (34.2)	34 (26.2)		13 (34.2)	14 (36.8)	
Temporal tumor			0.54			0.80
No	26 (68.4)	82 (63.1)		26 (68.4)	27 (71.1)	
Yes	12 (31.6)	48 (36.9)		12 (31.6)	11 (28.9)	
Thalamus/Basal ganglion			0.58*			0.24*
No	38 (100)	125 (96.2)		38 (100)	35 (92.1)	
Yes	0	5 (3.8)		0	3 (7.9)	
Corpus callosum			0.07*			0.35*
No	37 (97.4)	112 (86.2)		37 (97.4)	34 (89.5)	
Yes	1 (2.6)	18 (13.8)		1 (2.6)	4 (10.5)	
Eloquent area†			0.60			0.64
No	17 (44.7)	52 (40.0)		17 (44.7)	19 (50.0)	
Yes	21 (55.3)	78 (60.0)		21 (55.3)	19 (50.0)	
Initial leptomeningeal dissemination			0.96*			1.00*
No	34 (89.5)	116 (89.2)		34 (89.5)	34 (89.5)	
Yes	4 (10.5)	14 (10.8)		4 (10.5)	4 (10.5)	
Number of tumors			0.02*			1.00*
Single	36 (94.7)	102 (78.5)		36 (94.7)	36 (94.7)	
Multiple	2 (5.3)	28 (21.5)		2 (5.3)	2 (5.3)	
Tumor volume-ml			0.003			1.00
< 30	19 (50.0)	32 (24.6)		19 (50.0)	19 (50.0)	
≥ 30	19 (50.0)	98 (75.4)		19 (50.0)	19 (50.0)	
Postoperative KPS			0.66			0.48
< 80	24 (63.2)	77 (59.2)		24 (63.2)	21 (55.3)	
≥ 80	14 (36.8)	53 (40.8)		14 (36.8)	17 (44.7)	
Adjuvant therapy			0.18			0.09
RT alone	21 (55.3)	87 (66.9)		21 (55.3)	28 (73.7)	
RT with TMZ	17 (44.7)	43 (33.1)		17 (44.7)	10 (26.3)	

(*Continued*)

Table 1 (*Continued*)

Factor	Full cohort ($N = 168$)			Propensity score-matched cohort ($N = 76$)		
	Total resection n (%)	Non-total resection n (%)	*P*-value	Total resection n (%)	Non-total resection n (%)	*P*-value
IDH1 mutation			0.83*			1.00*
Wild-type GBM	36 (94.7)	122 (93.8)		36 (94.1)	35 (92.1)	
Mutant GBM	2 (5.3)	8 (6.2)		2 (5.3)	3 (7.9))	
MGMT promoter methylation			0.14*			0.24*
Methylated GBM	0	7 (5.4)		0	3 (7.9)	
Unmethylated GBM	38 (100)	123 (94.6)		38 (100)	35 (92.1)	

Abbreviations: GBM, glioblastoma; IDH1, isocitrate dehydrogenase1; KPS, Karnofsky performance status; MGMT, O6-methylguanine-DNA methyltransferase; RT, radiotherapy; TMZ, temozolomide.
*p-value of Fisher exact test.
†Eloquent area defined tumor involved motor cortex, sensory cortex, visual center, speech center, basal ganglion, hypothalamus, thalamus, brainstem, dentate nucleus.

volume. In detail, multiple GBMs were frequently observed in the non-total resection group ($p = 0.02$), while tumor volume < 30 ml was commonly found in the total resection group ($p = 0.003$).

Matched Cohort

Patients were equally divided into total resection and non-total resection groups, according to PS. Therefore, 38 patients were assigned to each group. After matching, differences between the two groups regarding several tumors and tumor volume were noticeably absent.

Effect of EOR on Survival Outcome

PSM

The Kaplan-Meier curves based on the EOR after PSM presented in ►**Fig. 1A-B** show overall median survival time of 11.0 months (95%CI 9.29–12.70). According to EOR subgroups, the median survival time of the total resection subgroup was 15 months (95%CI 10.1–19.8), whereas the incomplete resection subgroup had median survival time of 6 months (95%CI 2.6–9.3), as shown in ►**Table 2**. There was a significant difference in prognosis between complete and incomplete

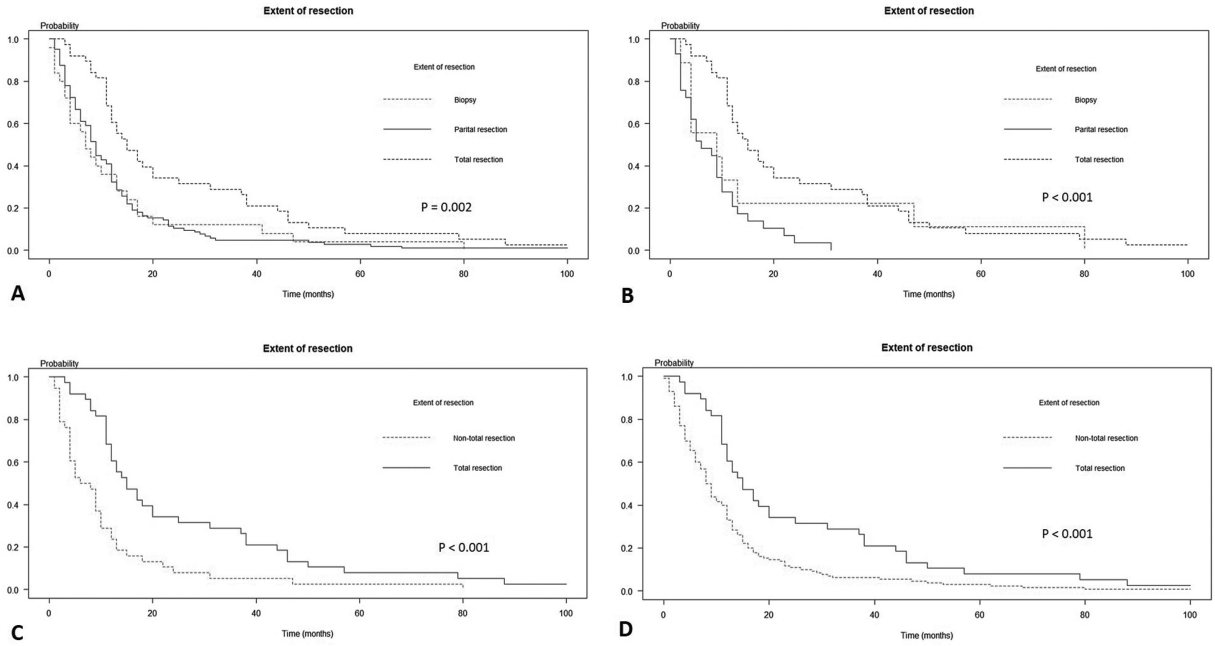

Fig. 1 The Kaplan-Meier curves of survival according to the extent of resection. (A) Bi-classifier of the extent of resection with matched data. (B) The extent of resection with matched data. (C) Bi-classifier of the extent of resection with unmatched data. (D) The extent of resection with unmatched data.

Table 2 Median survival time and survival probability of the extent of resection subgroups

Dataset	The binary outcome of the extent of resection		Extent of resection		
	Total resection (95%CI)	Non-total resection (95%CI)	Total resection (95%CI)	Partial resection (95%CI)	Biopsy (95%CI)
Unmatched dataset					
Median survival time-month	15.0 (10.1–19.8)	8.0 (6.6–9.3)	15.0 (10.1–19.8)	9.0 (7.6–10.3)	7.0 (3.7–10.2)
1-year probability of survival	60.5 (46.8–78.2)	33.0 (25.9–42.2)	60.5 (46.8–78.2)	32.3 (24.5–42.6)	36.0 (21.3–60.7)
2-year probability of survival	34.2 (22.0–53.2)	10.7 (6.5–17.6)	34.2% (22.0–53.2)	10.4 (5.9–18.3)	12.0 (4.1–34.7)
3-year probability of survival	28.9 (17.5–47.6)	6.15 (3.1–12.0)	28.9% (17.5–47.6)	4.7 (2.0–11.2)	12.0 (4.1–34.7)
Matched dataset					
Median survival time-month	15.0 (10.1–19.8)	6.0 (2.6–9.3)	15.0 (10.1–19.8)	6.0 (1.7–10.2)	9.0 (0–23.6)
1-year probability of survival	60.5% (46.8–78.2)	23.6% (13.3–41.9)	60.5% (46.8–78.2)	20.6% (10.1–42.2)	33.3% (13.2–84.0)
2-year probability of survival	34.2% (22.0–53.2)	7.8% (2.6–23.4)	34.2% (22.0–53.2)	3.4% (0.5–2.3)	22.2% (6.5–7.5)
3-year probability of survival	28.9% (17.5–47.6)	5.2% (1.3–20.3)	28.9% (17.5–47.6)	–	22.2% (6.5–7.5)

Abbreviation: 95%CI, 95% confidence interval.

Table 3 Cox regression of the extent of resection on survival outcome according to propensity score methods

Survival outcome	Hazard ratio (95%CI)	*p*-value
Death		
Propensity score matching		
Total resection	Ref	
Partial resection	1.42 (0.68–2.98)	0.34
Biopsy	2.92 (1.72–4.94)	< 0.001
Regression adjustment with the propensity score*		
Total resection	Ref	
Partial resection	1.89 (1.28–2.80)	0.001
Biopsy	1.89 (1.13–3.16)	0.01
Progressive disease		
Propensity score matching		
Total resection	Ref	
Partial resection	0.65 (0.22–1.89)	0.43
Biopsy	0.71 (0.36–1.37)	0.31
Regression adjustment with the propensity score†		
Total resection	Ref	
Partial resection	1.01 (0.62–1.65)	0.07
Biopsy	0.80 (0.41–1.57)	0.52

*Covariates of the model comprised extent of resection (hazard ratio (HR) as shown in table), postoperative Karnofsky performance status (HR 1.044; 95%CI 0.76–1.43), and propensity scores (HR 0.85; 95%CI 0.25–2.88).
†Covariates of the model comprised extent of resection (hazard ratio (HR) as shown in table), postoperative Karnofsky performance status (HR 1.02; 95%CI 0.68–1.52), and propensity scores (HR 2.06; 95%CI 0.44–9.56).

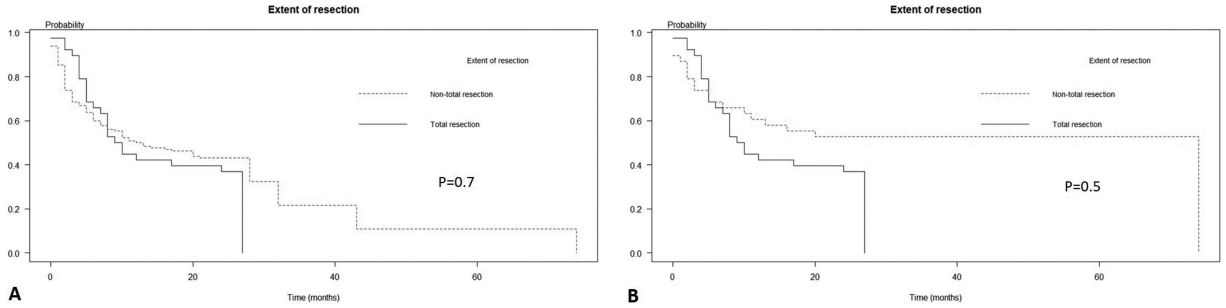

Fig. 2 The Kaplan-Meier curves of progression-free survival according to the extent of resection. (A) Matched data. (B) Unmatched data.

resection subgroups with a log-rank test < 0.001. Using Cox proportional hazard regression analysis, a biopsy had shorter survival time than total tumor resection (HR 2.92, 95%CI 1.72–4.94), and EOR is not associated with progression-free survival, as shown in ►**Table 3** and ►**Fig. 2A-B**.

PS Regression Adjustment

The overall median survival time was 11.0 months (95%CI 9.36–12.63) in the unmatched dataset. The 3-year survival probability of the total resection subgroup was 28.9%, while incomplete resection subgroup had a 3-year survival probability in 5.2%, as shown in ►**Table 2**. By PS regression adjustment, biopsy and partial tumor resection significantly associated with poor prognosis when compared with total tumor resection (HR of biopsy 1.89, 95%CI 1.13–3.16 and HR of partial resection 1.89, 95%CI 1.28–2.80). Additionally, the EOR was not associated with progression-free survival, as summarized in ►**Table 3**.

Discussion

Nowadays, lack of level I evidence exists for comparing the EOR and survival outcome in GBM.[5] Although the effects of the EOR on survival outcomes have been reported in systematic review and meta-analysis, the achievement of an RCT examining EOR in patients with GBM remains unlikely. The PS is the alternative approach to control confounder before analyses of intervention.[20] The patients were equally divided into intervention and control groups that were nearly RCT's assignment in PSM, whereas PSs was a covariate in the model in PS regression adjustment.

After adjustment with PS, total tumor resection significantly increased the survival advantages when compared with non-total resection in both PS methods. Lacroix et al. studied about the degree of resection in 416 patients with GBM and reported that 98% of tumor resection significantly increased survival time,[1] while Stummer et al reported that total tumor resection was associated with longer survival for GBM patients, according to the re-stratifying study of the aminolevulinic acid (ALA) glioma study group.[21,22]

GBM is the infiltrative tumor that has an ill-defined border during tumor resection. Therefore, total resection is not easily performed in all cases. Fluorescence-guided resections with 5-aminolevulinic acid (5-ALA) significantly enhanced rates of total resection compared with conventional microsurgical resection. However, the incremental cost with 5-ALA compared with traditional operation was € 9,021 per QALY gained in economic evaluation. Therefore, fluorescence-guided resection is not the standard treatment, notably a limited-resource setting.[24]

Although the EOR was the independent prognostic factor in the present study, treatment biases to determine the degree of tumor removal have been reported, such as young age, tumor involving eloquent area, preoperative tumor volume, and several tumors. Tunthanathip et al reported that it was hard to achieve total removal in cases of multiple GBMs. Multicentric GBM is one of the subgroups of multiple GBMs in which the centers of the tumors are clearly disconnected from each other, such as in different lobes or bilateral tumors, with no apparent route of dissemination.[25–27] Multi-stage operations need to be performed for total tumor resection in this subgroup.

To our knowledge, the present study is the first paper that demonstrated the effect of the EOR on survival outcomes by PS approaches. The limitations of the present study should be acknowledged. First, for the purpose of PSM, the patients were assigned into total resection and non-total resection groups, based on PS. Nine-two patients were removed from the dataset after matching that deleted patients cause decrease power of the study.[28,29] However, the results after PSM still demonstrate the effect of total tumor resection, which was in. Alternatively, we tried to perform the PS regression adjustment method to preserve the total number of the study population for analyzing the effect of EOR.[30] The concordance of results was observed from both PS approaches. For other limitations, fluorescence-guided resections with 5-ALA was not performed in the present study because it is unavailable in our institute.

Conclusion

Patients with total tumor resection had a statistical tendency of a more favorable prognosis than patients with non-total tumor resection. The PS-based analysis is a useful approach to evaluate the effect of the EOR on survival outcome that has limitations to conduct RCT.

Authors' Contributions

Conception and design: T. T.

Administrative support: T. T., S. M.
Provision of study materials or patients: T. T., S. M.
Collection and assembly of data: T. T., S. M.
Data analysis and interpretation: T. T.
Manuscript writing: All authors
Final approval of manuscript: All authors

Transparency Declaration

Part of the study population was obtained from the studies by Tunthanathip et al.[9,14] However, the present study focused on the effect of the EOR on prognosis.

Conflict of Interests

The authors have no conflict of interests to declare.

References

1 Lacroix M, Abi-Said D, Fourney DR, et al. A multivariate analysis of 416 patients with glioblastoma multiforme: prognosis, extent of resection, and survival. J Neurosurg 2001;95(02):190–198
2 Tunthanathip T, Ratanalert S, Sae-Heng S, Oearsakul T. Butterfly Tumor of the Corpus Callosum: Clinical Characteristics, Diagnosis, and Survival Analysis. J Neurosci Rural Pract 2017;8(Suppl 1): S57–S65
3 Trifiletti DM, Alonso C, Grover S, Fadul CE, Sheehan JP, Showalter TN. Prognostic Implications of Extent of Resection in Glioblastoma: Analysis from a Large Database. World Neurosurg 2017;103:330–340
4 Chaichana KL, Jusue-Torres I, Navarro-Ramirez R, et al. Establishing percent resection and residual volume thresholds affecting survival and recurrence for patients with newly diagnosed intracranial glioblastoma. Neuro-oncol 2014;16(01):113–122
5 Sanai N, Mirzadeh Z, Polley M-Y, et al. The value of glioblastoma extent of resection: a volumetric analysis of 500 patients. J Neurosurg 2010;113:A433
6 Brown TJ, Brennan MC, Li M, et al. Association of the Extent of Resection With Survival in Glioblastoma: A Systematic Review and Meta-analysis. JAMA Oncol 2016;2(11):1460–1469
7 Osorio JA, Aghi MK. Optimizing glioblastoma resection: intraoperative mapping and beyond. CNS Oncol 2014;3(05):359–366
8 Shinoda J, Sakai N, Murase S, Yano H, Matsuhisa T, Funakoshi T. Selection of eligible patients with supratentorial glioblastoma multiforme for gross total resection. J Neurooncol 2001;52(02): 161–171
9 Tunthanathip T, Madteng S. Factors associated with the extent of resection of glioblastoma. Precis Cancer Med 2020http://dx.doi.org/10.21037/pcm.2020.01.01
10 Newgard CD, Hedges JR, Arthur M, Mullins RJ. Advanced statistics: the propensity score–a method for estimating treatment effect in observational research. Acad Emerg Med 2004;11(09):953–961
11 Tanprasertkul C, Patumanond J, Manusook S, et al. Recurrence of Endometrioma Following Conservative Ovarian Endometrioma Cystectomy: Laparoscopy versus Laparotomy. J Med Assoc Thai 2015;98(98, Suppl 3):S96–S100
12 Agrawal D, Raghavendran K, Schaubel DE, Mishra MC, Rajajee V. A Propensity Score Analysis of the Impact of Invasive Intracranial Pressure Monitoring on Outcomes after Severe Traumatic Brain Injury. J Neurotrauma 2016;33(09):853–858. Doi: 10.1089/neu.2015.4015
13 Cepeda S, Castaño-León AM, Munarriz PM, et al. Effect of decompressive craniectomy in the postoperative expansion of traumatic intracerebral hemorrhage: a propensity score-based analysis. J Neurosurg 2019;26:1–13. Doi: 10.3171/2019.2.JNS182025
14 Tunthanathip T, Sangkhathat S, Tanvejsilp P, Kanjanapradit K. Impact of IDH1 Mutation and MGMT Promoter Methylation in Patients with Glioblastoma. [dissertation]. Songkhla: Prince of Songkla University; 2020
15 Vecht CJ, Avezaat CJJ, van Putten WL, Eijkenboom WM, Stefanko SZ. The influence of the extent of surgery on the neurological function and survival in malignant glioma. A retrospective analysis in 243 patients. J Neurol Neurosurg Psychiatry 1990;53(06): 466–471
16 Bloch O, Han SJ, Cha S, et al. Impact of extent of resection for recurrent glioblastoma on overall survival: clinical article. J Neurosurg 2012;117(06):1032–1038
17 Ahmadipour Y, Kaur M, Pierscianek D, et al. Association of Surgical Resection, Disability, and Survival in Patients with Glioblastoma. J Neurol Surg A Cent Eur Neurosurg 2019;80 (04):262–268
18 Hsieh FY. Comparing sample size formulae for trials with unbalanced allocation using the logrank test. Stat Med 1992;11(08): 1091–1098. Doi: 10.1002/sim.4780110810
19 Ho D, Imai K, King G, et al. Package 'MatchIt'. https://cran.r-project.org/web/packages/MatchIt/MatchIt.pdf/2018 Accessed 13 March 2019.
20 Austin PC. An Introduction to Propensity Score Methods for Reducing the Effects of Confounding in Observational Studies. Multivariate Behav Res 2011;46(03):399–424
21 Stummer W, Pichlmeier U, Meinel T, Wiestler OD, Zanella F, Reulen HJALA-Glioma Study Group. Fluorescence-guided surgery with 5-aminolevulinic acid for resection of malignant glioma: a randomised controlled multicentre phase III trial. Lancet Oncol 2006;7(05):392–401
22 Stummer W, Reulen HJ, Meinel TALA-Glioma Study Group. , et al; . Extent of resection and survival in glioblastoma multiforme: identification of and adjustment for bias. Neurosurgery 2008; 62(03):564–576, discussion 564–576
23 Slof J, Díez Valle R, Galván J. Cost-effectiveness of 5-aminolevulinic acid-induced fluorescence in malignant glioma surgery. Neurologia 2015;30(03):163–168. Doi: 10.1016/j.nrl.2013.11.002
24 Tunthanathip T, Kanjanapradit K. Glioblastoma Multiforme Associated with Arteriovenous Malformation: A Case Report and Literature Review. Ann Indian Acad Neurol 2020;23(01):103–106
25 Liu Q, Liu Y, Li W, et al. Genetic, epigenetic, and molecular landscapes of multifocal and multicentric glioblastoma. Acta Neuropathol 2015;130(04):587–597
26 Thomas RP, Xu LW, Lober RM, Li G, Nagpal S. The incidence and significance of multiple lesions in glioblastoma. J Neurooncol 2013;112(01):91–97
27 Tunthanathip T, Sangkhathat S, Tanvejsilp P, Kanjanapradit K. The clinical characteristics and prognostic factors of multiple lesions in glioblastomas. Clin Neurol Neurosurg 2020;195:105891
28 Streiner DL, Norman GR. The pros and cons of propensity scores. Chest 2012;142(06):1380–1382
29 Tunthanathip T, Sangkhathat S. Temozolomide for patients with wild-type isocitrate dehydrogenase (IDH) 1 glioblastoma using propensity score matching. Clin Neurol Neurosurg 2020; 191:105712. Doi: 10.1016/j.clineuro.2020.105712
30 Cottone F, Anota A, Bonnetain F, Collins GS, Efficace F. Propensity score methods and regression adjustment for analysis of nonrandomized studies with health-related quality of life outcomes. Pharmacoepidemiol Drug Saf 2019;28(05):690–699. Doi: 10.1002/pds.4756

Hydrodynamic Considerations VI: Temporary Shunting for Intraventricular Hemorrhage: Observational Study of Two Treatment Variants

Considerações hidrodinâmicas VI: Drenagem temporária nas hemorragias intraventriculares. Estudo observacional de duas variantes de tratamento

Victor Beneditti Guimarães[1] Felipe Henrique Muniz[1] Jakeline Flávia Sertório Santos[1] Raphael Bertani[1] Ruy Monteiro[2] Angelo Luiz Maset[3] Dionei Moraes[4]

[1] Faculdade de Medicina de São José do Rio Preto, São José do Rio Preto, SP, Brazil
[2] Department of Neurosurgery, Hospital Municipal Miguel Couto, Rio de Janeiro, RJ, Brazil
[3] Department of Neurosurgery, Hospital de Base de São José do Rio Preto, São José do Rio Preto, SP, Brazil
[4] Department of Neurosurgery, Faculdade de Medicina de São José do Rio Preto, São José do Rio Preto, SP, Brazil,

Address for correspondence Angelo Luiz Maset, MD, Av Carlos de Arnaldo Silva, 360, Village Sta. Helena, São Jose do Rio Preto, SP, 15091-610, Brazil (e-mail: maset@terra.com.br).

Arq Bras Neurocir 2021;40(1):44–50.

Abstract

Introduction Patients who have external ventricular drainage (EVD) inserted are prone to many risks and complications. Intraventricular hemorrhage (IVH) is a frequent and life-threatening complication for spontaneous intracerebral hemorrhage (ICH) and results in an increased morbidity and mortality for those patients. An EVD insertion is a frequent surgical procedure for those with IVH. However, it is also known that IVH patients have a much higher rate of ventricular catheter occlusion. We hypothesize that blood clots have a predominant participation as a pathophysiological mechanism for EVD occlusion, and that a different and more appropriate catheter design might decrease the occlusion rate occurring during the utilization of EVDs on patients with IVH and, therefore, reduce implantation time.

Methods The electronic data sheets of 30 patients with spontaneous IVH from March 2014 until April 2015 were evaluated. Two concepts in catheter design were evaluated: A group of 15 patients with a conventional type of catheter inserted was identified as Group C (conventional). A group of 15 patients with a new design of catheter inserted was identified as Group H (hemorrhagic). Both groups were compared regarding survival end parameters, outcomes, days spent in intensive care units (ICUs) and time spent with EVDs implanted.

Results Hospitalization at the ICU was statistically significantly reduced for Group H compared with Group C. There was no significant difference among the hospitalization

Keywords
- external ventricular drainage
- intraventricular hemorrhage
- intracerebral hemorrhage
- intraventricular catheter

received March 30, 2020
accepted August 5, 2020
published online January 18, 2021

DOI https://doi.org/10.1055/s-0040-1718428.
ISSN 0103-5355.

Thieme Revinter Publicações Ltda., Rua do Matoso 170, Rio de Janeiro, RJ, CEP 20270-135, Brazil

days between both groups. There was no statistical difference either for acute hydrocephalus or death rate. External ventricular drainage implantation days were significantly reduced for Group H related to Group C.

Conclusion The results of the present study points to the fact that, although apparently the new catheter design did not change some secondary complications such as hydrocephalus and hospitalization rate, it seems that a better or specifically designed catheter for IVH purposes might lead to less ICU hospitalization days and EVD implantation days, two factors that have economic impact on healthcare due to the reduction of hospitalization costs and reduced incidence of related complications. The information obtained by this preliminary study should be grounded by a larger, more detailed and prospective evaluation; if these preliminary data are maintained, the new design should be considered for IVH associated EVDs insertions.

Resumo

Pacientes que utilizam drenagem ventricular externa (DVE) estão sujeitos a muitos riscos e complicações. A hemorragia intraventricular (IVH) é uma complicação frequente na hemorragia intracerebral espontânea (HIC) e resulta em um aumento da morbidade e mortalidade para esses pacientes. A inserção de DVE é um procedimento cirúrgico frequente para pessoas com HIV. No entanto, também se sabe que os pacientes com HIV têm uma taxa muito maior de oclusão do cateter ventricular. Nossa hipótese é que os coágulos sanguíneos têm uma participação predominante como um mecanismo fisiopatológico para a oclusão da DVE, e que um design de cateter diferente e mais apropriado pode diminuir a taxa de oclusão que ocorre durante a utilização de DVEs em pacientes com IVH e, portanto, reduzir o tempo de implantação.

Métodos Foram avaliadas as planilhas eletrônicas de 30 pacientes com HIV espontânea de março de 2014 a abril de 2015. Dois conceitos no desenho do cateter foram avaliados: Um grupo de 15 pacientes com um tipo convencional de cateter inserido foi identificado como Grupo C (convencional). Um grupo de 15 pacientes com um novo desenho de cateter inserido foi identificado como Grupo H (hemorrágico). Ambos os grupos foram comparados em relação aos parâmetros finais de sobrevivência, resultados, dias passados em unidades de terapia intensiva (UTI) e tempo gasto com EVDs implantados.

Resultados A internação na UTI foi estatisticamente reduzida para o Grupo H em comparação com o Grupo C. Não houve diferença significativa entre os dias de internação entre os dois grupos. Não houve diferença estatística para hidrocefalia aguda ou taxa de mortalidade. Os dias de implantação de drenagem ventricular externa foram significativamente reduzidos para o Grupo H em relação ao Grupo C.

Conclusão Os resultados do presente estudo apontam para o fato de que, embora aparentemente o novo desenho do cateter não tenha alterado algumas complicações secundárias, como hidrocefalia e taxa de hospitalização, parece que uma melhor ou específica.

Palavras-chave
- drenagem ventricular externa
- hemorragia intraventricular
- hemorragia intracerebral
- cateter intraventricular

Introduction

Although intracerebral hemorrhage (ICH) estimates are between 10 and 15% of all strokes,[1,2] it is related to worse prognosis compared with any other isolated stroke event, especially in the presence of intraventricular hemorrhage (IVH).[1,3,4] Morbidity and mortality rates are in between 50 and 80% [2,5] When IVH occurs, blood drawn into the cerebral ventricles and/or cisterns often causes, as an immediate result, a partial or total blockage of the cerebrospinal fluid (CSF) pathways, immunological deficiency,[4] higher rates of infection,[2,4] acute hydrocephalus and intracranial hypertension,[5,6] possibly requiring surgical treatment in an urgent basis. Ultimately, IVH is a life-threatening condition, which increases morbidity and mortality when associated with ICH. Surgical management consider external ventricular drainage (EVD) alone, bilateral EVDs, fibrinolytics + EVD, endoscopic surgery, endoscopic surgery + EVD, among others.[5]

However, it is also known that IVH patients have a much higher rate of ventricular catheter occlusion. We hypothesize

that blood clots have a predominant participation as a pathophysiological mechanism for EVD occlusion, and that a different and more appropriate catheter design might decrease the occlusion rate occurring during the utilization of EVDs in patients with IVH and, therefore, reduce implantation time.

Material and Methods

The present study was approved by the Fundação Faculdade Regional de Medicina (FUNFARME, in the Portuguese acronym) Ethics Committee. It is an observational retrospective study done with 30 nontraumatic ICH patients with extension to the ventricular cavities (IVH) during the period of March 1st 2014 until April 30th 2015 at FUNFARME, Sao José do Rio Preto, state of São Paulo, Brazil. In the present preliminary study, we compared two different concepts of ventricular catheters. At first, we searched for an EVD model that follows the recommendations of Tronnier et al.[7] for an adequate EVD to minimize mechanical failures and infections. There were a total number of 30 patients, 15 patients for each conceptual group. The first concept was denominated as C (conventional, because it is the conventional catheter offered in drainage sets for this manufacturer). It is a 23 cm length silicone tubing, closed tip, 1,7 I.D. x 3,0 mm O.D., with 12 oblong holes 1 × 2 mm each, the more distant hole being 17 mm distant from the catheter tip. (►**Fig. 1A**). The model C product has a Brazilian ANVISA registration # 10175060016. The second group was identified as H (hemorrhage), and it has an ANVISA registration # 10175060037, both made commercially available by the same manufacturer. Group H patients (Type H catheter, ►**Fig. 1B**) included a larger bore, open end tip, 2,6 I.D. x 4,0 m O.D, four oblong and bigger sized lateral holes, the more distant hole being 15 mm distant from the catheter tip. The type H catheter was specifically designed for IVH, in an attempt to decrease the incidence of blockage caused by particles in the CSF that regularly would clog the small orifices, the catheter lumen, and/or the connector site into the EVD set in conventional EVDs and, consequently, would require surgical revision or manual unclogging procedures at bedside leading to either increased infection rates, increased number of ICU hospitalization days, increased number of hospitalization days, acute hydrocephalus (defined as hydrocephalus while at the hospital), or increased number of EVD implantation days.[6]

The objective of the present study was to verify the efficacy of two different external ventricular drainage catheter concepts regarding: 1. ICU hospitalization days; 2. EVD implantation days, and 3. Occurrence of acute hydrocephalus. Acute hydrocephalus was defined as hydrocephalus while the patient was hospitalized.

Inclusion criteria: spontaneous intracranial hemorrhage seen on initial computed tomography (CT) scan at the emergency room (ER), Glasgow coma score (GCS)[8] < 9 at admission after patient resuscitation, ICH ≤ 3 (ICH score),[9] to whom EVD insertion was clinically indicated. The target ventricle for Group H was always the most blood compromised ventricle. For Group C, we followed the literature, inserting them in the least compromised ventricle. The reasoning for that was to make sure that a larger bore catheter would unequivocally have some effect on drainage of liquified blood.

Exclusion criteria: abnormal coagulation patterns at initial blood sample, initial utilization of antifibrinolytics, ICH score > 3 or GCS > 9 at resuscitation

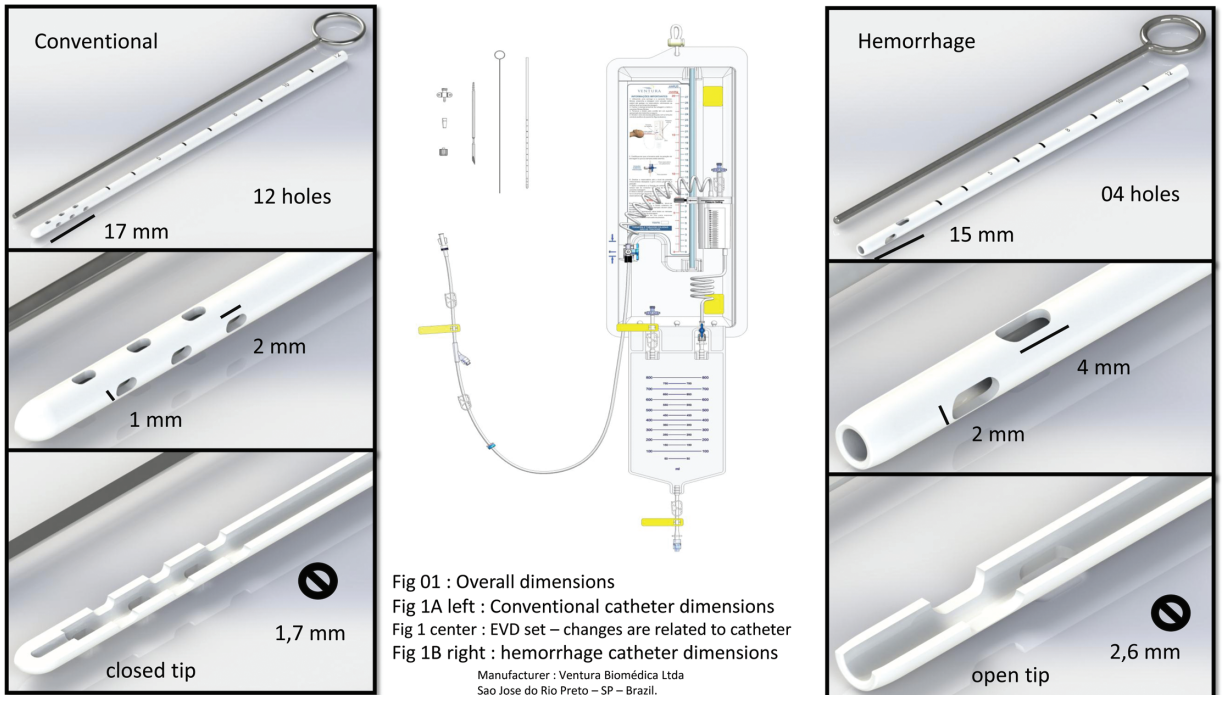

Fig. 1 Overall dimensions. (**A**) Left: Conventional catheter dimensions. (**B**) Center: EVD set – changes are related to catheter. (**C**) Right: hemorrhage catheter dimensions.

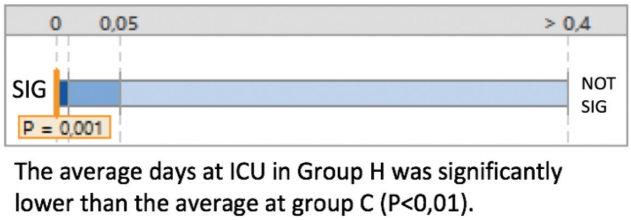

Fig. 2 (A) Intensive care unit average days - comparison between Group H and Group C. Intensive care unit average days for Group H was statistically significant smaller when compared to Group C at $p = 0.001$. (**B**) Ventricular catheter implantation days. Ventricular catheter implantation days for Group H was statistically significant compared with Group C.

Procedures

After approval by the Ethics Committee, electronic files were reviewed and the patients were identified. Collected data were age, pupils at admission, GCS score, pre-existent pathologies, and type of catheter used. It was possible to select 30 patients, 15 patients for each group. Both groups were then compared according to the parameters described above.

Table II II-A Total Hospitalization days

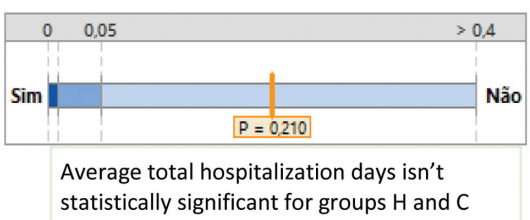

II-B Hydrocephalus

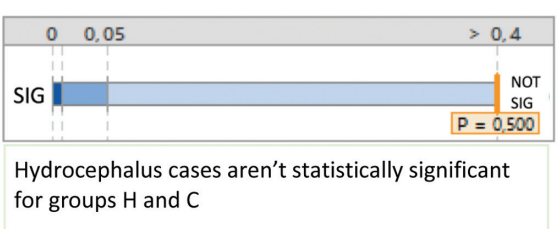

II-C Deaths

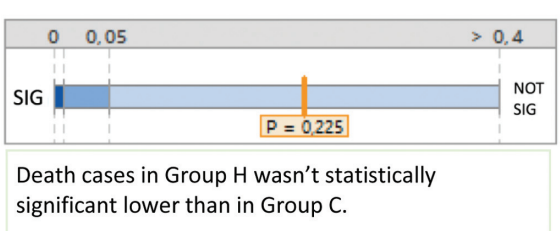

Fig. 3 (A) Total Hospitalization days. Average total hospitalization days isn't statistically significant for groups H and C. (**B**) Hydrocephalus. Hydrocephalus cases aren't statistically significant for groups H and C. (**C**) Deaths. Death cases in Group H wasn't statistically significantly lower than in Group C.

Data Analysis

We used parametric tests (t-student test for ordinary variables and the chi-squared test for nominal variables) and a level of significance of $p \leq 0.05$.

Results

The average ICU hospitalization days for group H was 14.4 ± 8.4 standard deviation (SD) versus 24.4 ± 7.9 days for group C, a mean difference of 9.8 ICU hospitalization days. This difference was statistically significant ($p = 0.001$ ►**Fig. 2A**). This result made us review the total hospitalization days, which was 21.4 ± 13.0 days for group H versus 25.94 ± 16.9 days for group C. This difference still was not statistically significant (►**Fig. 3A** $p = 0.21$). The number of patients who developed hydrocephalus between Groups H and C respectively were 4 and 5, percentual of 26.67 and 33.33% respectively, with no statistical significance (►**Fig. 2B** $p = 0.5$). Finally, the number of patients who died between Groups H and C were 8 and 11, percentual of 53.3% and 73.33% respectively, again with no statistical significance (►**Fig. 3C** $p = 0.225$). The average implanted catheter days between Group H and C was 7.7 ± 3.3 versus 11.2 ± 2.93 days for group C, a mean difference of 3.5 days favoring Group H. This difference was statistically significant at $p = 0.003$ (►**Fig. 2B**).

Discussion

It is reported that ICH accounts for between 10 and 30 incidents / 100.000 habitants, with an estimate of ~2 million strokes per year.[2] Intracranial hemorrhage with or without IVH accounts for 15% of all strokes, and subarachnoid hemorrhage (SAH) accounts for 5% of all strokes. The prognosis for ICH is disproportional and devastating, reaching between 35 and 50% of mortality for 30 days, being half of them during the first 2 days; it is even higher when associated with IVH, reaching between 50 and 80% of mortality for 30 days. Intraventricular hemorrhage occurs in between 5–10% of SAH patients and in up to 40% of ICH patients. Only 38% of ICH patients survive for 1 year. Therefore, massive IVHs require aggressive and rapid management to decrease intracranial hypertension, mainly due to acute hydrocephalus. The immediate control of intracranial pressure (ICP) by external ventricular drainage is a salvage procedure; the amount of intraventricular blood is a strong negative prognostic predictor on outcome.[1,3,4] External ventricular drainages are the most common surgical procedure for IVH, and they are indicated for the control of intracranial pressure as the blood and blood clots compromise acutely the CSF circulation. External ventricular drainages are hydraulic devices that work against a positive pressure, regulated by the positioning aside the patient at the ICU.[10] It is known that EVDs do not decrease morbidity and mortality, but catheter occlusions do increase de risk of infection, hydrocephalus and neurological deterioration. Yet, EVD insertions are at large the most common choice of treatment,[5,11] and the search for additional and/or concomitant treatments is constant.

Catheters are usually inserted in the cleanest lateral ventricle. As mentioned in the Methods section, our target ventricle for the Group H was the most blood compromised ventricle. The whole of blood into the ventricles and the catheter design has been a matter of discussion either on permanent shunts or EVDs.[6,11,12] Thomale et al[12] replaced a regular catheter design with 16 holes by a new design with 4 or 6 holes only, both with a closed end, maintaining the same diameter and distance among holes for all of them, but the maximum distance from the tip was 6,4 mm as compared with 15,4 mm from the conventional catheter. The 6-hole catheter was implanted in 55 hydrocephalic patients with a mean follow-up period of 15 ± 9 months. A total of 12 catheters were explanted, revealing an overall survival proportion of 77.4%. He concluded that "fewer amounts of perforations in the catheters with equal flow features might decrease this risk when catheters can be implanted with adequate precision. However, EVDs work in a different environment as compared to shunts, are short term implants, and therefore ventricular catheters face different CSF conditions, since those patients frequently are submitted to increased concentrations of proteins, debris and blood."

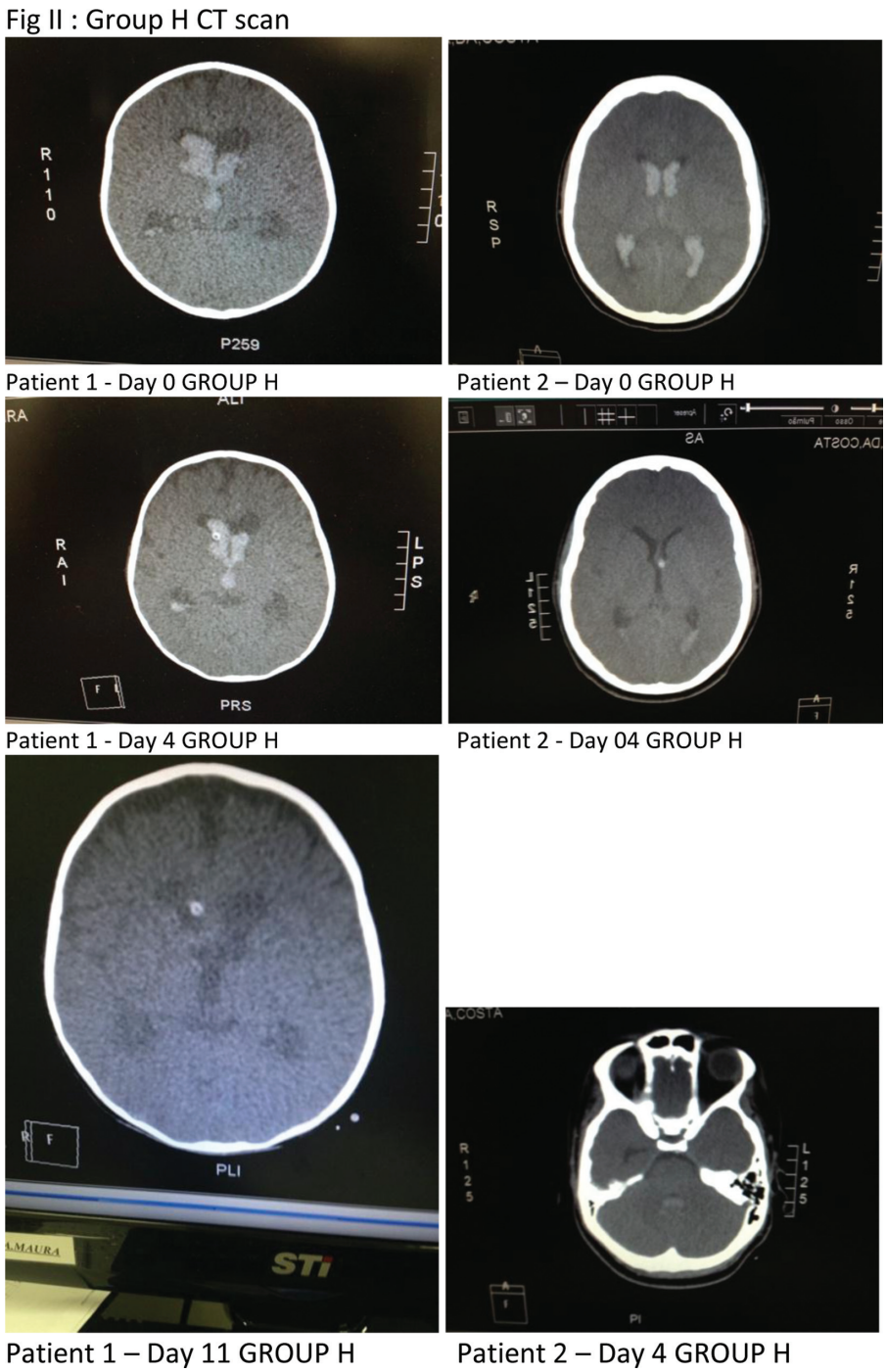

Fig. 4 Group H computed tomography scan. (**A**) Patient 1 - Day 0 GROUP H. (**B**) Patient 2–Day 0 GROUP H. (**C**) Patient 1 - Day 4 GROUP H. (**D**) Patient 2 - Day 04 GROUP H. (**E**) Patient 1–Day 11 GROUP H. (**F**) Patient 2–Day 4 GROUP H.

Tronnier et al,[7] in 1991, evaluated 12 commercially available sets for drainage of CSF for several mechanical aspects. "All systems showed considerable deficiencies in their reliability and handling. None of them can be recommended without certain restrictions and they should all be revised." Thus, they suggested changes in the catheter hole design, mentioning specifically that in "75% of our patients the CSF is hemorrhagic or very viscous and the risk of catheter occlusion is high." Length markers, type of catheter fixation, surface properties, one-way valve, orthograde and retrograde flows, fixation and adjustment of the drip chamber, system ventilation and collection bag also were all matter of evaluation and further suggestions. The choice of the EVD for the present work was based on those presumptions, and we selected the one that included most of those attributes. We did not implant two catheters simultaneously in either group. Basaldella et al[13] recommended that "tetra-ventricular blood inundation should be managed using bilateral ventricular catheters, which frequently become obstructed by blood clots and need to stay in place for a longer period for blood washout." Naff et al[14] clearly demonstrated that the percentage of clot clearance is 10.8% per day and is independent from the initial clot volume, patient age and gender, type of underlying hemorrhage, and use of EVD. Another approach is endoscopic surgery, sucking the blood clots and apparently improving CSF circulation, although EVDs are still inserted after endoscopic surgery. Basaldella[13] compared retrospectively EVD alone (group B; $n = 48$) versus endoscopic surgery + EVD (group A, $n = 48$). They all had acute hydrocephalus before obstruction, 3rd and 4th ventricles obstruction, similar average Glasgow Coma Scale (GCS), similar average GRAEB[15] scale. His conclusions, among others, were "the endoscopic procedure resulted in adequate clot removal. Mean GRAEB score changed from 9.5 to 3.8; endoscopic aspiration had an EVD in place for 0.18 days fewer than patients treated with an EVD alone. Neuroendoscopy plus external drainage reduces shunting rates by 34% when compared with external drainage alone. However, and as seen in that same work,[13] patients end up reaching the same modified Rankin scale[16] and, on average, the EVDs on patients submitted to endoscopy remained only 0.18 days less. Although endoscopy remains elusive regarding several aspects, for sure the ventricular system is cleaned much faster and there is less exposition of the subarachnoid vessels to the products resulting from degradation of the blood. Tuhrim et al[17] did a prospective study to determine the prognostic significance and pathophysiologic implications of intraventricular extension of ICH and showed that 30-day mortality was much higher in patients with IVH. There was a direct correlation between IVH volume and poor outcome, and this correlation persisted when comparing for the presence or absence of hydrocephalus and size of associated ICH, thus establishing IVH volume as an independent prognostic factor of poor outcome, independent of the volume of ICH.[17] Another technique is the use of fibrinolytics agents to dissolve clots. This technique tries to expedite the ventricular blood clots and decrease mortality and morbidity. However, results from Randomised, multicentre, multiregion, placebo-controled trial (CLEAR III)[18] did not get the expected results; irrigation with alteplase did not substantially improve functional outcomes at the mRS3 cutoff compared with irrigation with saline. Alteplase demonstrated to be a safe procedure, though. In the present preliminary work, we utilized a recent EVD commercially available in Brazil for hemorrhage. Since the proposal of the EVD made sense to us, we decided to use 15 EVDs for an initial assessment. Along with the utilization, we observed a striking difference between both types of catheter regarding drainage capability. The elimination of clots that were unthinkable on a regular EVD was a common event for the hemorrhage type, and the occlusion rate was small. The CSF became cleaner faster with the hemorrhage

Fig III : Example of Conventional group.

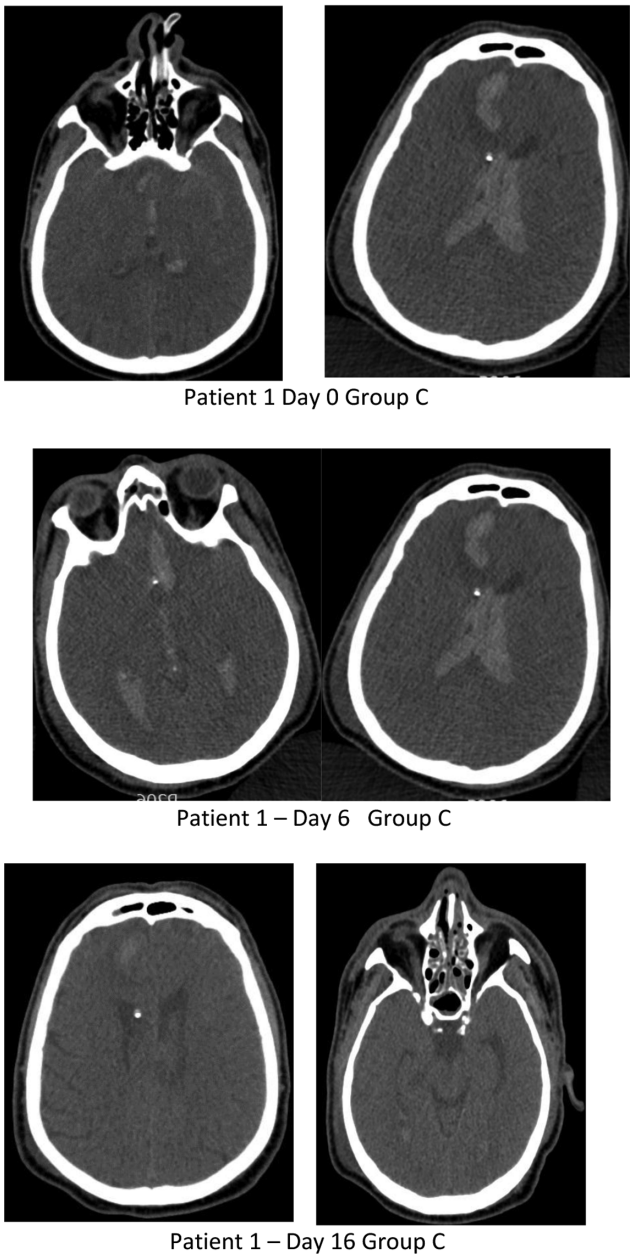

Fig. 5 Example of Conventional group. (**A**) Patient 1 Day 0 Group C. (**B**) Patient 1–Day 6 Group C. (**C**) Patient 1–Day 16 Group C.

type of catheter. The chosen EVD system has some important details that avoid mechanical clogging or occlusion for several reasons. A common weakness in EVD refers to the disparity of the lumen of the male connector to insert into the ventricular catheter and the catheter itself. This EVD has the lumen of the ventricular catheter as the smallest diameter along the whole EVD tubing set. Another advantage is the horizontal fixation tab as part of the body of the connector. There is no chance of the ventricular catheter to slip through the fixation tab and allow vertical slides by the catheter. As a preliminary work, there was no randomization regarding imaging dates from the ictus day. Computed tomographies were made according to the necessity of each patient (►**Fig. 4** for Group H and ►**Fig. 5** for Group C). Although with a small number of patients, the optimistic results regarding ICU days and ventricular catheter implantation days between both types of catheter led us to maintain the initial target of 15 patients and organize a trial in such a way that we could collect a larger number of patients taking into consideration several other factors. At least for those 15 patients, we did not observe any additional adverse events for using a larger bore ventricular catheter.

Conclusion

Despite the small number of patients, some results seemed to favor the type H ventricular catheter and encouraged us to proceed with a trial. The reduced number of ICU days and ventricular catheter implantation time favoring Group H reached statistical significance at $p < 0.01$. Considering the daily cost for hospitalization in our country, the impact on the daily ICU costs due to use of Type H catheters may represent an interesting tool for cost reduction and maybe to avoid collateral damage to the patient. These results are motivating for a prospective, more detailed study with a larger number of patients.

Conflict of Interests

The authors have no conflict of interests to declare. The Doctor Angelo Maset declares that he is CEO and owner of the company Ventura Biomédica.

References

1 González-Pérez A, Gaist D, Wallander MA, McFeat G, García-Rodríguez LA. Mortality after hemorrhagic stroke: data from general practice (The Health Improvement Network). Neurology 2013;81(06):559–565
2 Ministério da Saúde Secretaria de Atenção à Saúde, Departamento de atenção especializada, Coordenação geral de média e alta complexidade, Coordenação geral de atenção hospitalar. 2013. Manual de Rotinas para atenção ao AVC. Ministério da Saúde, Secretaria de Atenção à Saúde, Departamento de atenção especializada. Brasília: Editora do Ministério da Saúde, 2013. 50p.
3 Gaberel T, Magheru C, Parienti JJ, Huttner HB, Vivien D, Emery E. Intraventricular fibrinolysis versus external ventricular drainage alone in intraventricular hemorrhage: a meta-analysis. Stroke 2011;42(10):2776–2781
4 Sykora M, Diedler J, Poli S, et al. Autonomic shift and increased susceptibility to infections after acute intracerebral hemorrhage. Stroke 2011;42(05):1218–1223
5 Hughes JD, Puffer R, Rabinstein AA. Risk factors for hydrocephalus requiring external ventricular drainage in patients with intraventricular hemorrhage. J Neurosurg 2015;123(06):1439–1446
6 Wang K, Du HG, Yin LC, He M, Hao BL, Chen L. Which side of lateral ventricles to choose during external ventricular drainage in patients with intraventricular hemorrhage: ipsilateral or contralateral? J Surg Res 2013;183(02):720–725
7 Tronnier V, Aschoff A, Hund E, Hampl J, Kunze S. Commercial external ventricular drainage sets: unsolved safety and handling problems. Acta Neurochir (Wien) 1991;110(1-2):49–56
8 Teasdale G, Jennett B. Assessment of coma and impaired consciousness. A practical scale. Lancet 1974;2(7872):81–84
9 Hemphill JC III, Bonovich DC, Besmertis L, Manley GT, Johnston SC. The ICH score: a simple, reliable grading scale for intracerebral hemorrhage. Stroke 2001;32(04):891–897
10 Maset AL, Bim C, Camilo JR, Mansur SS, Vieira ER Caracterização hidrodinâmica de dispositivos para drenagem externa de líquido cefalorraquidiano. *CIBEM 10*, Porto, Portugal, 2011
11 Dey M, Jaffe J, Stadnik A, Awad IA. External ventricular drainage for intraventricular hemorrhage. Curr Neurol Neurosci Rep 2012; 12(01):24–33
12 Thomale UW, Hosch H, Koch A, et al. Perforation holes in ventricular catheters–is less more? Childs Nerv Syst 2010;26 (06):781–789
13 Basaldella L, Marton E, Fiorindi A, Scarpa B, Badreddine H, Longatti P. External ventricular drainage alone versus endoscopic surgery for severe intraventricular hemorrhage: a comparative retrospective analysis on outcome and shunt dependency. Neurosurg Focus 2012;32(04):E4
14 Naff NJ, Hanley DF, Keyl PM, et al. Intraventricular thrombolysis speeds blood clot resolution: results of a pilot, prospective, randomized, double-blind, controlled trial. Neurosurgery 2004; 54(03):577–583, discussion 583–584
15 Graeb DA, Robertson WD, Lapointe JS, Nugent RA, Harrison PB. Computed tomographic diagnosis of intraventricular hemorrhage. Etiology and prognosis. Radiology 1982;143(01):91–96
16 van Swieten JC, Koudstaal PJ, Visser MC, Schouten HJA, van Gijn J. Interobserver agreement for the assessment of handicap in stroke patients. Stroke 1988;19(05):604–607
17 Tuhrim S, Horowitz DR, Sacher M, Godbold JH. Volume of ventricular blood is an important determinant of outcome in supratentorial intracerebral hemorrhage. Crit Care Med 1999;27(03): 617–621
18 Hanley DF, Lane K, McBee NCLEAR III Investigators. et al. Thrombolytic removal of intraventricular haemorrhage in treatment of severe stroke: results of the randomised, multicentre, multiregion, placebo-controlled CLEAR III trial. Lancet 2017;389 (10069):603–611

Pterygopalatine Fossa: Microsurgical Anatomy and its Relevance for Skull Base Surgery

Fossa Pterigopalatina: Anatomia microcirúrgica e sua relevância para a cirurgia da base do crânio

Gustavo Rassier Isolan[1,2] Julio Mocellin Bernardi[2] João Paulo Mota Telles[3]
Nícollas Nunes Rabelo[3] Eberval Gadelha Figueiredo[3]

[1] The Center for Advanced Neurology and Neurosurgery (CEANNE), Brazil
[2] Diane and M Gazi Yasargil Microsurgical Laboratory, University of Arkansas for Medical Sciences, Little Rock, AK, United States of America
[3] Division of Neurosurgery, Hospital das Clínicas da Faculdade de Medicina da Universidade de São Paulo, São Paulo, SP, Brazil

Address for correspondence Eberval Gadelha Figueiredo, MD, PhD, Division of Neurosurgery, Hospital das Clínicas da Faculdade de Medicina da Universidade de São Paulo, Av. Dr. Eneas de Aguiar, 255, São Paulo, SP, 05403-010, Brazil (e-mail: ebgadelha@yahoo.com).

Arq Bras Neurocir 2021;40(1):51–58.

Abstract

Introduction The purpose of this study was to define the anatomical relationships of the pterygopalatine fossa (PPF) and its operative implications in skull base surgical approaches.

Methods Ten cadaveric heads were dissected at the Dianne and M Gazi Yasargil Educational Center MicrosurgicaLaboratory, in Little Rock, AK, USA. The PPF was exposed through an extended dissection with mandible and pterygoid plate removal.

Results The PPF has the shape of an inverted cone. Its boundaries are the pterygomaxillary fissure; the maxilla, anteriorly; the medial plate of the pterygoid process, and greater wing of the sphenoid process, posteriorly; the palatine bone, medially; and the body of the sphenoid process, superiorly. Its contents are the maxillary division of the trigeminal nerve and its branches; the pterygopalatine ganglion; the pterygopalatine portion of the maxillary artery (MA) and its branches; and the venous network. Differential diagnosis of PPF masses includes perineural tumoral extension along the maxillary nerve, schwannomas, neurofibromas, angiofibromas, hemangiomas, and ectopic salivary gland tissue. Transmaxillary and transpalatal approaches require extensive resection of bony structures and are narrow in the deeper part of the approach, impairing the surgical vision and maneuverability. Endoscopic surgery solves this problem, bringing the light source to the center of the surgical field, allowing proper visualization of the surgical field, extreme close-ups, and different view angles.

Keywords
- microsurgery
- neuroanatomy
- pterygopalatine fossa
- skull base

received July 27, 2020
accepted August 5, 2020
published online October 16, 2020

DOI https://doi.org/10.1055/s-0040-1718430.
ISSN 0103-5355.

Thieme Revinter Publicações Ltda., Rua do Matoso 170, Rio de Janeiro, RJ, CEP 20270-135, Brazil

Conclusion We provide detailed information on the fossa's boundaries, intercommunications with adjacent structures, anatomy of the maxillary artery, and its variations. It is discussed in the context of clinical affections and surgical approaches of this specific region, including pterygomaxillary disjunction and skull base tumors.

Resumo

Introdução O presente estudo objetiva definir as relações anatômicas da fossa pterigopalatina (FPP) e suas implicações na cirurgia de base de crânio.

Métodos Dez cadáveres foram dissecados no centro educacional *Dianne and M Gazi Yasargil,* em Little Rock, AK, EUA. A FPP foi exposta via uma dissecção estendida com remoção da mandíbula e placa pterigoidea.

Resultados A FPP tem o formato de um cone invertido. Seus limites são a fissure pterigomaxilar; a maxila, anteriormente; a placa medial do processo pterigoide e a asa maior do processo esfenoide, posteriormente; o osso palatino, medialmente; e o corpo do processo esfenoide, superiormente. Os conteúdos são a divisão maxilar do nervo trigêmeo e seus ramos; o gânglio pterigopalatino; a porção pterigopalatina da artéria e seus ramos; e o plexo venoso. O diagnóstico diferencial de massas da FPP inclui extensão perineural de tumores sobre o nervo maxilar, schwannomas, neurofibromas, angiofibromas, hemangiomas e tecido salivar ectópico. Abordagens transmaxilares e transpalatais requerem ressecção extensa de estruturas ósseas e são estreitas em sua porção mais profunda, dificultando a visão cirúrgica. Cirurgia endoscópica é uma solução para tal, iluminando e possibilitando visualização adequada do centro do campo cirúrgico, aproximação extrema e diferentes ângulos.

Conclusão Descreve-se detalhadamente os limites, intercomunicações e estruturas adjacentes à FPP, anatomia da artéria maxilar e suas variações, com contextualização clínica e cirúrgica.

Palavras-chave
- neuroanatomia
- fossa pterigopalatina
- base de crânio
- microcirurgia

Introduction

The pterygopalatine fossa (PPF) is a small area that lies between the maxilla and the middle cranial fossa. It contains multiple delicate vascular and nervous structures and is of great interest to neurosurgeons, otolaryngologists, and maxillofacial surgeons.

Tumors of the FPP are rare; however, their management poses numerous surgical challenges. Transmaxillary approaches are often associated with high morbidity, poor cosmetical results, and possibly bone development disorders. Endoscopic approaches have cosmetic and postoperative advantages, although limited in terms of hemostatic control.[1–3]

Anatomic knowledge of this particular region is paramount because the space is narrow, the structures are packed tightly, and accidental lesions could result in high morbidity. The purpose of the present study was to analyze the microsurgical anatomy of this area to define the anatomical relationships of the PPF with the respective surgical implications for skull base approaches.

Material and Methods

The dissections were performed by the main author on 10 cadaveric heads at the Dianne and MGazi Yasargil Educational Center Microsurgical Laboratory, in Little Rock, AK, USA. The heads were fixed in formalin. Arteries and veins were colored with latex to enhance their visibility. An anatomical dissection was done via a wide preauricular incision, ranging from the superior temporal line to the neck, on the anterior border of the sternocleidomastoid muscle at the level of the cricoid cartilage. The flap was displaced anteriorly.

The branches of the facial nerve and the parotid duct were dissected. The parotid fascia and parotid gland were removed, preserving the facial nerve. The masseter muscle was cleaned and resected. The superficial temporal fascia and the fat pad were removed along the zygomatic arch, which was then removed. The superficial temporal artery (STA) and the auriculotemporal nerve were identified over the deep temporal fascia. The coronoid process of the mandible was cut and reflected upward together with the temporal muscle tendon, while the insertion of the deep layer of the masseter muscle was resected. The mandible was cut at the level of the neck and the level of the angle. This part of the mandible was removed, and the structures of the infratemporal fossa (ITF) were identified. The IFT fossa muscles were resected, and the lateral pterygoid plate was removed to expose the PPF.

Results

Boundaries and Contents of the Pterygopalatine Fossa

The PPF has the shape of an inverted cone, having as apex the greater palatine canal. Its lateral boundary is the pterygomaxillary fissure (PMF), which communicates the PPF with the infratemporal fossa. The other boundaries of the PPF are the following: the maxilla, anteriorly; the medial plate of the

pterygoid process and greater wing of the sphenoid process, posteriorly; the palatine bone, medially; and the body of the sphenoid process, superiorly. The maxillary artery (MA), arising medially to the neck of the mandible, and bending in an anterior, medial and slightly superior direction, enters the PPF through the PMF, giving several branches before entering the sphenopalatine foramen as the sphenopalatine artery. The MA can be divided into three parts: the mandibular, pterygoid, and pterygopalatine portions.

The contents of the PPF are the following: (1) maxillary division of the trigeminal nerve and its branches; (2) pterygopalatine ganglion; (3) pterygopalatine portion of MA and its branches; (4) venous network surrounding the MA. The maxillary nerve innervates the lateral aspect of the cheek, the temple, and the maxillary teeth. Its branches are the zygomatic nerve, one or two posterior superior alveolar nerves, infraorbital nerve, and roots to the sphenopalatine ganglion. The maxillary artery is a significant source of blood supply to the deep structures of the face, and also gives rise to the middle meningeal artery. The pterygopalatine ganglion gives rise to postganglionic fibers to the lacrimal gland and glands in the nasal and nasopharyngeal mucosa. It is the largest parasympathetic ganglion in the body.

Table 1 Communications of the pterygopalatine fossa to adjacent structures

Structure	Communication provided by
Infratemporal fossa	Pterygomaxillary fissure
Orbit	Inferior orbital fissure
Nasal cavity	Sphenopalatine foramen
Middle cranial fossa	Foramen rotundum
Palate	Greater and lesser palatine canals and foramina
Foramen lacerum	Pterygoid canal
Vault of pharynx	Pharyngeal canal

Table 2 Contents of the structures that communicate with the pterygopalatine fossa

Communication provided by	Contents
Foramen rotundum	Maxillary division of fifth cranial nerve
Sphenopalatine foramen	Sphenopalatine artery and vein Nasal branches of maxillary nerve
Greater and lesser palatine canals	Greater and lesser nerves, arteries, and veins Descending palatine artery
Pterygoid canal	Vidian nerves, arteries, and veins
Inferior orbital fissure	Zygomatic branch of maxillary nerve Infraorbital nerves, arteries, and veins
Pterygomaxillary fissure	Maxillary artery Posterior superior alveolar nerve, artery, and vein
Pharyngeal canal	Pharyngeal nerve, artery, and vein

The PPF is a neurovascular hub in the middle face. It communicates with the foramen lacerum, infratemporal fossa, middle cranial fossa, nasal cavity, orbit, and pharynx via foramina and fissures. A summary of the communications is shown in ►**Table 1**. The vascular and nervous structures arising from the PPF are described in ►**Table 2**. To reach the PPF, the ramus and condyle of the mandible were removed. The contents of the infratemporal fossa were removed using a lateral infratemporal approach.

The Maxillary Artery (MA)

The MA (►**Fig. 1**, structure number 5) was found deep into the mandibular ramus. It passed horizontally and gave rise to the buccal artery, which supplied the buccinator muscle. Then, it turned medially and crossed the PMF to arrive in the PPF, thus becoming the pterygopalatine portion of the MA.

Branches arising from this portion of the MA were located at approximately one-third of the height of the maxillary sinus' posterolateral wall. The artery entered the PMF in an anterior, medial, and superior direction, as previously described. While in the PMF, the MA originated two branches, namely, the infraorbital artery (IOA) and the posterosuperior alveolar artery (PSAA). Both arteries were located in the posterior wall of the maxilla. The PSAA entered into the posterosuperior alveolar foramen, while the IOA entered the infraorbital fissure.

After giving off these branches, the MA continued to the PPF. It then split into three arteries: the descending palatine artery (DPA), which supplied the palate; the artery of the pterygoid canal (or Vidian artery, VA); and the sphenopalatine artery (SPA). The PSAA and IOA branched from the MA

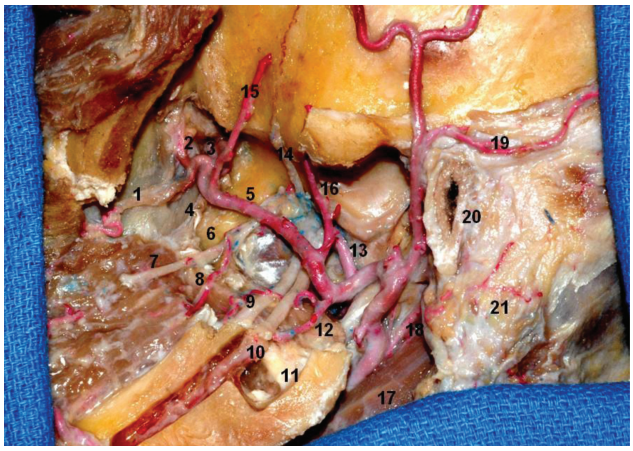

Fig. 1 Lateral view of the infratemporal fossa (ITF). The pterygopalatine fossa is medial to the lateral pterygoid plate. The lateral pterygoid process and the condylar process were removed. 1, posterior superior alveolar artery; 2, infraorbital artery; 3, sphenopalatine artery; 4, descending palatine artery (not injected); 5, maxillary artery; 6, lateral pterygoid plate; 7, buccal nerve; 8, buccal artery; 9, lingual nerve; 10, inferior alveolar nerve; 11, medial pterygoid muscle; 12, inferior alveolar artery; 13, middle meningeal artery; 14, deep temporal nerve; 15, anterior deep temporal artery; 16, posterior deep temporal artery; 17, digastric muscle (posterior belly); 18, posterior auricular artery; 19, posterior auricular artery; 20, external acoustic meatus; 21, mastoid.

with two different patterns. In the first one, a short common trunk arose from the MA, subsequently bifurcating to form both arteries. In the second pattern, the PSAA and IOA branched separately. According to Choi and Park,[4] both patterns occur with almost equal frequency.

Communications of the Pterygopalatine Fossa

The bony structures and communications of the PPF are illustrated in ►**Fig. 2**. Regarding the communications of the PPF, an interesting finding was the proximity of the foramen rotundum and pterygoid canal to the sphenoid

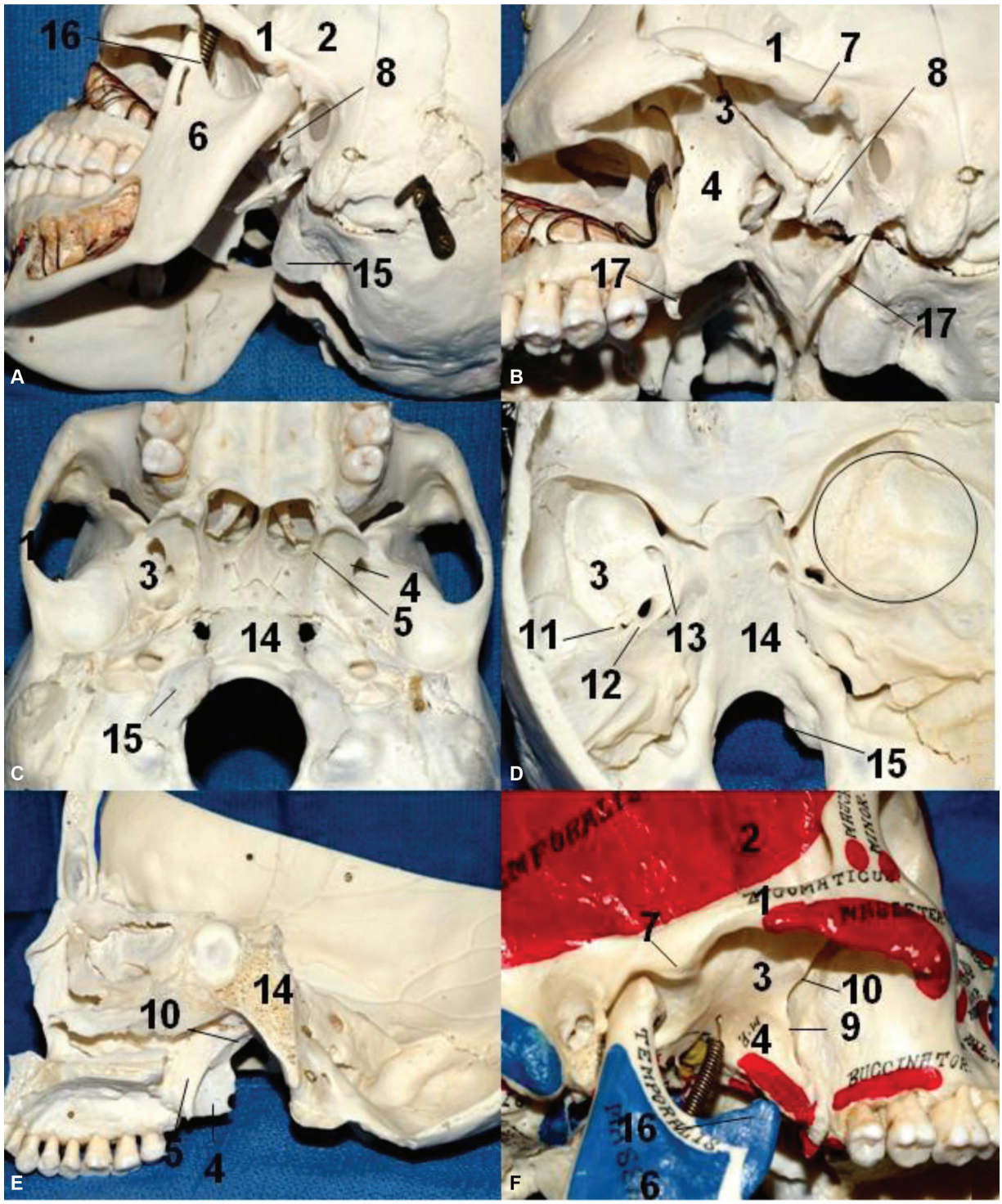

Fig. 2 Limits of the infratemporal fossa, pterygopalatine fossa and bone relationships. (A). Oblique lateral view of the ITF. (B) Same oblique lateral view after removal of the mandible. (C) Inferior aspect of the cranium. (D) Interior view of the cranial base. The circle on the right middle fossa represents approximately the correspondence of the ITF in the middle fossa. (E) Lateral view of the ITF after sagittal paramedian section. (F) Note that the depression of the mandible (open mouth) gives more access to the ITF laterally. 1, zygomatic process of the temporal bone; 2, temporal fossa; 3, greater wing of the sphenoid; 4, lateral pterygoid plate; 5, medial pterygoid plate; 7, articular tubercle of the temporal bone; 8, spine of the sphenoid bone; 9, pterygomaxillary fissure; 10, pterygopalatine fossa; 11, foramen spinosum; 12, foramen ovale; 13, foramen rotundum; 14, clivus; 15, occipital condyle; 16, coronoid process; 17, styloid process.

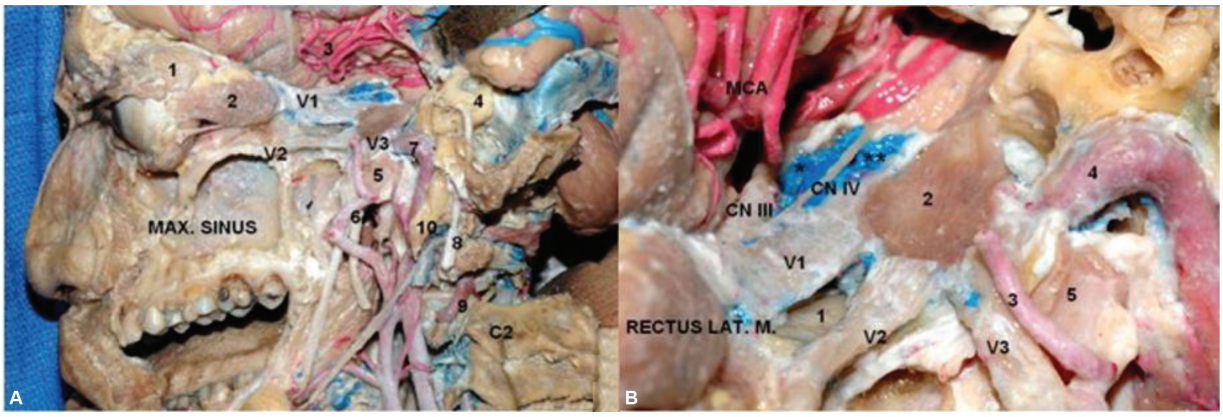

Fig. 3 Lateral view. (A). Were removed the lateral and anterior walls of the maxillary sinus, the walls of the orbit, and the orbital fat. The temporal lobe is displaced posteriorly to expose the cavernous sinus. The dura of the middle fossa was peeled away, and the bone of the middle fossa floor was drilled out to show the anatomical relationship between the temporal and infratemporal fossa structures. Mastoidectomy was performed, preserving the mastoid tip. 1. lacrimal gland; 2. rectus lateralis muscle; 3. middle cerebral artery; 4. otic capsule (semicircular canals); 5. Eustachian tube; 6. middle meningeal artery; 7. internal carotid artery (intrapetrous portion); 8. facial nerve; 9. vertebral artery; 10. styloid process. Max. Maxillary. (B). Middle fossa floor and cavernous sinus. ;1. sphenoidal sinus; 2. Gasserian ganglion; 3. middle meningeal artery; 4. internal carotid artery (intrapetrous portion); 5. eustachian tube.

sinus. The pterygoid canal can be completely intrasinusal in 7.5 to 13% of the cases and may even be in open communication with the sphenoid sinus when the root of the canal is absent. The anterior portion of the pterygoid canal may also be associated with the ethmoid sinus in up to 7% of cases if the latter is grossly enlarged. Knowledge of those anatomical variations may be useful in the planning of endoscopic surgery and could also explain neural and vascular involvement in inflammatory and neoplastic diseases of the sphenoid and ethmoid sinuses, which occur in some case reports.[5–10]

In the present study, the branching pattern of the MA's pterygopalatine portion was similar to that in other articles.[11–14] From the PMF to the PPF, the MA branched into five arteries. The first ones to branch were the PSAA and the IOA, followed by the DPA, VA, and SPA, which arose in the PPF region. (►**Fig. 3**)

The present data indicate that pterygomaxillary disjunction can be safely performed without lacerating the MA or damaging the neural contents of the PPF. This can be accomplished by placing the osteotome inferiorly on the pterygomaxillary junction (PMJ) and directing it anteriorly and medially. Special care should be taken in not directing the osteotome superiorly. Besides, because the location of the DPA was reported to be an average 24.8 mm apart from the PMJ [28], the osteotome should be directed inferiorly from the zygomaticomaxillary crest as it continues posteriorly when performing the Le Fort I osteotomy. The risk of damaging the MA and its branches will be minimized with this maneuver.

Discussion

Despite its surgical importance, anatomic reports of the pterygopalatine portion of the MA are scarce, because of the difficulty in approaching this region. (►**Fig. 4**) To the best of our knowledge, this issue has been addressed by Montgomery et al., Potter, Pearson et al., and Wentges.[11–14] Turvey and Fonseca[15] described the relationship between the course of the MA in the PPF and the pterygomaxillary suture, a particularly useful finding in oral and maxillofacial surgery. Li et al.[16] also described the localization of the descending

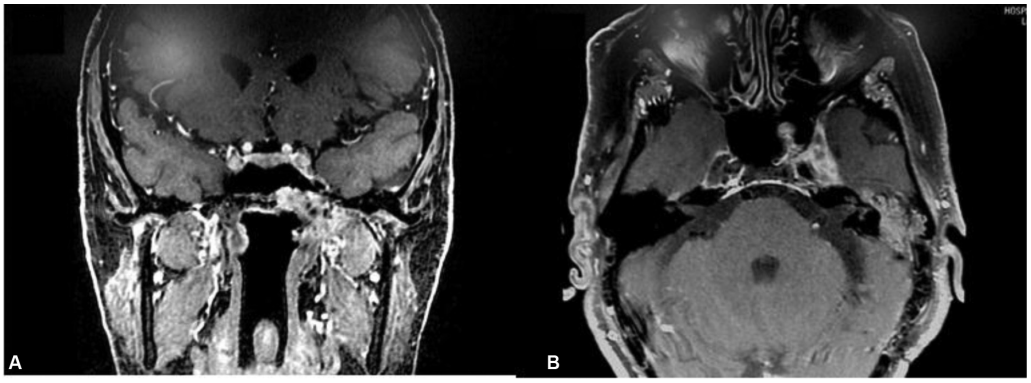

Fig. 4 Clinical example. Computed tomography scan. Endoscopic endonasal biopsy of the tumor in the pterygopalatine fossa reveled squamous cell carcinoma. Treatment was supplemented with radiation therapy.

palatine artery concerning the Le Fort I osteotomy. To separate the pterygomaxillary junction, detailed knowledge of the PPF anatomy is crucial to surgeons. Understanding the course and variations of the MA and its branches in the PPF will help the surgeon prevent injury to this artery when performing midfacial osteotomies. ►**Fig. 4** illustrates a pterygopalatine fossa tumor—the biopsy revealed squamous cell carcinoma.

Clinical Applications

In the setting of a PPF mass lesion, the differential diagnosis includes perineural tumoral extension along the maxillary nerve, schwannomas or neurofibromas arising from this nerve, angiofibromas, hemangiomas, and—on rare instances—ectopic salivary gland tissue. In the investigation of these lesions, computed tomography (CT) provides information regarding the adjacent osseous structures, while magnetic resonance imaging (MRI) helps to characterize the lesion.

The finding of a lesion in the PPF has serious implications, both in treatment and prognosis.[17,18] In the absence of a local destructive neoplasm, it often signifies the presence of perineural spread. The 5-year survival rate of patients presenting with sinonasal malignancies and invasion of the PPF is very low.[19,20] Frequently, perineural spread into the PPF is also an indicator of increased tumor recurrence and reduced survival.[17]

On MRI, the normal PPF appears as a small fatty cleft between the posterior wall of the maxillary sinus, anteriorly, and the pterygoid plates, posteriorly. The fossa is best viewed on T1-weighted images because its contents are surrounded by hyperintense fat. It is usually bilaterally symmetric, containing small flow voids arising from branches of the maxillary artery. The presence of small emissary veins may cause mild enhancement within the PPF after the administration of contrast.[8,17,21]

Angiofibromas and hemangiomas, being vascular tumors, will enhance intensely following contrast administration, and may show abundant flow voids. A nasopharyngeal carcinoma extending into the PPF will replace fat in this location and, if extensive, may erode and enlarge the osseous limits of the fossa. Schwannomas are circumscribed, enhancing tumors that, when large enough, may also erode the osseous margins of the PPF.[22] Encephaloceles and heterotopic brain might have signal characteristics similar to brain tissue on T1, T2, and proton density-weighted MRI.

The various anatomic communications provided by the PPF in the midfacial region explain why the spread of tumors and infections from the head and neck to the cranial base is typical. Many tumors arising from the perineurium spread in all these regions. This explains why the PPF, despite its limited size, has such an importance in cranial base surgery.

Many different methods have been used to produce regional anesthesia of the maxillary branch of the trigeminal nerve.[23] Inserting a needle into the greater palatine canal through the greater palatine foramen and then applying the local anesthetic into the superior part of the PPF will result in profound anesthesia in the distribution of the maxillary nerve.[24] This technique is useful in both maxillofacial surgery and dental treatment, providing a low incidence of complications.[25–27]

Standard Surgical Approach

The standard approach to the PPF usually requires transmaxillary techniques. However, these techniques are limited by facial scars, prolonged recovery time, and possible effects on facial skeletal growth.[2,3,28] Endoscopic approaches are becoming increasingly more popular but have limited utility in far lateral access, increased operative time, and increased difficulty in achieving hemostasis in highly vascular tumors.[2,3,29,30]

Patel et al.[1] described a modified lateral rhinotomy with maxillectomy technique for the treatment of PPF neoplasms. This new approach provides excellent access to most anatomic extensions and is cosmetically superior to the previously described techniques. It allows to preserve the infraorbital nerve and a portion of the maxillary periosteum and facilitates complete resection of PPF lesions.

Endoscopic Approaches

Surgically approaching the PPF is technically tricky, both because of its depth and bony encasement. Traditional open approaches, such as the Caldwell-Luc and lateral rhinotomy, have been primarily replaced by transnasal endoscopic approaches, which are less invasive and greatly minimize the postoperative morbidity associated with older approaches.

Concerning PPF biopsies, the majority of the image-guided cases reported in the literature used a transnasal approach with a medial maxillary antrostomy to gain access to the posterior maxillary wall.[31] The image-guided transoral approach, described by Bleier and Mirza, has been reported to allow wide surgical exposure without the need for endoscopic equipment, also minimizing the potential morbidity of a wide maxillary antrostomy, such as orbital and nasolacrimal duct injury.

Using the endoscopic endonasal route, the PPF can be exposed through its anteromedial surface.[32–37] When using this technique to approach lesions that invade the PPF through the lateral recess of the sphenoid sinus (LRSS), it is more critical to gain wide access to the LRSS, located medially, than to enlarge the surgical field laterally to expose the surface of the PPF completely. The latter maneuver should only be performed during the procedure if the surgeon notices that the lesion expands laterally.

Alfieri et al,[22] using an endoscopic endonasal approach to the pterygopalatine fossa in cadavers, found that the Vidian nerve is an important anatomic landmark. The foramen lacerum was located posteromedially to it, the mandibular nerve was located posterolaterally, the Eustachian tube was located inferomedially, and the PPF was located anteriorly. In all the specimens studied, the pterygopalatine ganglion was found to be of triangular shape, reflecting the disposition of its three main branches: the Vidian nerve superomedially, the branch from the maxillary nerve superolaterally, and the greater and lesser palatine nerves inferiorly. It was also noted

that small branches from the pterygopalatine nerve innervated the nasal and pharyngeal mucosa.

In their study, Alfieri et al.[22] used three different approaches to the PPF. In the middle meatal transpalatine approach, a medial exposure of the PPF can be achieved. The Vidian nerve is found superomedially and can be followed to identify the pterygopalatine ganglion. The middle meatal transantral approach allows a broader exposure and is particularly indicated to approach the lateral PPF. At this location, the infraorbital nerve is easily identified. When the sphenopalatine artery cannot be identified, this approach is a valid alternative. At last, the inferior turbinectomy transantral approach allows the most extensive exposure, so that the infratemporal fossa can be easily approached.

At present, the best available non-endoscopic approaches to the PPF are more invasive when compared with their endoscopic counterparts.[38] The transmaxillary and transpalatal approaches require extensive resection of bony structures and are narrow in the deeper part of the approach. This creates a cone-shaped surgical field, impairing the surgical vision and maneuverability. Endoscopic surgery solves this problem, bringing the light source to the center of the surgical field. An endoscope also allows proper visualization of the surgical field, with the possibility of extreme close-ups and different view angles when using changeable endoscopes.[39–41]

Conclusions

The pterygopalatine fossa is a cone-shaped space that contains multiple key neurovascular structures and its access, either endoscopic or microsurgical, can be challenging. We provide detailed information on the fossa's boundaries, intercommunications with adjacent structures, anatomy of the maxillary artery, and its variations. This anatomical knowledge is discussed in the context of clinical affections and surgical approaches of this specific region, including pterygomaxillary disjunction and skull base tumors.

Conflict of Interests

The authors have no relevant conflict of interests to declare.

References

1 Patel NJ, Ettema SL, Kerschner JE. Maxillary osteoplastic flap technique for the treatment of pediatric pterygopalatine fossa neoplasms. Int J Pediatr Otorhinolaryngol 2006;70(02):295–301. Doi: 10.1016/j.ijporl.2005.06.024

2 Scholtz AW, Appenroth E, Kammen-Jolly K, Scholtz LU, Thumfart WF. Juvenile nasopharyngeal angiofibroma: management and therapy. Laryngoscope 2001;111(4 Pt 1):681–687. Doi: 10.1097/00005537-200104000-00022

3 Mann WJ, Jecker P, Amedee RG. Juvenile angiofibromas: changing surgical concept over the last 20 years. Laryngoscope 2004;114 (02):291–293. Doi: 10.1097/00005537-200402000-00020

4 Choi J, Park H-S. The clinical anatomy of the maxillary artery in the pterygopalatine fossa. J Oral Maxillofac Surg 2003;61(01):72–78. Doi: 10.1053/joms.2003.50012

5 Kim HS, Kim DI, Chung IH. High-resolution CT of the pterygopalatine fossa and its communications. Neuroradiology 1996;38 (Suppl 1):S120–S126. Doi: 10.1007/BF02278138

6 Pandolfo I, Gaeta M, Blandino A, Longo M. The radiology of the pterygoid canal: normal and pathologic findings. AJNR Am J Neuroradiol 1987;8(03):479–483

7 Meloni F, Mini R, Rovasio S, Stomeo F, Teatini GP. Anatomic variations of surgical importance in ethmoid labyrinth and sphenoid sinus. A study of radiological anatomy. Surg Radiol Anat 1992;14(01):65–70. Doi: 10.1007/BF01628046

8 Chong VFH, Fan Y-F. Pterygopalatine fossa and maxillary nerve infiltration in nasopharyngeal carcinoma. Head Neck 1997;19 (02):121–125. Doi: 10.1002/(SICI)1097-0347(199703)19:2<121: AID-HED6>3.0.CO;2-6

9 Mazziotti S, Gaeta M, Blandino A, Vinci S, Pandolfo I. Perineural spread in a case of sinonasal sarcoidosis: case report. AJNR Am J Neuroradiol 2001;22(06):1207–1208

10 Lawson W, Reino AJ. Isolated sphenoid sinus disease: an analysis of 132 cases. Laryngoscope 1997;107(12 Pt 1):1590–1595. Doi: 10.1097/00005537-199712000-00003

11 Montgomery WW, Katz R, Gamble JF. Anatomy and surgery of the pterygomaxillary fossa. Ann Otol Rhinol Laryngol 1970;79(03): 606–618. Doi: 10.1177/000348947007900326

12 Potter GD. The pterygopalatine fossa and canal. Am J Roentgenol Radium Ther Nucl Med 1969;107(03):520–525. Doi: 10.2214/ajr.107.3.520

13 Pearson BW, MacKenzie RG, Goodman WS. The anatomical basis of transantral ligation of the maxillary artery in severe epistaxis. Laryngoscope 1969;79(05):969–984. Doi: 10.1288/00005537-196905000-00014

14 Wentges RT. Surgical anatomy of the pterygopalatine fossa. J Laryngol Otol 1975;89(01):35–45. Doi: 10.1017/S0022215100080051

15 Turvey TA, Fonseca RJ. The anatomy of the internal maxillary artery in the pterygopalatine fossa: its relationship to maxillary surgery. J Oral Surg 1980;38(02):92–95http://www.ncbi.nlm.nih.gov/pubmed/6928026

16 Li KK, Meara JG, Alexander A Jr. Location of the descending palatine artery in relation to the Le Fort I osteotomy. J Oral Maxillofac Surg 1996;54(07):822–825, discussion 826–827. Doi: 10.1016/S0278-2391(96)90528-5

17 Ginsberg LE. Imaging of perineural tumor spread in head and neck cancer. Semin Ultrasound CT MR 1999;20(03):175–186. Doi: 10.1016/S0887-2171(99)90018-5

18 Curtin HD, Williams R, Johnson J. CT of perineural tumor extension: pterygopalatine fossa. AJR Am J Roentgenol 1985;144(01): 163–169. Doi: 10.2214/ajr.144.1.163

19 Goepfert H, Dichtel WJ, Medina JE, Lindberg RD, Luna MD. Perineural invasion in squamous cell skin carcinoma of the head and neck. Am J Surg 1984;148(04):542–547. Doi: 10.1016/0002-9610(84)90385-4

20 Gullane PJ, Conley J. Carcinoma of the maxillary sinus. A correlation of the clinical course with orbital involvement, pterygoid erosion or pterygopalatine invasion and cervical metastases. J Otolaryngol 1983;12(03):141–145http://www.ncbi.nlm.nih.gov/pubmed/6308278

21 Chong VF, Fan YF, Khoo JB, Lim TA. Comparing computed tomographic and magnetic resonance imaging visualisation of the pterygopalatine fossa in nasopharyngeal carcinoma. Ann Acad Med Singapore 1995;24(03):436–441http://www.ncbi.nlm.nih.gov/pubmed/7574428

22 Alfieri A, Jho H-D, Schettino R, Tschabitscher M. Endoscopic endonasal approach to the pterygopalatine fossa: anatomic study. Neurosurgery 2003;52(02):374–378, discussion 378–380. Doi: 10.1227/01.NEU.0000044562.73763.00

23 Poore TE, Carney MT. Maxillary nerve block: a useful technique. J Oral Surg 1973;31(10):749–755http://www.ncbi.nlm.nih.gov/pubmed/4516663

24 Loetscher CA, Melton DC, Walton RE. Injection regimen for anesthesia of the maxillary first molar. J Am Dent Assoc 1988; 117(02):337–340. Doi: 10.1016/S0002-8177(88)72020-6
25 Sved AM, Wong JD, Donkor P, et al. Complications associated with maxillary nerve block anaesthesia via the greater palatine canal. Aust Dent J 1992;37(05):340–345. Doi: 10.1111/j.1834-7819.1992.tb00758.x
26 Sweet WH. Trigeminal injection with radiographic control: technic and results. J Am Med Assoc 1950;142(06):392–396, illust. Doi: 10.1001/jama.1950.02910240010003
27 Nish IA, Pynn BR, Holmes HI, Young ER. Maxillary nerve block: a case report and review of the intraoral technique. J Can Dent Assoc 1995; 61(04):305–310http://www.ncbi.nlm.nih.gov/pubmed/7736334
28 Tewfik TL, Tan AK, al Noury K, et al. Juvenile nasopharyngeal angiofibroma. J Otolaryngol 1999;28(03):145–151http://www.ncbi.nlm.nih.gov/pubmed/10410346
29 Roger G, Tran Ba Huy P, Froehlich P, et al. Exclusively endoscopic removal of juvenile nasopharyngeal angiofibroma: trends and limits. Arch Otolaryngol Head Neck Surg 2002;128(08):928–935. Doi: 10.1001/archotol.128.8.928
30 Nicolai P, Berlucchi M, Tomenzoli D, et al. Endoscopic surgery for juvenile angiofibroma: when and how. Laryngoscope 2003;113 (05):775–782. Doi: 10.1097/00005537-200305000-00003
31 Aronsohn MS, Stringer SP, Brown HM. Utility of image guided surgery in the diagnosis of pterygopalatine fossa lesions. Laryngoscope 2004;114(03):424–427. Doi: 10.1097/00005537-200403000-00007
32 Alfieri A, Jho H-D. Endoscopic endonasal approaches to the cavernous sinus: surgical approaches. Neurosurgery 2001;49(02):354–360, discussion 360–362. Doi: 10.1097/00006123-200108000-00017
33 Al-Nashar IS, Carrau RL, Herrera A, Snyderman CH. Endoscopic transnasal transpterygopalatine fossa approach to the lateral recess of the sphenoid sinus. Laryngoscope 2004;114(03): 528–532. Doi: 10.1097/00005537-200403000-00026
34 Başak S, Karaman CZ, Akdilli A, Mutlu C, Odabaşi O, Erpek G. Evaluation of some important anatomical variations and dangerous areas of the paranasal sinuses by CT for safer endonasal surgery. Rhinology 1998;36(04):162–167http://www.ncbi.nlm.nih.gov/pubmed/9923058
35 Cheung DK, Attia EL, Kirkpatrick DA, Marcarian B, Wright B. An anatomic and CT scan study of the lateral wall of the sphenoid sinus as related to the transnasal transethmoid endoscopic approach. J Otolaryngol 1993;22(02):63–68http://www.ncbi.nlm.nih.gov/pubmed/8515518
36 Mutlu C, Unlu HH, Goktan C, Tarhan S, Egrilmez M. Radiologic anatomy of the sphenoid sinus for intranasal surgery. Rhinology 2001;39(03):128–132http://www.ncbi.nlm.nih.gov/pubmed/11721501
37 Sethi DS, Stanley RE, Pillay PK. Endoscopic anatomy of the sphenoid sinus and sella turcica. J Laryngol Otol 1995;109(10): 951–955. Doi: 10.1017/S0022215100131743
38 Pasquini E, Sciarretta V, Farneti G, Ippolito A, Mazzatenta D, Frank G. Endoscopic endonasal approach for the treatment of benign schwannoma of the sinonasal tract and pterygopalatine fossa. Am J Rhinol 2002;16(02):113–118
39 Cappabianca P, Cavallo LM, de Divitiis E. Endoscopic endonasal transsphenoidal surgery. Neurosurgery 2004;55(04):933–940, discussion 940–941. Doi: 10.1227/01.NEU.0000137330.02549.0D
40 Cappabianca P, de Divitiis E. Endoscopy and transsphenoidal surgery. Neurosurgery 2004;54(05):1043–1048, 1048–1050. Doi: 10.1227/01.NEU.0000119325.14116.9C
41 Elwany S, Elsaeid I, Thabet H. Endoscopic anatomy of the sphenoid sinus. J Laryngol Otol 1999;113(02):122–126. Doi: 10.1017/S0022215100143361

Internal Neurolysis (Nerve Combing) for Trigeminal Neuralgia without Neurovascular Compression

Neurólise interna (nerve combing) para neuralgia do trigêmeo sem compressão neurovascular

Marco Gonzales-Portillo[1] Luis Adrián Huamán[2]

[1] Instituto Neurociencias de Lima, Universidad Peruana Cayetano Heredia, Lima, Perú
[2] Servicio de Neurocirugía, Hospital Nacional Dos de Mayo, Lima, Perú

Address for correspondence Marco Gonzales-Portillo, MD, Instituto Neurociencias de Lima, Del Pinar 198, Surco. 15038, Lima, Perú (e-mail: marcogps@outlook.com).

Arq Bras Neurocir 2021;40(1):59–70.

Abstract

Objective The aim of the present study was to describe and evaluate the initial and the long-term clinical outcome of internal neurolysis (IN) for trigeminal neuralgia (TN) without neurovascular compression (NVC).

Methods A total of 170 patients diagnosed with TN were treated by posterior fossa exploration, during the period between April 2012 and October 2019. The patients were divided into two groups: Group A (50 patients) was treated by IN and Group B (120 patients) received microvascular decompression (MVD). Surgical outcomes and post-operative complications were compared between the two groups. Pain intensity was assessed by the Barrow Neurological Institute (BNI) pain intensity score and BNI facial numbness score. Pain recurrence was statistically evaluated with Kaplan-Meier analysis.

Results Pain was completely relieved in 44 patients (88%) who underwent IN (group A); 3 (6%) experienced occasional pain but did not require medication (BNI 2). In group B, 113 (94%) experienced immediate pain relief after MVD. The median duration of follow-ups was 4 years (6 months to 7.5 years). In Group A, there was a meantime recurrence of 27 months in 3 patients (6%). The recurrence in Group B was of 5.8% during the follow-up period. There were no statistically significant differences in the surgical outcomes between the two groups. All patients with IN experienced some degree of numbness, 88% of the cases resolved in 6 months, on average.

Conclusion Internal neurolysis is an effective, safe and durable treatment option for trigeminal neuralgia when NVC is absent.

Keywords
- internal neurolysis
- nerve combing
- trigeminal neuralgia
- root entry zone
- neurovascular compression
- microvascular decompression

Resumo

Objetivo O propósito do presente estudo foi descrever e avaliar o resultado clínico inicial e a longo prazo da neurólise interna (IN, na sigla em inglês) para neuralgia do trigêmeo (TN, na sigla em inglês) sem compressão neurovascular (NVC, na sigla em inglês).

received
August 1, 2020
accepted
September 25, 2020
published online
January 18, 2021

DOI https://doi.org/10.1055/s-0040-1721334.
ISSN 0103-5355.

Thieme Revinter Publicações Ltda., Rua do Matoso 170, Rio de Janeiro, RJ, CEP 20270-135, Brazil

Métodos. Um total de 170 pacientes diagnosticados com TN foram tratados pela exploração da fossa posterior, durante o período entre abril de 2012 e outubro de 2019. Os pacientes foram divididos em dois grupos: o grupo A foi tratado com IN (50 pacientes) e o grupo B recebeu descompressão microvascular (DMV) (120 pacientes). Resultados cirúrgicos e complicações pós-operatórias foram comparados entre os dois grupos. A intensidade da dor foi avaliada pelo escore de intensidade de dor do Barrow Neurological Institute (BNI, na sigla em inglês) e pelo escore de dormência facial do BNI. A recorrência da dor foi avaliada estatisticamente com a análise de Kaplan-Meier.

Resultados A dor foi completamente aliviada em 44 pacientes (88%) submetidos a IN (grupo A); em 3 (6%) houve dor ocasional, mas não necessitaram de medicação (BNI 2). No grupo B, 113 (94%) experimentaram alívio imediato da dor após DMV. A duração média do acompanhamento foi de 4 anos (6 meses a 7,5 anos). No grupo A, houve recorrência em três pacientes (6%). O tempo médio de recorrência foi de 27 meses. A recorrência no grupo B foi de 5,8% nesse período de acompanhamento. Não houve diferenças estatisticamente significativas nos resultados cirúrgicos entre os dois grupos. Todos os pacientes com IN experimentaram algum grau de dormência, em 88% dos casos, resolvidos em 6 meses, em média.

Conclusões A IN é uma opção de tratamento atraente, eficaz, segura e durável para a neuralgia do trigêmeo quando a NVC está ausente.

Palavras-chave
- neurólise interna
- nerve combing
- neuralgia do trigêmeo
- zona de entrada da raiz
- compressão neurovascular
- descompressão microvascular

Introduction

Vascular arterial contacts with the dorsal root of the trigeminal nerve were first described in 1929, by Dandy.[1] These findings were characterized in subsequent communications.[2,3] In his 1934 publication, "Concerning the cause of trigeminal neuralgia," Dandy describes the total or subtotal division of the trigeminal root in 215 cases.[3] Through a lateral suboccipital craniectomy without the aid of illumination and magnification afforded by an operating microscope, Dandy was able to identify compression on the trigeminal nerve root by a superior cerebellar artery (SCA) loop, in 66 cases (30.7%); compression by a branch of the superior petrosal vein in 30 (14%), and a dolichoectatic basilar artery in 6 (2.7%), for a total of 102 cases (47%).[3–5]

Dandy postulated that the vascular compression of the trigeminal roots was a major cause of tic douloureux.[3,6] However, vascular transposition was not used by Dandy to attempt to relieve the pain; rather, selective section of the trigeminal nerves was performed.

In 1959, Gardner et al. reported a series of 100 patients in whom an extradural subtemporal approach was used to manipulate and free up the sensory root of the trigeminal nerve from its dural sleeve. Exploration of the trigeminal nerve through the posterior fossa, without magnification, was performed in two patients with recurrence. In one patient, an arterial loop was found lying against the nerve at the pons. Pain was completely relieved by separating the vessel from the nerve with a piece of Gelfoam. The second patient was relieved of pain following removal of a large meningioma compressing the trigeminal nerve. It was concluded that the critical part of the operation appeared to be a neurolysis or manipulation of the sensory root of the trigeminal nerve at the point where it crosses the apex of the petrous bone. Gentle manipulation of the sensory root could be done through a middle or a posterior fossa approach. "The cause of trigeminal neuralgia, therefore, presumably lies in the sensory root."[7]

In 1962, Gardner published "Concerning the mechanism of trigeminal neuralgia and hemifacial spasm." He reported a series of suboccipital approaches that followed a failed middle fossa procedure in 18 cases for trigeminal neuralgia (TN) from 1955 to 1961. Although in the era that predated neurosurgical use of the operative microscope, he found an artery loop that compressed and encircled the nerve in 6 cases.[8] There was no mention of the treatment those 6 patients received. Rand reported in 1981 a personal communication with Gardner, where he was informed that the treatment of TN involved either removing the offending lesion such as a tumor, or performing a vascular decompression by dissecting the arterial compressing loop away from the trigeminal root, and placing Gelfoam in between at the level of the pons.[9]

Jannetta, in 1967, still a neurosurgical resident at the time, participated in a workshop titled "Structural Mechanisms of Trigeminal Neuralgia."[10] Reporting five patients with TN, he operated using a binocular dissecting microscope following exposure of the nerve through the transtentorial subtemporal approach to the cerebellopontine angle. He found that the trigeminal nerve was mildly to severely distorted and compressed by one or more small tortuous arteries that appeared to be branches of the SCA. In four out of five patients, he was able to free the artery from the fine to dense arachnoidal membranes, allowing the vessel to assume a new position away from the nerve. He performed a partial to total section of the portio major in all cases. Jannetta hypothesized that it was possible that this minor arterial distortion of the trigeminal nerve at the pons may be a contributing factor in TN. "This possible definitive procedure, namely, release of the artery without nerve section, is planned in a future series of patients."[10]

Table 1 Incidence of neurovascular compression

Authors	Patients	With Vascular Conflict (%)	No vascular Conflict (%)
Van Loveren et al.[17] 1982	50	82	18
Piatt et al.[18] 1984	103	76.7	23.3
Zorman et al.[19] 1984	118	76.3	23.7
Benderson et al.[20] 1989	243	87.7	12.3
Klun[21] 1992	215	80.5	19.5
Baechli et al.[22] 2007	40	87.5	12.5
Leal et al.[23] 2010	100	91	9
Revuelta et al.[24] 2013	271	83.8	16.2
Ko et al.[25] 2015	156	82.7	17.3
Hitchon et al.[26] 2019	69	87	13
Yang et al.[27] 2019	298	88.6	11.4

In a 1974 letter published in JAMA, Jannetta described his 8-year experience with 150 cases of tic douloureux. He reported having found compression-distortion of the nerves with resultant pain control after vascular decompression.[11] The approach used was not described. This was followed by complete manuscripts published in 1976 and 1977.[12,13]

Jannetta became the first neurosurgeon to explore the cranial nerves within the posterior fossa by using an operating microscope, modifying Dandýs original suboccipital approach and developing a set of microneurosurgical instruments. Therefore, the idea that TN was a neurovascular compression was revived, and the treatment of this problem by microvascular decompression (MVD) was developed.

In spite of some initial controversy, today MVD represents the best and the most widely used surgical treatment for TN, because it offers the best long-term cure rates and preserves facial sensation.[14–16]

Neurovascular compression (NVC) of the trigeminal nerve has been identified in most cases of TN; however, the absence of NVC in TN is also common and has been described in the literature in 9 to 23.7% of the cases (►**Table 1**).[17–27] Many surgical modalities are appropriate for MVD candidates who exhibit no NVC on magnetic resonance imaging (MRI), such as percutaneous balloon compression, radiofrequency thermocoagulation, glicerol rhizolysis, and radiosurgical techniques.

In the case of negative microsurgical suboccipital retrosigmoid exploration of the trigeminal root, the intraoperative management options have not been established. Surgical strategies include internal neurolysis (IN), trigeminal root compression (TRC) and partial sensory rhizotomy (PSR).

Internal neurolysis, also referred to as "nerve combing" or "neurocombing", is a procedure in which all or portions of the trigeminal nerve are divided longitudinally along its fibers between the pons and the porus trigeminus.[28,29] The objective of the present study is to evaluate the efficacy of IN in patients with TN without NVC and evaluate the long-term outcome.

Materials and Methods

This is an observational prospective cohort study, based on the prospective observation of 184 patients diagnosed with TN (TN Type 1). The patients were treated by posterior fossa exploration, during the period between April 2012 and October 2019.

Sixteen of the patients were excluded from the present study due to the diagnosis of a cerebellopontine angle tumor during the preoperative evaluation, using magnetic resonance imaging (MRI) of the brain. Data was obtained from hospital records and patient interviews.

Patients included in the cohort study were diagnosed with TN (TN type 1), characterized by paroxysmal and lancinating pain in the distribution area of the trigeminal nerve branches. These patients experienced unilateral, recurrent, stereotyped attacks, generally provoked by stimulated trigger points, including facial movements and changes in temperature.

Indications for surgery included insufficient pain relief with drug treatment and or unacceptable medication side effects. Surgical procedures involved MVD and percutaneous procedures (balloon compression and radiofrequency thermocoagulation).

General physical and neurological examinations were clinically performed to evaluate the patients. In addition, brain MRI, in combination with three high-resolution sequences (T2-weighted 3D, 3D TOF-MRA, and 3D T1-Gad) with fine cuts in the trigeminal nerves, were used for detection of possible neurovascular contact. Routine presurgical examinations were performed.

A surgical treatment algorithm was used for patients with TN (►**Fig. 1**). The advantages and disadvantages of the different surgical treatment options were explained to the patients, and they decided according to their preference. Only those who chose MVD were included in the present study.

The 170 patients with trigeminal neuralgia were divided into two groups. The first group, Group A, consisted of 50 patients who were treated with internal neurolysis (IN). Group B was made up of 120 patients treated with MVD (4 patients treated with MVD and IN). Each group had one patient who underwent two procedures at different times for bilateral trigeminal neuralgia, which was considered to be a separate case for the purposes of analysis. Only one patient (2%) in Group A had a previous surgery. This patient had undergone two percutaneous balloon surgeries without adequate response in pain management. The follow-up period was from 6 months to 7.5 years (average 4 years). In patients with recurrence, the time at which the recurrence occurred was considered a follow-up endpoint.

The Barrow Neurological Institute (BNI) pain intensity score and facial numbness score table was used in the postoperative evaluation (►**Table 2**). The grade of NVC was established on a scale from I to III. In grade I, the vessel was in contact with the root without any visible indentation at the root. In grade II, there was root displacement and/or distortion, and in grade III there was marked indentation in the root. The absence of contact or compression in the root was recorded as grade 0.

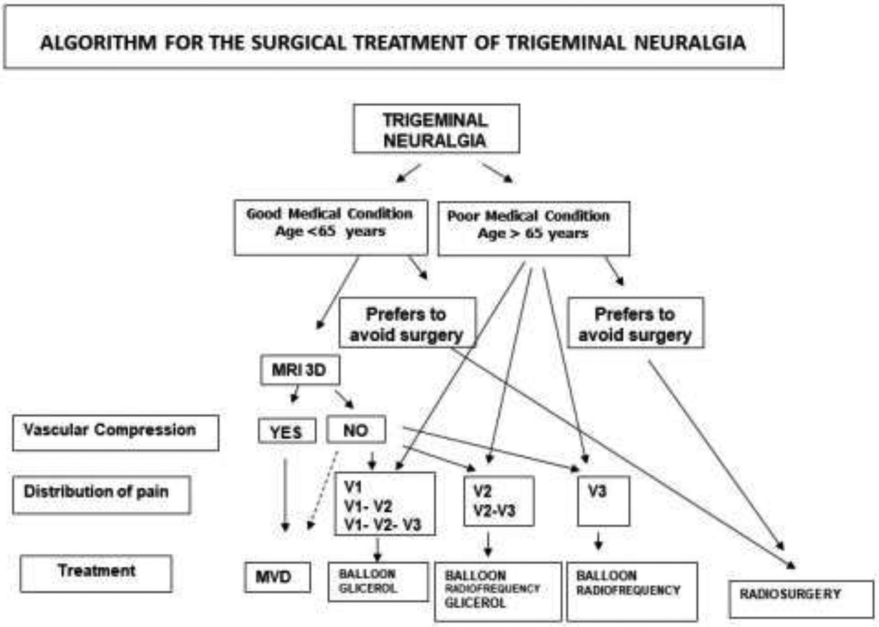

Fig. 1 Algorithm of surgical treatment for trigeminal neuralgia.

Table 2 Barrow Neurological Institute (BNI) pain intensity score and facial numbness score

(P) Evaluation of pain relief by the BNI pain intensity score	
1	No pain, no medication
2	Occasional pain, not requiring medication
3	Some pain, adequately controlled with medication
4	Some pain, not adequately controlled with medication
5	Severe pain / no pain relief
(N) Evaluation of numbness by the BNI facial numbness score	
1	No facial numbness
2	Mild facial numbness, not bothersome
3	Facial numbness, somewhat bothersome
4	Facial numbness, very bothersome

Statistical Analysis

Epidemiological data, clinical history, operative findings, and clinical results were analyzed.

The data was stored on a Microsoft Excel (Microsoft Corporation, Redmond, WA, USA) spreadsheet. The mean, standard deviation (SD), minimum and maximum values were used to summarize the quantitative variables. To summarize the qualitative variables, frequency tables (simple and crossed) were used, expressing the final results in absolute and relative frequency. Ratio comparison test and Kaplan-Meier curves were calculated to determine the ratio of patients who responded to the operation. All hypothesis tests were performed considering a type I error (α) equal to 0.05. Statistical analysis was performed by the R version 4.0.2 statistical software (R Foundation, Vienna, Austria).

Surgical Procedure

The patients were placed in supine or in lateral decubitus position with the affected side upward, the ear positioned parallel to the floor, and the chin flexed. A linear 3.5 cm incision was made behind the ear, starting at the top of the pinna and extending to the mastoid tip within the hairline, between $\sim$ 4 and 5 cm.

The burr hole was made in the asterion, and a 3×3 cm retrosigmoid craniotomy is performed using a high-speed drill and Kerrison Rongeurs to expose the borders of the transverse sinus, the sigmoid sinus, and their intersection. Any exposed mastoid air cells were carefully waxed. The dura was opened in a rectangular fashion along the inferior border of the transverse sinus with the base toward the sigmoid sinus. The dural edges were elevated with sutures extended over the craniotomy dressings. Under direct microscopic visualization, gentle traction of the cerebellum took place with an aspirator and bipolar, protected by cottonoids. Meticulous arachnoid dissection was made and cerebral spinal fluid (CSF) was aspirated.

The superior petrosal vein and its main branches were dissected free from the surrounding arachnoid membranes and preserved as much as possible. The entire length of the trigeminal nerve from the pons to the Meckel cave was carefully explored even if a definite vessel was located. Conflicting vessels were dissected and separated from the nerve, a teflon felt was implanted between them. Particular attention was made to prevent a "neo-compression" between the prosthetic material and the nerve root.

When a vascular compression was not found; veins with simple contact or thickness arachnoid adhesions affected branches of the trigeminal nerve, according to preoperative pain location and intraoperative findings, were longitudinally divided along its fibers, using a Rothon microdisector, into 3 to 4 bundles from the root entry point (REP) to the porus

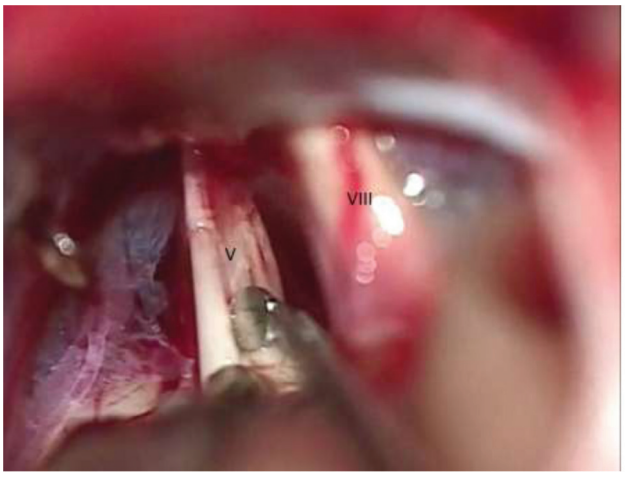

A

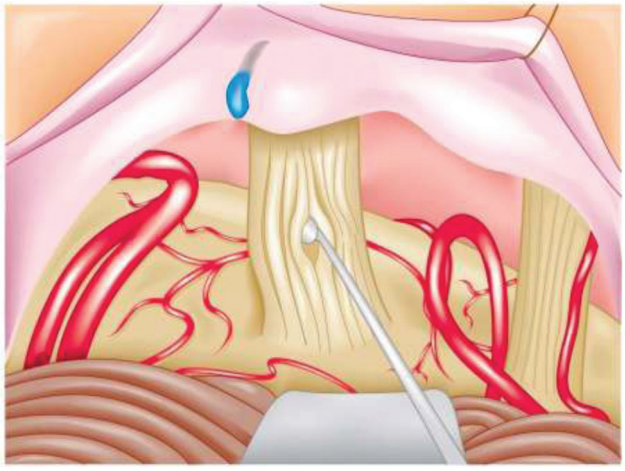

B

Fig. 2 Internal neurolysis (IN) for trigeminal neuralgia without neurovascular compression. (**A**) IN procedure with longitudinal division of the trigeminal nerve using a microdissector. (**B**) An anatomical drawing of the IN procedure.

trigeminus (►**Fig. 2**). Finally, compression of the root at the root entry zone (REZ) with bipolar forceps for 10 seconds took place. The dura was closed, filling the craniotomy defect with autogenous bone. Closure of muscle, soft tissue, and skin was performed in layers in a standard fashion.

Results

In the present study, 50 internal neurolysis procedures were performed in patients with TN during the period between April 2012 and October 2019. Of these patients, 40 were female (80%), the age ranged from 25 to 75 years old (mean of 49 years old).

The age distribution according to gender was unimodal (►**Fig. 3**). The most affected side of the face was the right (68%), the most affected branches being the combination V2, V3 (50%). These clinical and demographic characteristics are shown in ►**Table 3** and ►**Table 4**. The degree of NVC severity is shown in ►**Table 5**. In this series, we found 42 cases (24.7%) with absence of neurovascular conflict.

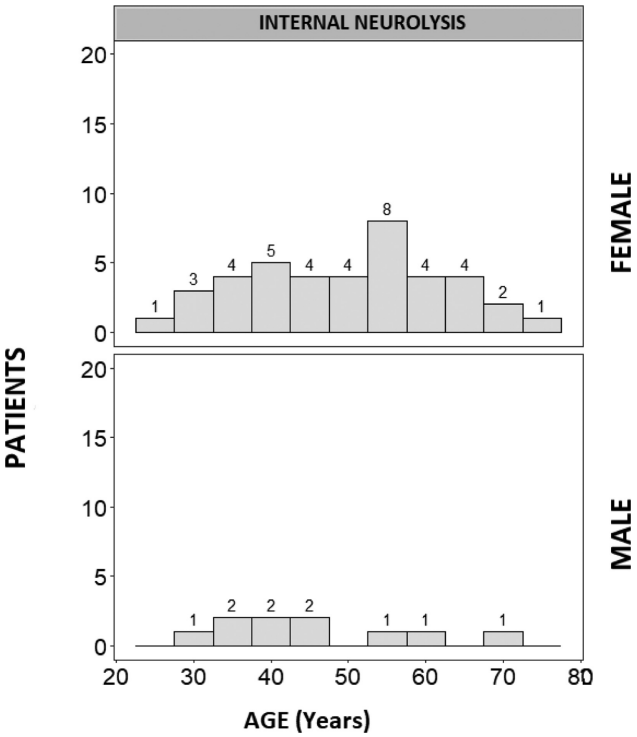

Fig. 3 The Hartigans Dip Test for Unimodality indicates that the age distribution according to gender was unimodal, female ($p = 0.227$) and male ($p = 0.220$).

Table 3 Demographic and clinical information of the two groups

FEATURE	GROUP A ($n = 50$)	GROUP B ($n = 120$)
AGE (years old)	49 (25–75)	50.8 (23–76)
SIDE (Right/Left)	34/16	87/33
GENDER (Female /Male)	40/10	79/41
DISTRIBUTION OF PAIN		
V1	0	0
V2	6 (12%)	13 (10.8%)
V3	9 (18%)	27 (22.5%)
V1,V2	2 (4%)	10 (8.3%)
V2,V3	25 (50%)	51 (42.5%)
V1,V2,V3	8 (16%)	19 (15.8%)

Group A: Patients without vascular compression, Group B: Patients with vascular compression.

Surgical findings in Group A included 42 patients (84%) with no neurovascular conflicts found. Although no neurovascular conflicts were detected, there was presence of arachnoid thickening in 11 patients. The remaining 8 patients (16%) presented with a vein with simple contact (grade 1) to the trigeminal root; 2 of those patients also presented thickened arachnoid adhesions.

In Group B, 116 patients (96.7%) with distortion/displacement (grade II) or indentation (grade III) were surgically treated with MVD; while 4 patients (3.3%) with touching or less severe compression (grade I) underwent an MVD in combination with an IN (►**Table 5**).

Table 4 Distribution of patients with internal neurolysis according to age

AGE (years old)	Patients	%
≤ 30	4	8
31–40	9	18
41–50	12	24
51–60	15	30
61–70	8	16
71–80	2	4
TOTAL	50	100

Table 5 Distribution of patients according to the grade of severity of neurovascular contact

GRADE	Group A ($n = 50$)	Group B ($n = 120$)	TOTAL ($n = 170$)
0	42 (84%)	0	42 (24.7%)
I	8 (16%)	4 (3.3%)*	12 (7%)
II	0	99 (82.5%)	99 (58.2%)
III	0	17 (14.2%)	17 (10%)

Group A: Internal neurolysis, Group B: Microvascular decompression.
*MVD and internal neurolysis were performed.

During the manipulation of the trigeminal nerve, and while IN was performed; some patients experienced bradicardia and arrhythmias that reversed spontaneously. None of these cases reported recurrent bradicardia or arrhythmias requiring any additional treatment.

In the postoperative period, 44 patients (88%) who underwent IN surgical treatment were pain free without any medication, 3 (6%) experienced occasional pain, but did not require medication. Mild facial numbness not bothersome to the patient was presented in 88% of the cases, which resolved in 6 months, on average. (►**Table 6**). In Group B, 94.2% of the patients who underwent MVD were pain-free, and 16 patients (13.3%) experienced some grade of facial numbness, 4 of them having been treated with DMV and IN surgeries.

Table 6 Surgical results after surgery using BNI pain intensity score and facial numbness score

SURGICAL RESULTS	GROUP A ($n = 50$)	GROUP B ($n = 120$)
(P) Pain intensity score		
1	44 (88%)	113(94.2%)
2	3 (6%)	2 (1.7%)
3	0	1 (0.8%)
4	0	1 (0.8%)
5	3 (6%)	3 (2.5%)
(N) Facial numbness score		
1	0	104 (86.7%)
2	44 (88%)	11 (9.2%)
3	4 (8%)	5 (4.1%)
4	2 (4%)	0

Group A: Internal neurolysis, Group B: Microvascular decompression.

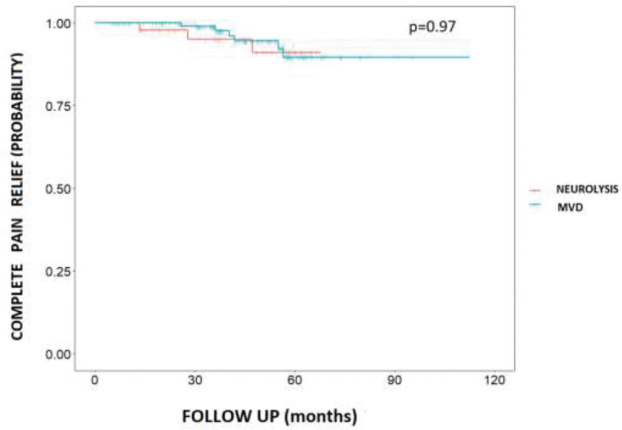

Fig. 4 Kaplan-Meier curves showed that the mean pain-free time was 84.9 (standard error: 2.82) months for neurolysis. For microvascular decompression, the mean was 85.4 (standard error: 1.86) months. The logarithm of range test ("logrank") shows that the treatments did not show differences throughout the study time with respect to complete pain relief ($p = 0.97$).

Recurrence was defined as transition from pain-free or occasional pain without medication (BNI I and II) to severe pain or requirement of medication (BNI III–V).

The follow-up period was from 6 months to 7.5 years (average 4 years). In group A there was recurrence in 3 patients (6%), one of them with intraoperative finding of a small vein that contacted the trigeminal root, occurred at 12 months; a second patient in whom only adhesions were found recurred at 25 months, and a third patient in whom no neurovascular compression was identified, it recurred at 44 months. Two out of three patients underwent successful balloon compression, and the third continued with medication.

The mean time of recurrence was 27 months. Kaplan-Meier analysis showed that the mean pain-free time was 84.9 (standard error: 2.82) months (►**Fig. 4**).

The recurrence in Group B was of 5.8% in this follow-up period.

The logarithm of range test ("Logrank") shows that the treatments in the 2 groups did not show differences over time in the study with respect to complete pain relief ($p = 0.97$).

Complications are summarized in ►**Table 7**. Cerebellar infarction occurred in one patient who also had hemifacial

Table 7 Postoperative complications

COMPLICATION	Group A	Group B
Cerebellar infarction	1 (2%)	
Transient hearing loss	1 (2%)	2 (1.7%)
Meningitis		1 (0.8%)
Transient diplopia		1 (0.8%)
Wound cerebrospinal fluid leak		2 (1.7%)
Nasal cerebrospinal fluid leak		2 (1.7%)

Group A: Internal Neurolysis, Group B: Microvascular decompression.

spasm and had to undergo MVD of the facial nerve during the same procedure. Most of the patients experienced mild transient hearing loss, with resolution in 2 months; the diplopia was caused by paresis of the VI cranial nerve, with complete resolution after 3 months. In cases of nasal CSF leaks, external lumbar drainage was placed for between 5 and 7 days. In 2 cases of wound CSF leaks, placement of new sutures were required, as well as compression and use of acetazolamide. Placement of external lumbar drain was not necessary.

Discussion

Pathophysiology

The leading theory for the pathophysiology of TN is the "ignition" hypothesis proposed by Devor et al in 2002, which proposes three key elements in the genesis of TN: a trigger, an amplifier, and a stop mechanism.[30]

According to the ignition hypothesis, a neurovascular contact is thought to damage the myelin sheath in the trigeminal nerve, which renders the sensory afferents hyperexcitable by means of ectopic pacemaker sites and ephaptic cross-talk and crossed after discharge between axons.[30,31] Anatomical studies confirmed that the root entry zone or transition zone of the trigeminal nerve, where the myelination changes from peripheral Schwann cell myelination to central oligodendrocyte myelination, is a site of demyelination in patients with classical TN with a neurovascular contact.[32,33]

Currently accepted, the decompression of the central myelin alone or decompression of the central-peripheral myelin transitional zone was the mechanism that provided pain relief.

McLaughlin et al., in 1999, postulated that the central myelin of the sensory root of the trigeminal nerve could extend along the entire cisternal segment of this branch. He stated that not only would vascular decompression of the REZ relieve the pain of patients with TN, but also that decompression performed anywhere along the entire length of the nerve (from the pons to entry into the Meckel cave) would be effective.[34]

Sindou et al., in 2002, suggested that NVC can be located not only at the REZ but also all along the root, and because offending vessels can be multiple in the same patient, he strongly advised that the entire trigeminal nerve from the Meckel cave to the pons should be exposed. He proposed that NVC probably does not entirely explain all the pathogenesis of TN. He thought that there might be several other important factors. Sindou concluded, "It is wise to admit that besides peripheral mechanisms, central phenomena probably play an important additional role."[16]

Peker et al., in 2006, reported his study of one hundred trigeminal nerves from 50 cadaver heads that were examined. "The measurements showed that the central myelin occupies only the initial one-fourth of the trigeminal nerve length. If trigeminal neuralgia is caused exclusively by vascular compression of the central myelin, the problem vessel would always have to be located in this region. However, it is well known that pain from trigeminal neuralgia can resolve after vascular decompression at more distal sites. This suggests that the effects of surgical decompression are caused by another mechanism."[32]

Ko, Lee et al. observed that it is increasingly clear that TN occurs and recurs in the absence of NVC,[35] and that NVC of the trigeminal nerve exists in a sizeable population without TN.[36] He suggested that NVC is neither a necessary nor sufficient condition for the development of TN. Nevertheless, NVC does play a role in disease pathogenesis.

It is becoming increasingly understood that the pathophysiology of TN is associated with both trigeminal nerve and brain abnormalities.

Importance of Degree of Neurovascular Compression

Increasingly, the contributions of NVC severity is beginning to be better understood.

Sindou reported a series of 362 patients who underwent MVD. Concerning anatomical factors, neither the type of the compressive vessel nor its location along or around the root was found to be significant. However, the severity of compression was important – the more severe the degree of compression, the better the outcome.[37]

Maarbjerg et al., in 2015, with 3T MRI, evaluated 135 patients with classical trigeminal neuralgia. Neurovascular contact was prevalent both on the symptomatic and asymptomatic side, 89 versus 78%, while severe neurovascular contact (displacement or atrophy of the trigeminal nerve) was highly prevalent on the symptomatic compared with the asymptomatic side (53 versus 13%). Severe neurovascular contact was caused by arteries in 98%.

This concluded that neurovascular contact causing displacement or atrophy of the trigeminal nerve is highly associated with the symptomatic side in classical TN, as opposed to neurovascular contact in general, suggesting that the degree of NVC could thus be important when selecting patients for surgery.[38]

Hughes et al. published in 2019 the significance of degree of NVC in surgery for TN. Seventy-nine patients were studied on a 3-T MRI. Vascular contact was more common on the asymptomatic side (43/79, 54.4%) compared with the symptomatic side (30/79, 38%). Severe NVC (indentation/deformity of the of the trigeminal nerve) was much more commonly identified on the symptomatic side (47/79, 59.5%) compared with the asymptomatic side (7/79, 8.9%). In his study, the only imaging variable that was a statistically significant predictor of being pain-free without medication following MVD was severe NVC. Patients with severe NVC were 6.36 times more likely to be pain-free following MVD when compared with those without severe NVC.[39]

According to various studies published with high resolution MRI, the presence of NVC has a sensitivity of 87% to 97% and a specificity between 50% to 100% for TN.[23,35,39,40]

Recently, it was reported that ultra-high field MRI enabled advanced Diffusion tensor imaging (DTI)-based tractographic reconstruction of the white matter tracts connecting the thalamus and primary somatosensory cortex. Reduced microstructural integrity of thalamic-somatosensory tracts was found ipsilateral to the site of NVC in patients with TN, whereas no differences were observed contralateral to the

site of NVC. These changes implicate a compensatory mechanism for reducing pain sensation, and may provide substantial evidence of secondary white matter disruption at the thalamic-somatosensory level in patients with TN.[41]

Trigeminal Neuralgia without Vascular Compression

The absence of vascular compression over the trigeminal nerve has been described in the literature in 9 to 23.7% of cases (►**Table 1**). In our series of 170 patients, 42 (24.7%) presented no vascular conflict, and in 12 cases (7%), a mild contact (grade I) was found; 8 with venous compression were coagulated and cut and IN was performed. In 4 cases with arterial compression, MVD in combination with IN was performed.

It is likely that the number of TN without neurovascular compression (WONVC) will increase more since it is increasingly recognized that vascular contact (grade I) should not be accepted as vascular compression and additional treatment must done.

In the absence of NVC on imaging, the question arises as to whether recommend a posterior fossa exploration versus percutaneous procedures or radiosurgery.

However, it is challenging for neurosurgeons to deal with cases without visible vascular compression intraoperatively, and there are no well-designed surgical strategies for these patients, which ranged from no manipulation to complete section of the nerve.

In these cases, most neurosurgeons do a meticulous dissection of the arachnoid to expose the entire trigeminal root, followed by a massage and/or a compression with bipolar to the trigeminal nerve or a partial nerve section.

Based on the proposed mechanisms of production of TN related to the compression of the sensitive trigeminal root of the trigeminal nerve in its intracranial route, nondestructive open surgical techniques have historically been directed toward a decompression of the trigeminal nerve at some point in its intracranial trajectory.[42,43]

In 1955, Shelden et al. suggested that the common denominator to all procedures is operative trauma, introducing a new technique such as pressing with a blunt dissector the portio major nerve fibers of the trigeminal nerve surgically exposed through a middle cranial fossa approach, suggesting that the compression of the trigeminal fibers during the operation is the factor that relieves the pain.[44]

Partial sensory rhizotomy (PSR) is a classical alternative technique used in the absence of NVC.

The response rate is reported in 70 to 87% of patients (►**Table 8**), with a recurrence rate of 29% at 5 years of follow-up.[21,45–48] The main disadvantages of this ablative treatment are sensory deficits, which occur in 22 to 100% of patients and can lead to additional complications as dysesthesias, corneal reflex impairment and anesthesia dolorosa. Furthermore, it has been reported that a lesser degree of patient satisfaction is associated with side effects after PSR.[47]

Ishikawa et al., in 2002, speculated a different mechanism other than vascular compression.[49]

They suggested that arachnoid thickening or granulomatous adhesion between the root and surrounding structures can cause a tethering effect to the trigeminal root, which would make pulsatile movement of the root more restricted or desynchronized. This could give the root an abnormally high stretching force, which might promote hyperexcitability of the nerve.

Dissection of thick arachnoid around the root along the whole length reversed the root to be straight and flaccid. This speculative mechanism suggests that it is important to make

Table 8 Partial sensory rhizotomy. Results related to extent of the rhizotomy

Reference	Number of Cases	Pain Relief After Surgery (%)	Median Follow-Up (months)	Extent of Rhizotomy	Corneal Reflex Impairment/ Hypesthesia (%)	Sensory Deficit (%)	Anesthesia dolorosa	Recurrence Rate
Adams et al.[45] J Neurol Neurosurg Psychiatry 1982	54	87.3	54	30–100% of trigeminal Nerve	0	100 Painful dysesthesia 7.4%	1 case (1.8%)	11.8% at 5 years
Bederson et al. J Neurosurg 1989	30 (PSR) 56 (PSR + MVD)	70 (PSR) 80 (PSR + MVD)	61.2	Inferior ½ to ⅔ of pars Major	4.6	dysesthesias 8.1%	2.3%	NA
Klun et al.[21] Neurosurgery 1992	42	86	62.4	1/3 or less of the pars major	0	100	0	Total recurrence rate 49%
Young et al.[46] J Neurosurg 1993	83	48 Excellent 22 Good	72	1/3 to ½ ventrolateral of nerve root (89%) 2/3 of nerve root (11%)	NA	67	NA	17% at 1 year and 2.6% each year thereafter
Zakrzewska et al.[47] Neurosurgery 2005	60	88	68.4	NA	22 “eye problems”	48	NA	28% at 5 years
Terrier et al.[48] 2017	22	86.4	67.3	2/3 ventrolateral of pars Major	0	22.7	9% in hemitongue	14.6% at 1 year 31.5% at 5 years

Abbreviations: MVD, microvascular decompression; NA, not available; PSR, partial sensory rhizotomy.

Table 9 Series of intraoperative trigeminal root manipulations

Reference	N° of cases	Treatment	Pain-free immediatly	Recurrence	Facial numbness
Ishikawa et al.[49] Journal of Clinical Neuroscience 2002	5	Arachnoidal dissection	80%	20% in 15 months	NR
Revuelta et al.[24] World Neurosurgery 2013	44	Intermittent compression on cisternal segment	100%	27.2% in 10 months	61.4% transient
Cheng et al.[51] Acta Neurochir 2015	28	Compression with bipolar forceps for 10 seconds	71.4%	38.4% in 46 months	21.4% transient 14.3% permanent
Guo et al.[68] Journal of Clinical Neuroscience 2018	19	360-degree circumferential arachnoid dissection	100%	10.5% in 2 years	15.8% transient
Urculo et al.[52] Neurocirugia 2020	10	Trigeminal root massage/ intermittent compression	100%	40% in 5 years	NR

Abbreviation: NR, not reported.

the root free along the entire length, especially at its distal portion in cases with no offending vessels.

Revuelta-Gutierrez et al., in 2006 and 2013, proposed their surgical strategy for TN without vascular compression. The surgery consists of meticulous dissection of the arachnoid, exposing the entire trigeminal root, followed by gentle compression with bipolar tips on its cisternal segment.[24,50]

This nerve compression technique has been subsequently followed by other authors.[51,52]

►**Table 9** shows the outcome of a series of intraoperative trigeminal root manipulations.

Internal Neurolysis

Nerve combing is a surgical strategy for trigeminal neuralgia that longitudinally splits branches of the trigeminal nerve using a special fiber knife in accordance with preoperative pain locations and intraoperative findings. This surgical strategy for TN was reported by Li et al. in 1995.[53]

Ashkan et al., in 2004, reported their series of MVD for TN in 80 patients, "When no compressing vessel was identified, the trigeminal nerve was probed longitudinally by use of a microdissector and split into several fascicles. To the best of our knowledge, this is a novel technique and is preferred by the authors to the partial transverse sectioning of the nerve, which is usually associated with facial numbness."[54] About 13 patients were subjected to these techniques, without specific mention of the surgical outcome of these patients

Ma et al., in 2009, described 10 patients without vascular compression who underwent nerve combing and achieved satisfactory long-term relief by 70%. They postulated that traumatizing the nerve and dampening its abnormal activity in the brainstem could perhaps explain nerve combing to relieve pain.[28]

The mechanism by which IN results in pain relief remains unclear. Studies suggest that IN destroys the continuity of axons and decreases the electrical excitability of abnormal afferent trigeminal fibers, permanently degenerating the partial axon tissue and myelin sheath after a period of time.[29,55]

Internal neurolysis may disrupt interconnections between nerve fibers and communication between distributions of the trigeminal nerve prior to entrance into the brainstem.[25] Kline et al. suggested that partial nerve injury and damage to the root of the trigeminal nerve mediated pain relief.[56]

Internal neurolysis resulted in immediate relief of all pain in 80 to 98% of patients (►**Table 10**).

The success rate is durable, with an estimated 72 to 82% pain-free in 5 years.[25,27,29,55,57]

Microvascular decompression has an initial pain relief rate of 79 to 94%,[14–16,39] with a pain-free rate of 72 to 84% at a 5-year follow-up.[47,58–60]

In our series, the two proportion Z-Test showed no statistically significant difference in immediate ($p = 0.289$) and long-term outcomes ($p = 1.000$) between IN and MVD.

All of our patients with IN had some degree of hypoesthesia; in two, the facial numbness was very bothersome in the immediate postoperative period, but they improved afterwards.

In 88% of the cases, sensitivity was fully recovered within 6 months after the operation. Compared with our patients with balloon compression, the degree of numbness is generally much lower in patients with IN at the immediate postoperative. Reported rates of facial numbness after IN range between 60 and 96%.[25,27,28,61–63] Most cases are transient and resolve over weeks to months.

A previous study reported that facial numbness after IN did not negatively impact the quality of life in the majority of cases when the pain was controlled.[62]

One case of anesthesia dolorosa reported in the literature includes a patient with previous MVD for the treatment of TN, who presented with a sensory deficit.[25]

Some studies found that patients with TN without NVC may represent a distinct population of younger, predominantly female patients in their mid-30s with a short symptom duration.[64,65]

In our patients undergoing IN, the difference in the mean age according to gender was not statistically significant ($p = 0.335$). The age distribution of our female patients shows for the IN procedure an almost uniform dispersion

Table 10 Literature series of Internal Neurolysis (nerve combing) for trigeminal neuralgia

Reference	Number of cases	Outcome	Sensory deficit
Ma et al.[28] Clin J Pain 2009	10	Initial pain-free: 80% 70% pain free, recurrence 10% in 3 years	90% transitory numbness 10% permanent numbness
Jie et al.[29] Acta Neurochir 2013	28	82% pain-free, 4% recurrence in 4.3 years	10.5% numbness
Ko et al.[25] JNS 2015	27	Initial pain-free 85%. 72% in 5 years	96% numbness 1 patient (4%) anesthesia dolorosa *
Zhou et al.[57] Braz J Otorhinolatyngol 2016	50	Initial satisfactory relief 92% 82% in 7.5 years Recurrence 10%	16% dysesthesias
Zhao et al.[55] J Craniofacial 2017	15	Initial pain-free 80% 73.3% pain-free in 4 years	13% transitory numbness 7% permanent numbness
Zhang et al.[61] World Neurosurgery 2017	86	Initial pain-free 98% 94% in 1 year	60% transitory numbness at 1 day 4% in 1 year
Liang et al.[62] Ir J Med Sci 2017	37	Initial pain free 94.6% In 3 years 78% pain free Recurrence 21.6%	91,9% transitory facial numbness In 6 months 67.6% facial numbness
Wu et al.[63] Stereotact Funct Neurosurg 2018	27	Initial pain free 92.6%	88.9% facial numbness
Yang et al.[27] Acta Neurol Belg 2019	34	Initial pain-free 88% In 5 years 73% pain-free Recurrence 6%	76% transitory facial numbness
Gonzáles-Portillo et al. 2020	50	Initial pain-free 88% Recurrence 6%	100% facial numbness 88% transitory

*Previous MVD,
with sensory deficit.

throughout the range of 25 to 75 years old; no outstanding peak was observed. The distribution of the patients in the study of Liang et al. was normal and unimodal. The mean age of the patients was 50.19 years old.[62]

The relapse of TN after MVD has been shown without recurrence of compression.[35,66,67]

Internal neurolysis can be an important option in posterior fossa exploration for recurrent or persistent TN symptoms. Zhang et al. reported that, in patients with recurrent or persistent TN symptoms, IN plus MVD significantly improved the success rate of the operation compared with simple redo MVD.[61]

Surgical Description of the Grades of Compression and Location in Microvascular Decompression

We suggest a surgical description for posterior fossa exploration for TN. ►**Table 11**. It has two components: first, the degree of NVC, based in the studies of Sindou[37] and Maarbjerg,[38] and the report of Hughes, who concluded that "The only imaging variable that was a statistically significant predictor of being pain-free without medication following MVD was severe NVC."[39] The second component is the location of the MVD. The locations were divided in thirds based on the study of Peker et al.,[32] who stated that the cisternal segment of the trigeminal nerve ranged from 8 mm to 15 mm long (mean, 12.3 mm; median,11.9 mm). The proportion of the central myelin relative to the length of the cisternal portion of the trigeminal nerve was 25% in 74 specimens and between 26 and 33% in 20 specimens out of 100.

Table 11 Surgical description of microvascular decompression for trigeminal neuralgia

MICROVASCULAR DECOMPRESSION GRADING SYSTEM	
GRADES OF COMPRESSION	
☐ Grade 0	No contact
☐ Grade I	Simple neurovascular contact: without visible alteration of the root
☐ Grade II	Severe neurovascular contact: displacement, distortion, indentation, engrooving or atrophy of the trigeminal nerve.
LOCATION OF NEUROVASCULAR COMPRESSION	
☐ Anterior Third	
☐ Middle Third	
☐ Posterior Third	

In this grading system, veins are graded according to the same scale as arteries.
The cisternal segment extends from the root entry point to the porus trigeminus.
Posterior Third: Defined as the proximal third of the cisternal segment of the nerve closest to the root entry point.

Conclusions

Internal neurolysis has become increasingly used as an adjunct or standalone therapy when a low grade or no NVC is identified intraoperatively, or as a salvage procedure in TN patients who are unresponsive to MVD or have a recurrence of symptoms.

Internal neurolysis is a viable treatment option, providing adequate initial pain relief and long-term efficacy.

Patients treated with IN may experience some degree of facial numbness, which was well tolerated by the patients in the present study. However, further studies are required to explore the exact mechanisms of pain relief.

In the present study, there were no statistically significant differences in the immediate and long-term surgical outcomes between IN and MVD.

Conflict of Interests

The authors have no conflict of interests to declare.

References

1 Dandy WE. An operation for the cure of tic douloureux. Partial section of the sensory root at the pons. Arch Surg 1929; 18:687–734
2 Dandy WE. The treatment of trigeminal neuralgia by the cerebellar route. Ann Surg 1932;96(04):787–795
3 Dandy WE. Concerning the cause of trigeminal neuralgia. Am J Surg 1934;24:447–455
4 Kaufmann AM, Price AV. A history of the Jannetta procedure. J Neurosurg 2019;132(02):639–646
5 Wilkins RH. Trigeminal Neuralgia: Historical Overview, with Emphasis on Surgical Treatment. In: Burchiel KJ(ed). Surgical management of pain. Thieme; 2002:288–301
6 Wilkins RH. Historical perspectives, in Rovit RL, Murali R, Jannetta PJ (eds). Trigeminal Neuralgia Baltimore: Williams & Wilkins; 1990:1–25
7 Gardner WJ, Miklos MV. Response of trigeminal neuralgia to decompression of sensory root; discussion of cause of trigeminal neuralgia. J Am Med Assoc 1959;170(15):1773–1776
8 Gardner WJ. Concerning the mechanism of trigeminal neuralgia and hemifacial spasm. J Neurosurg 1962;19:947–958
9 Rand RW. The Gardner neurovascular decompression operation for trigeminal neuralgia. Acta Neurochir (Wien) 1981;58(3-4):161–166
10 Jannetta PJ. Arterial compression of the trigeminal nerve at the pons in patients with trigeminal neuralgia. 1967. J Neurosurg 2007;107(01):216–219
11 Jannetta PJ. Letter: Tic douloureux and facial spasm. JAMA 1974; 228(13):1637–1638
12 Jannetta PJ. Microsurgical approach to the trigeminal nerve for tic douloureux. In: Krayenbühl H, Maspes PE, Sweet WH(eds). Pain - Its Neurosurgical Management. Part I: Procedures on Primary Afferent Neurons. Basel: Karger; 1976, Vol 7180–200
13 Jannetta PJ. Observations on the etiology of trigeminal neuralgia, hemifacial spasm, acoustic nerve dysfunction and glossopharyngeal neuralgia. Definitive microsurgical treatment and results in 117 patients. Neurochirurgia (Stuttg) 1977;20(05):145–154
14 Barker FG II, Jannetta PJ, Bissonette DJ, Larkins MV, Jho HD. The long-term outcome of microvascular decompression for trigeminal neuralgia. N Engl J Med 1996;334(17):1077–1083
15 Broggi G, Ferroli P, Franzini A, Servello D, Dones I. Microvascular decompression for trigeminal neuralgia: comments on a series of 250 cases, including 10 patients with multiple sclerosis. J Neurol Neurosurg Psychiatry 2000;68(01):59–64
16 Sindou M, Howeidy T, Acevedo G. Anatomical observations during microvascular decompression for idiopathic trigeminal neuralgia (with correlations between topography of pain and site of the neurovascular conflict). Prospective study in a series of 579 patients. Acta Neurochir (Wien) 2002;144(01):1–12, discussion 12–13
17 van Loveren H, Tew JM Jr, Keller JT, Nurre MA. a 10-year experience in the treatment of trigeminal neuralgia. Comparison of percutaneous stereotaxic rhizotomy and posterior fossa exploration. J Neurosurg 1982;57(06):757–764
18 Piatt JH Jr, Wilkins RH. Treatment of tic douloureux and hemifacial spasm by posterior fossa exploration: therapeutic implications of various neurovascular relationships. Neurosurgery 1984; 14(04):462–471
19 Zorman G, Wilson CB. Outcome following microsurgical vascular decompression or partial sensory rhizotomy in 125 cases of trigeminal neuralgia. Neurology 1984;34(10):1362–1365
20 Bederson JB, Wilson CB. Evaluation of microvascular decompression and partial sensory rhizotomy in 252 cases of trigeminal neuralgia. J Neurosurg 1989;71(03):359–367
21 Klun B. Microvascular decompression and partial sensory rhizotomy in the treatment of trigeminal neuralgia: personal experience with 220 patients. Neurosurgery 1992;30(01):49–52
22 Baechli H, Gratzl O. Microvascular decompression in trigeminal neuralgia with no vascular compression. Eur Surg Res 2007;39 (01):51–57
23 Leal PRL, Hermier M, Froment JC, Souza MA, Cristino-Filho G, Sindou M. Preoperative demonstration of the neurovascular compression characteristics with special emphasis on the degree of compression, using high-resolution magnetic resonance imaging: a prospective study, with comparison to surgical findings, in 100 consecutive patients who underwent microvascular decompression for trigeminal neuralgia. Acta Neurochir (Wien) 2010;152(05):817–825
24 Revuelta-Gutierrez R, Martinez-Anda JJ, Coll JB, Campos-Romo A, Perez-Peña N. Efficacy and safety of root compression of trigeminal nerve for trigeminal neuralgia without evidence of vascular compression. World Neurosurg 2013;80(3-4):385–389
25 Ko AL, Ozpinar A, Lee A, Raslan AM, McCartney S, Burchiel KJ. Long-term efficacy and safety of internal neurolysis for trigeminal neuralgia without neurovascular compression. J Neurosurg 2015; 122(05):1048–1057
26 Hitchon PW, Bathla G, Moritani T, Holland MT, Noeller J, Nourski KV. Predictability of vascular conflict by MRI in trigeminal neuralgia. Clin Neurol Neurosurg 2019;182:171–176
27 Yang DB, Wang ZM. The efficacy and safety of nerve combing for trigeminal neuralgia without neurovascular compression. Acta Neurol Belg 2019;119(03):439–444. Doi: 10.1007/s13760-019-01099-2
28 Ma Z, Li M. “Nerve combing” for trigeminal neuralgia without vascular compression: report of 10 cases. Clin J Pain 2009;25(01): 44–47
29 Jie H, Xuanchen Z, Deheng L, et al. The long-term outcome of nerve combing for trigeminal neuralgia. Acta Neurochir (Wien) 2013; 155(09):1703–1708, discussion 1707
30 Devor M, Amir R, Rappaport ZH. Pathophysiology of trigeminal neuralgia: the ignition hypothesis. Clin J Pain 2002;18(01):4–13
31 Rappaport ZH, Devor M. Trigeminal neuralgia: the role of self-sustaining discharge in the trigeminal ganglion. Pain 1994;56 (02):127–138
32 Peker S, Kurtkaya O, Uzün I, Pamir MN. Microanatomy of the central myelin-peripheral myelin transition zone of the trigeminal nerve. Neurosurgery 2006;59(02):354–359, discussion 354–359
33 Rappaport ZH, Govrin-Lippmann R, Devor M. An electron-microscopic analysis of biopsy samples of the trigeminal root taken during microvascular decompressive surgery. Stereotact Funct Neurosurg 1997;68(1-4 Pt 1):182–186

34 McLaughlin MR, Jannetta PJ, Clyde BL, Subach BR, Comey CH, Resnick DK. Microvascular decompression of cranial nerves: lessons learned after 4400 operations. J Neurosurg 1999;90(01):1–8
35 Lee A, McCartney S, Burbidge C, Raslan AM, Burchiel KJ. Trigeminal neuralgia occurs and recurs in the absence of neurovascular compression. J Neurosurg 2014;120(05):1048–1054
36 Miller JP, Acar F, Hamilton BE, Burchiel KJ. Radiographic evaluation of trigeminal neurovascular compression in patients with and without trigeminal neuralgia. J Neurosurg 2009;110(04):627–632
37 Sindou M, Leston J, Decullier E, Chapuis F. Microvascular decompression for primary trigeminal neuralgia: long-term effectiveness and prognostic factors in a series of 362 consecutive patients with clear-cut neurovascular conflicts who underwent pure decompression. J Neurosurg 2007;107(06):1144–1153
38 Maarbjerg S, Wolfram F, Gozalov A, Olesen J, Bendtsen L. Significance of neurovascular contact in classical trigeminal neuralgia. Brain 2015;138(Pt 2):311–319
39 Hughes MA, Jani RH, Fakhran S, et al. Significance of degree of neurovascular compression in surgery for trigeminal neuralgia. J Neurosurg 2019;14:1–6
40 Brînzeu A, Drogba L, Sindou M. Reliability of MRI for predicting characteristics of neurovascular conflicts in trigeminal neuralgia: implications for surgical decision making. J Neurosurg 2018;130 (02):1–11
41 Rutland JW, Huang KH, Gill CM, et al. First application of 7-T ultra-high field diffusion tensor imaging to detect altered microstructure of thalamic-somatosensory anatomy in trigeminal neuralgia. J Neurosurg 2019:1–9. Doi: 10.3171/2019.6.JNS19541
42 Taarnhøj P. Decompression of the trigeminal root and the posterior part of the ganglion as treatment in trigeminal neuralgia; preliminary communication. J Neurosurg 1952;9(03):288–290
43 Taarnhøj P. Decompression of the trigeminal root. J Neurosurg 1954;11(03):299–305
44 Shelden CH, Pudenz RH, Freshwater DB, Crue BL. Compression rather than decompression for trigeminal neuralgia. J Neurosurg 1955;12(02):123–126
45 Adams CB, Kaye AH, Teddy PJ. The treatment of trigeminal neuralgia by posterior fossa microsurgery. J Neurol Neurosurg Psychiatry 1982;45(11):1020–1026
46 Young JN, Wilkins RH. Partial sensory trigeminal rhizotomy at the pons for trigeminal neuralgia. J Neurosurg 1993;79(05):680–687
47 Zakrzewska JM, Lopez BC, Kim SE, Coakham HB. Patient reports of satisfaction after microvascular decompression and partial sensory rhizotomy for trigeminal neuralgia. Neurosurgery 2005;56 (06):1304–1311, discussion 1311–1312
48 Terrier L-M, Amelot A, François P, Destrieux C, Zemmoura I, Velut S. Therapeutic failure in trigeminal neuralgia: from a clarification of trigeminal nerve somatotopy to a targeted partial sensory rhizotomy. World Neurosurg 2018;117:e138–e145
49 Ishikawa M, Nishi S, Aoki T, et al. Operative findings in cases of trigeminal neuralgia without vascular compression: proposal of a different mechanism. J Clin Neurosci 2002;9(02):200–204
50 Revuelta-Gutiérrez R, López-González MA, Soto-Hernández JL. Surgical treatment of trigeminal neuralgia without vascular compression: 20 years of experience. Surg Neurol 2006;66(01): 32–36, discussion 36
51 Cheng J, Lei D, Zhang H, Mao K. Trigeminal root compression for trigeminal neuralgia in patients with no vascular compression. Acta Neurochir (Wien) 2015;157(02):323–327
52 Urculo E, Elua A, Arrazola M, Torres P, Torres S, Undabeitia J. Trigeminal root massage in microsurgical treatment of trigeminal neuralgia patients without arterial compression: When, how and why. Neurocirugia (Astur) 2020;31(02):53–63
53 Li M, Yu GZ, Guan Y, et al. Nerve combing treat for trigeminal neuralgia. Zhonghua Er Bi Yan Hou Za Zhi (China) 1995;30:377
54 Ashkan K, Marsh H. Microvascular decompression for trigeminal neuralgia in the elderly: a review of the safety and efficacy. Neurosurgery 2004;55(04):840–848, discussion 848–850
55 Zhao H, Zhang X, Tang D, Li S. Nerve combing for trigeminal neuralgia without vascular compression. J Craniofac Surg 2017;28 (01):e15–e16
56 Kline D, Hudson A. Acute injuries of peripheral nerve. In: JR Y(ed) . Neurological surgery. WB Saunders: Philadelpia; 1996:2103–2181
57 Zhou X, Liu Y, Yue Z, Luan D, Zhang H, Han J. Comparison of nerve combing and percutaneous radiofrequency thermocoagulation in the treatment for idiopathic trigeminal neuralgia. Rev Bras Otorrinolaringol (Engl Ed) 2016;82(05):574–579
58 Pollock BE, Stien KJ. Posterior fossa exploration for trigeminal neuralgia patients older than 70 years of age. Neurosurgery 2011; 69(06):1255–1259, discussion 1259–1260
59 Zhang H, Lei D, You C, Mao BY, Wu B, Fang Y. The long-term outcome predictors of pure microvascular decompression for primary trigeminal neuralgia. World Neurosurg 2013;79(5-6):756–762
60 Wei Y, Pu C, Li N, Cai Y, Shang H, Zhao W. Long-Term Therapeutic Effect of Microvascular Decompression for Trigeminal Neuralgia: Kaplan-Meier Analysis in a Consecutive Series of 425 Patients. Turk Neurosurg 2018;28(01):88–93
61 Zhang X, Xu L, Zhao H, et al. Long-Term Efficacy of Nerve Combing for Patients with Trigeminal Neuralgia and Failed Prior Microvascular Decompression. World Neurosurg 2017;108:711–715
62 Liang X, Dong X, Zhao S, Ying X, Du Y, Yu W. A retrospective study of neurocombing for the treatment of trigeminal neuralgia without neurovascular compression. Ir J Med Sci 2017;186(04): 1033–1039. Doi: 10.1007/s11845-016-1547-y
63 Wu M, Jiang X, Niu C, Fu X. Outcome of internal neurolysis for trigeminal neuralgia without neurovascular compression and its relationship with intraoperative trigeminocardiac reflex. Stereotact Funct Neurosurg 2018;96(05):305–310. Doi: 10.1159/000493547
64 Ko AL, Lee A, Raslan AM, Ozpinar A, McCartney S, Burchiel KJ. Trigeminal neuralgia without neurovascular compression presents earlier than trigeminal neuralgia with neurovascular compression. J Neurosurg 2015;123(06):1519–1527
65 Magown P, Ko AL, Burchiel KJ. The spectrum of trigeminal neuralgia without neurovascular compression. Neurosurgery 2019;85(03):E553–E559
66 Rath SA, Klein HJ, Richter H-P. Findings and long-term results of subsequent operations after failed microvascular decompression for trigeminal neuralgia. Neurosurgery 1996;39(05):933–938, discussion 938–940
67 Bakker NA, Van Dijk JM, Immenga S, Wagemakers M, Metzemaekers JD. Repeat microvascular decompression for recurrent idiopathic trigeminal neuralgia. J Neurosurg 2014;121(04):936–939
68 Guo H, Song G, Wang X, Bao Y. Surgical treatment of trigeminal neuralgia with no neurovascular compression: A retrospective study and literature review. J Clin Neurosci 2018;58:42–48. Doi: 10.1016/j.jocn.2018.10.066

Cervical Cordotomy in Terminal Cancer: Pain Relieving in Oncological Treatment

Cordotomia cervical em câncer terminal: Alívio da dor em tratamento oncológico

Maria Clara Cardoso Seba[1] Henrique Nicola Santo Antonio Bernardo[1] Natally Marques Santiago Sarturi[2] Thania Gonzalez Rossi[2] Newton Maciel de Oliveira[3] Paulo Henrique Pires de Aguiar[1,2,4]

[1] Faculdade de Medicina do ABC, Santo André, SP, Brazil
[2] Divison of Neurosurgery, Hospital Santa Paula, São Paulo, SP, Brazil
[3] Department of Histology, Pontifícia Universidade Católica de São Paulo, Sorocaba, SP, Brazil
[4] Pontifícia Universidade Católica de São Paulo, Sorocaba, Brazil

Address for correspondence Maria Clara Cardoso Seba, BA, Rua José Abdo Marão, 3418, Votuporanga, São Paulo, 15501-031, Brazil (e-mail: mariaclaracseba@hotmail.com).

Arq Bras Neurocir 2021;40(1):71–77.

Abstract

Cordotomy consists in the discontinuation of the lateral spinothalamic tract (LST) in the anterolateral quadrant of the spinal cord, which aims to reduce the transference of nociceptive information in the dorsal horn of the gray matter of the spinal cord to the somatosensory cortex. The main indication is for patients with terminal cancer that have a low life expectancy. It improves the quality of life by relieving pain. The results are promising and the pain relief rate varies between 69 and 100%. Generally speaking, the complications are mostly temporary and not remarkable.

Keywords
- cordotomy
- intractable pain
- neoplasms
- spinothalamic tracts

Resumo

A cordotomia consiste na descontinuação do trato espinotalâmico lateral (LST, na sigla em inglês) no quadrante anterolateral da medula espinhal, que visa reduzir a transferência de informações nociceptivas no corno dorsal da substância cinzenta da medula espinhal para o córtex somatossensorial. A principal indicação é para pacientes com câncer terminal com baixa expectativa de vida. Esse procedimento melhora a qualidade de vida, aliviando a dor. Os resultados são promissores e a taxa de alívio da dor varia entre 69 e 100%. De um modo geral, as complicações são principalmente temporárias e não são notáveis.

Palavras-chave
- cordotomia
- dor intratável
- neoplasias
- tratos espinotalâmicos

Introduction

Cordotomy is an interventional pain procedure used in the management of intractable cancer pain. It consists in the discontinuation of the anterolateral quadrant of the spinal cord; this interruption normally occurs in the axon of the second neuron of this pathway. It is based on physiological principles of interruption of the lateral spinothalamic tract (LST) by means of thermocoagulation, to reduce the transfer of nociceptive information coming from the gray matter of the

received
April 15, 2020
accepted
August 5, 2020
published online
November 26, 2020

DOI https://doi.org/10.1055/s-0040-1718425.
ISSN 0103-5355.

Thieme Revinter Publicações Ltda., Rua do Matoso 170, Rio de Janeiro, RJ, CEP 20270-135, Brazil

posterior horn of the spinal cord that would follow in direction to the primary sensitive cortex (postcentral gyrus).[1–6]

The surgery is performed with the patient awake and sedated, under the effect of local anestesia.[3,7] Moreover, the structure that serves as a spatial parameter for the procedure site is the dented ligament of the spinal cord; the electrode must be introduced before this structure, usually between C1 and C2.[8] Over time, cordotomy has become one of the most effective and reliable pain-relieving operation; nevertheless, it is essentially an ideal condition. The percentage of pain relief until death was high. Despite that, complications were common.

Methods

The PubMed database was used for bibliographic survey using *cordotomy* and *terminal cancer* as keywords. With the articles found in PubMed, a selection was made according to pain relief and complications. Therefore, articles that did not have enough information to calculate results and complications were excluded, so the articles that contained the information mentioned above were included. From this selection, the articles were organized in ►**Table 1** and the results were obtained.

In addition, analyzing the literature, important historical data were selected to assemble a timeline (►**Fig. 1**). ►**Fig. 2** is a cross-sectional histological section provided by one of the authors added to a schematic drawing of the spinal cord to indicate the place of the procedure.

Historical Remarks

To organize and illustrate the important facts of the history of cordotomy, ►**Fig. 1** was made.

Surgical Approach

The techniques to apply cordotomy can be divided into two major groups, which are open and percutaneous cordotomies. Each one has both advantages and disadvantages and the main points will be covered in this topic.

First, percutaneous cordotomy is a powerful technique for cancer pain management.[24] It remains the most frequently utilized neurosurgical procedure for the relief of cancer pain, particularly for unilateral pain confined to the trunk or lower limbs.[25] This type of cordotomy uses radiofrequency lesions to destroy this portion of the cord. In addition, it is done with local anesthesia usually performed at the C1-C2 vertebrae level and prior to producing the destructive lesion. A stimulation can be done to assure that the painful area will be covered by the cordotomy.[26] The best indication is unilateral pain below the shoulder in a patient with a life expectancy of < 1 year. The major contraindication to a percutaneous cordotomy is pre-existing respiratory dysfunction on the opposite side to the one to be rendered analgesic.[24]

Second, open cordotomy involves cervical or thoracic laminectomy and near complete section of the anterolateral quadrant of the spinal cord, usually under general anesthesia.[25,26] This procedure is usually reserved for patients who are unable to lie on the supine position or are not cooperative enough to undergo a percutaneous procedure.[27]

When these two techniques are brought up for comparison, it is notable that percutaneous techniques are less invasive, but open techniques remain viable options because some surgeons lack the expertise and equipment required for percutaneous procedures.[28] Although the results from open cordotomy are favorable, percutaneous cordotomy is less invasive and the results are comparable.[26] Therefore, percutaneous cordotomy has largely supplanted the open surgical approach, which is commonly employed even when predicted life expectancy is limited to weeks or days. The percutaneous technique is simple, safe, and effective, and is accompanied by minimal surgical and psychological trauma.[25]

Finally, these two great divisions of the technique are used; however, the percutaneous technique is the most used today. As for the other topics, cordotomy will be discussed without dividing into these two subgroups discussed above.

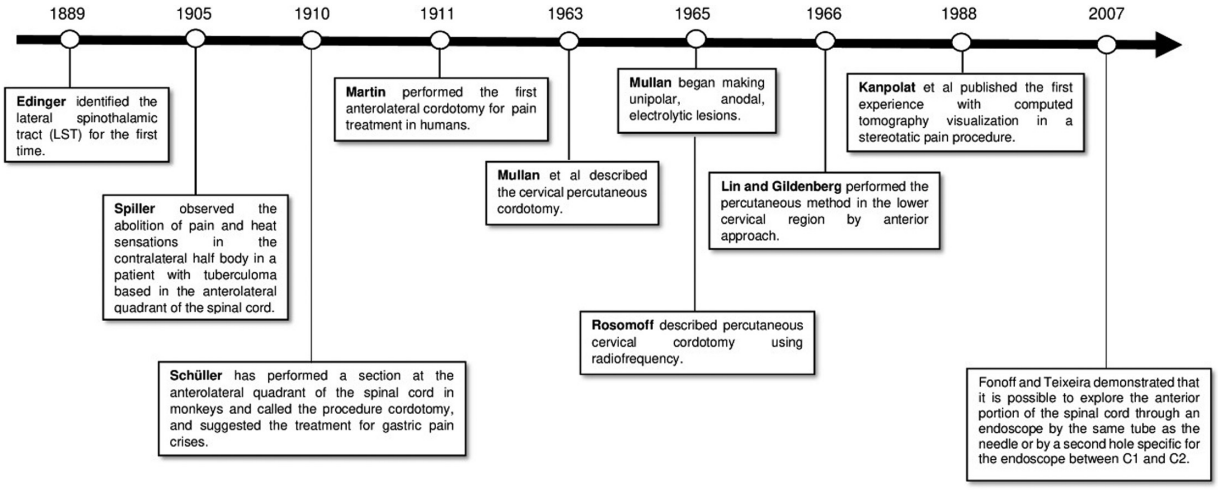

Fig. 1 Time line to illustrate the historical facts of cordotomy.[9–23]

Results

The results were obtained separately from the update table and from a previously performed article review.

First, when the table is analyzed, there is a significant improvement in pain, postoperative, in 89.1% (409/459) of the patients. In addition, in most cases, a significant reduction in opioid dose was observed after the cordotomy.[9,29–36]

On second analysis, in the literature review, similar results are achieved: cordotomy results in immediate pain relief in 69 to 100% of the cases.[6] The surgery cannot be completed in ~ 5.4% of the cases. However, there was a reduction in the health improvement from 92.2% to 62.5% during the follow-up period, which was ~ 5 weeks.[23]

When it comes to microendoscopy-guided percutaneous cordotomy, Fonoff exposes that the double channel approach presents better results than the single channel approach. The double channel approach provides a better vision and consequently a better security for the execution of the procedure.[9]

Several authors emphasize that cordotomy performed unilaterally presents better results than those performed bilaterally.

Moreover, to achieve satisfactory pain relief, it may be necessary to repeat percutaneous high cervical cordotomy, which is well tolerated by the severely distressed and poor-risk patient. Another detail that was commented is that if cordotomy is performed in children, the surgeon should not expect the same result as that of the one made in adults.[30]

According to Kanpolat, in 2009, patients may be evaluated in four groups postoperatively: Grade I – no pain; Grade II – partial satisfactory pain relief; Grade III – partial non satisfactory pain relief; Grade IV – no change in pain. Grades I and

Table 1 Table of articles for updating the literature review from the procedure of cordotomy[9,24–31]

NAME	AUTHORS	YEAR	N	RESULTS	COMPLICATIONS
Open thoracic anterolateral cordotomy for pain relief in children: report of 2 cases	Dora Steel; Matthew A. Kirkman; Dominic N. P. Thompson; Kristian Aquilina	2017	2 children	In the first child, bilateral open cordotomy at the T-5 and T-6 levels, via T3–6 laminoplasty, was performed. Postoperatively, there was immediate and significant improvement in his pain. His intrathecal analgesic treatment was successfully discontinued. He remained at home, where he died 12 weeks after the anterolateral cordotomy. In the second child, a left anterolateral cordotomy at T-5. There was an immediate reduction in his gluteal pain. On review 36 months postoperatively, analgesic medications have been discontinued.	No complications reported. This procedure is an effective treatment option for adults with intractable pain, but it has seldom been attempted in children.
Microendoscopy-guided percutaneous cordotomy for intractable pain: case series of 24 patients	Erich Talamoni Fonoff; William Omar Contreras Lopez; Ywzhe Sifuentes Almeida de Oliveira; Manoel Jacobsen Teixeira	2015	24	The microendoscopic double-channel approach provided real-time visualization of the target in 91% of the cases. The other 9% of procedures were performed by the single-channel technique. Significant analgesia was achieved in > 90% of the cases.	Two patients presented with significant ataxia lasting for a few weeks until total recovery.
The Dying Art of Percutaneous Cordotomy in Canada	Christopher R. Honey; Wendy Yeomans; Albert Isaacs; C. Michael Honey	2014	4	The pain relief following cordotomy is immediate and care must be taken to ensure appropriate opioid reduction.	In this very small cohort of patients, there has been no major complications. Patient 1: signs of depression. Patient 3: symptoms of continued bleeding. Patient 4: neck pain persisted.
Percutaneous cervical cordotomy for the menagement of pain from cancer: a prospective review of 45 cases	Emma Bain; Heino Hugel; Manohar Sharma	2013	45	Thirty-two patients experienced significant pain relief on day 2. At 28 days, 21 from 34 patients followed-up reported maximal and average pain scores of zero. At 2 days postprocedure, 43 patients stated it was worthwhile; at 28 days this number had decreased to 39.	Adverse events after percutaneous cervical cordotomy include respiratory insufficiency, headache, increase in pain, mirror pain, dysaesthesia and motor weakness. Headache was the most common problem observed in 20 patients. Mirror pain was reported in 13 patients.

(*Continued*)

Table 1 (*Continued*)

NAME	AUTHORS	YEAR	N	RESULTS	COMPLICATIONS
					These complications didn't affect the patients' good recovery.
Percutaneous cervical cordotomy for non-cancer pain in a patient with terminal esophageal carcinoma	Jacquelyn Lewin; Heino Hugel; Manohar L. Sharma	2012	1	The pain relief was immediate and the patient died 11 months later with no recurrence of the right-sided pain.	The patient had a transient occipital headache following the procedure.
Computed tomography-guided percutaneous cordotomy for intractable pain in malignancy	Yucel Kanpolat; Hasan Caglar Ugur; Murat Ayten; Atilla Halil Elhan	2009	207	Immediately postoperatively: 92.5% patients reported pain relief. The initial success rate was slightly higher in the malignancy group. In the cancer group, selective cordotomy was achieved in 83%. In 12 cases, bilateral selective percutaneous cordotomy was successfully applied.	The complications in the conventional cordotomy are greater than in the computed tomography-guided percutaneous cordotomy. In the computed tomography-guided percutaneous cordotomy, the creation of large lesions with thick electrodes is a complication. Complications: 5 cases (2.4%) with temporary slight motor paralysis; 5 cases with temporary ataxia. In bilateral cordotomy, there were 3 cases (1.4%) of temporary hypotension and 2 cases (0.9%) of temporary urinary retention. The only permanent complication postcordotomy in our series was dysesthesia, seen in 4 cases (1.9%). Most complications after this procedure are attributable to bilateral lesioning of the anteromedial portion of the spinal cord. There were no complications in the cases with intractable benign pain.
The present role of percutaneous cervical cordotomy for the treatment of cancer pain	Ben J. P. Crul; Laura M. Blok; Jan van Egmond; Robert T. M. van Dongen	2005	43	Immediately postoperatively: 41/43 (95%) patients reported a good result. During follow-up until death: 34/40 patients obtained good pain control. In 4 patients, percutaneous cervical cordotomy had to be repeated; 3 satisfied patients and one was treated with continuous intrathecal infusion with morphine and bupivacaine. In 3 patients, percutaneous cervical cordotomy was performed bilaterally with good results and no complications.	Only one patient had a permanent partial loss of muscle power in his ipsilateral lower limb. Common complications: mirror pain (7); muscle weakness (2); short lasting apnea (1); bladder dysfunction (1). These complications are mostly transient.
Percutaneous cervical cordotomy for the control of pain in patients with pleural mesothelioma	M B Jackson; D pounder; C price; A W Matthews; E Neville	1999	53	It can be inferred that most of the patients in this series (83%) had a significant reduction in pain, and 20 of 52 (38%) were able to stop opioid medication completely.	Two patients experienced troublesome dysesthesia following cervical cordotomy and persistent motor weakness was noted in four.
Safety of Unilateral and Bilateral Percutaneous Cervical Cordotomy in 80 Terminally ill Cancer Patients	Michael Sanders; Wouter Zuurmond	1995	Percutaneous cervical cordotomy: 62 Bilateral percutaneous cervical cordotomy: 18 Total: 80	Percutaneous cervical cordotomy: 54 satisfied patients; 6 partial and 2 no pain relief. Bilateral percutaneous cervical cordotomy: 9 satisfied patients; 6 partial and 3 no pain relief.	The permanent complications in percutaneous cervical cordotomy were urinary retention in 6.5%, hemiparesis in 8.1%, mirror-image pain in 6.5% and Horneŕs syndrome in 100%. The permanents complications in Bilateral percutaneous cervical cordotomy were urinary retention in 11.1%, hemiparesis in 11.1%, mirror-image pain in 5.6% and Horneŕs syndrome in 100%.

II were accepted as successful outcome and grades III and IV as unsuccessful. The results were that 92% reported initial pain relief (grades I-II).[37]

In summary, cordotomy is an immediate analgesic effect that can promptly and significantly improve quality of life and reduce opioid use in this patient population.

►**Table 1** shows these results according to each article researched.[9,29–36]

Discussion

Functional Anatomical Basis for the Procedure

Cordotomy is a procedure performed in the LST, which is located in the anterolateral portion of the spinal cord as seen in ►**Fig. 2**. This tract carries information from pain and temperature stimuli.[4–6]

The stimulus is captured by nociceptors and thermoceptors present in the skin. This will be transmitted to the first order neuron that penetrates the spinal cord through the posterior root of a spinal nerve, which is characterized by having its body located in the sensory ganglion of that nerve. When it penetrates the spinal cord through the posterior horn, a synapse is performed with the second neuron in the gray matter of the spinal cord itself, it is crisscrossed at the height of the spinal cord through the anterior white commissure. The fibers of the second neuron go to the brainstem, where they will follow as spinal lemniscus to the thalamus. There, these axons synapse with the third neuron and this will reach the somatosensory cortex located in the postcentral gyrus of the parietal lobe.

Segmentation of fibers provides the opportunity for selective cordotomy, given that anteromedial lesions denervate the contralateral arm and upper chest region, whereas posterolateral lesions denervate the sacral and lumbar area.[4]

According to ►**Fig. 2**, cordotomy, which consists of the interruption of the LST at the medullary level, is performed by introducing a needle into the subarachnoid space between C1 and C2, anteriorly to the dentate ligament.

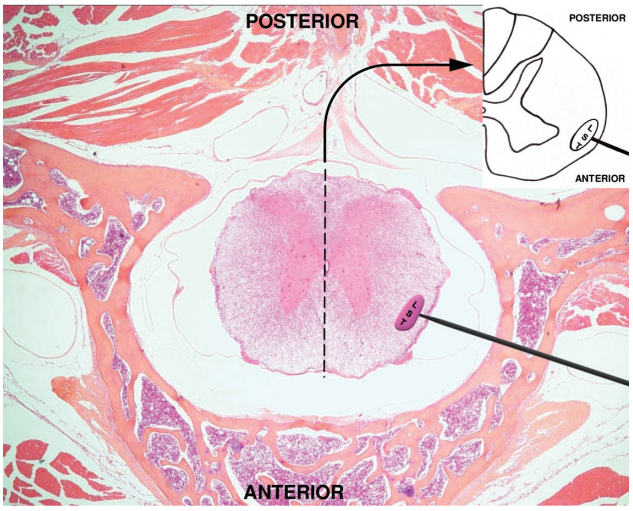

Fig. 2 Cross-sectional histological section and schematic drawing of the spinal cord aiming to represent the local of cordotomy.

Indications and Contraindications

Cordotomy can be performed safely and effectively with careful patient selection, preparation and scrupulous attention to detail. The procedure is indicated for pain treatment originated by cancer that unilaterally attacks distal segments, that is, candidates for cordotomy are patients with lateral somatic cancer pain and compression of the plexus, roots or nerves.[23,38]

The best candidates for computed tomography (CT)-guided percutaneous cordotomy are those with unilateral localized pain. In bilateral cordotomy, the best candidates are patients with intractable pain localized in the lower part of the body.[8,15,37]

In the literature, cases report that cordotomy can be made in patients that passed a long period in morphine therapy and have short life expectancy.[39–41] Other authors support that the procedure presents better results in patients with life expectancy > 6 months and have not initiated morphine therapy.[42]

Patients with severe pulmonary dysfunction (partial oxygen saturation < 80%) are not suitable candidates for cordotomy. Also, patients with neck metastasis could be a contraindication for needle puncture if the compromised area is involved.[42–44]

Complications

As observed in ►**Table 1**, the most frequent complications are: Horner's syndrome, urinary retention, arterial hypotension, sensorial ataxy, hypotony and ipsilateral hemiparesis. Right after the surgery, headache is common. Other complications are less frequent, such as: motor and sphincter or sexual deficits (< 10% of the cases), respiratory disfunction and sleep apnea (Ondinès Syndrome). It is observed that this last one is most common when the procedure is performed bilaterally or when analgesia is related to the brachial dermatomes. Most of the complications are temporary and not remarkable.[9,29–36]

Lahuerta observed that complications usually occurred when the lesion of cordotomy had an extension of > 20% of the spinal cord.[45]

When the procedure is performed unilaterally, occasionally contralateral pain from the original pain (mirror pain) can be manifested. When analyzed, bilateral cordotomy is not recommended for upper trunk pain because of the risk of respiratory complications.[44] Furthermore, cervical cordotomy should be avoided in patients with respiratory insufficiency.

Finally, to avoid other complications, the surgeon must remember not to stop morphine therapy suddenly. The conduct is to reduce their dosages progressively and discontinue morphine use over time.

Conclusions

Cordotomy provides excellent pain relief in the contralateral hemibody. Cordotomy should be included in the patient care pathway of those suffering from severe unilateral pain that has failed to respond to medication therapy. However, cordotomy performed in children is not as suitable and safe as in adults.

Cordotomy consists in the discontinuation of the spinothalamic tract in the anterolateral quadrant of the spinal cord.

The outcome is promising, achieving immediate pain relief in 69 to 100% of the cases, and mainly temporary or not remarkable complications.

Edinger, Spiller and Rosomoff are some of the researches committed with the development of cordotomy. Also, the work of Fonoff with microendoscopy provides the possibility of a safer procedure.

In summary, cordotomy has become the most effective and reliable pain-relieving operation. Operative intervention is indicated in the management of pain when the cause defies more direct treatment and when the severity of the pain justifies the operative procedure.

Note

Work developed at: Faculdade de Medicina do ABC (FMABC).

Conflict of Interests

The authors have no conflict of interests to declare.

References

1 Hyndman OR. Possibility of differential section of the spinothalamic tract: a clinical and histologic study. Arch Surg 1939;38(06):1036

2 Kanpolat Y, Akyar S, Cağlar S. Diametral measurements of the upper spinal cord for stereotactic pain procedures: experimental and clinical study. Surg Neurol 1995;43(05):478–482, discussion 482–483

3 Lorenz R. Methods of Percutaneous Spino-Thalamic Tract Section. In: Krayenbühl H, Brihaye J, Loew F, Logue V, Mingrino S, Pertuiset B, et al., editors. Advances and Technical Standards in Neurosurgery [Internet]. Vienna: Springer Vienna; 1976:123–45. Available at: https://doi.org/10.1007/978-3-7091-7080-9_6

4 Taren JA, Davis R, Crosby EC. Target physiologic corroboration in stereotaxic cervical cordotomy. J Neurosurg 1969;30(05):569–584

5 Walker AE. The spinothalamic tract in man. Arch Neurol Psychiatry 1940;43(02):284–298

6 White JC, Sweet WH. Pain and the neurosurgeon; a forty-year experience, Springfield, Ill.: C.C. Thomas. 1969

7 Sindou M, Jeanmonod D, Mertens P. Ablative neurosurgical procedures for the treatment of chronic pain. Neurophysiol Clin 1990;20(05):399–423

8 Kanpolat Y, Caglar S, Akyar S, Temiz C. CT-Guided Pain Procedures for Intractable Pain in Malignancy. In: Meyerson BA, Ostertag C, editors. Advances in Stereotactic and Functional Neurosurgery 11. Vienna: Springer Vienna; 1995:88–91

9 Fonoff ET, Lopez WOC, de Oliveira YSA, Teixeira MJ. Microendoscopy-guided percutaneous cordotomy for intractable pain: case series of 24 patients. J Neurosurg 2016;124(02):389–396

10 Clarke E, O'Malley CD. Function of the spinal Cord. In: Clarke E, O'Malley CD, editors. The human brain and spinal cord. San Francisco: Norman Publishing; 1996:291–322

11 Fonoff ET, de Oliveira YSA, Lopez WOC, Alho EJL, Lara NA, Teixeira MJ. Endoscopic-guided percutaneous radiofrequency cordotomy. J Neurosurg 2010;113(03):524–527

12 Kanpolat Y, Deda H, Akyar S, Bilgiç S. CT-guided Percutaneous Cordotomy. In: Broggi G, Burzaco J, Hitchcock ER, Meyerson BA, Tóth S, editors. Advances in Stereotactic and Functional Neurosurgery 8. Vienna: Springer Vienna; 1989:67–8

13 Kanpolat Y, Akyar S, Cağlar S, Unlü A, Bilgiç S. CT-guided percutaneous selective cordotomy. Acta Neurochir (Wien) 1993;123(1-2):92–96

14 Kanpolat Y, Savas A, Çaglar S, Temiz C, Akyar S. Computerized tomography-guided percutaneous bilateral selective cordotomy. Neurosurg Focus 1997;2(01):e4

15 Kanpolat Y. Cordotomy for pain. In Handbook of stereotactic and functional neurosurgery Schulder (ed) Marcel & Dekker. New York: Basel; 2003:459–472

16 Lin PM, Gildenberg PL, Polakoff PP. An anterior approach to percutaneous lower cervical cordotomy. J Neurosurg 1966;25 (05):553–560

17 Mullan S, Harper PV, Hekmatpanah J, Torres H, Dobbin G. Percutaneous Interruption of Spinal-Pain Tracts by Means of a Strontium 90 Needle. J Neurosurg 1963;20(11):931–939

18 Mullan S, Hekmatpanah J, Dobben G, Beckman F. Percutaneous, intramedullary cordotomy utilizing the unipolar anodal electrolytic lesion. J Neurosurg 1965;22(06):548–553

19 Rosomoff HL, Brown CJ, Sheptak P. Percutaneous radiofrequency cervical cordotomy: technique. J Neurosurg 1965;23(06):639–644

20 Schüller A. Über operative Durchtrennung der Rückenmarksstrange (Chordotomie). Wien Med Woch 1910;60:2292–2295

21 Spiller WG. The location within spinal cord of the fibers of temperature and pain sensations. J Nerv Ment Dis 1905; 32:318–320

22 Spiller WG, Martin E. The treatment of persistent pain of organic origin in the lower part of body by division of the anterolateral column of spinal cord. JAMA 1912;58:1489–1490

23 Teixeira MJ. Various functional procedures for pain. In: Gildenberg PL, Tasker RR (eds) . Textbook of stereotatic and functional neurosurgery, Part II, facial pain. New York: The Mac Graw Hill Companies Inc; 1389–1402

24 Rosen S. chapter 174 - Percutaneous Cordotomy. In: Waldman SD, Bloch JI, editors. Pain Management [Internet]. Philadelphia: W.B. Saunders; 2007:1501–17. Available at: http://www.sciencedirect.com/science/article/pii/B9780721603346501783

25 Patt RE. 15 - Neurosurgical Intervention for Chronic Pain Problems. In: FROST EAM, editor. Clinical Anesthesia in Neurosurgery [Internet]. Butterworth-Heinemann 1991:347–81. Available at: http://www.sciencedirect.com/science/article/pii/B9780409901719500210

26 Silvers JE, Campbell JN, Argoff CE. Chapter 42 - Neurostimulatory and Neuroablative Procedures. In: Argoff CE, McCleane G, editors. Pain Management Secrets (Third Edition) [Internet]. Third Edition Philadelphia: Mosby; 2009:323–7. Available at: http://www.sciencedirect.com/science/article/pii/B9780323040198000421

27 Cherny NI. Chapter 43 - The management of cancer pain. In: Melzack R, Wall PD, editors. Handbook of Pain Management [Internet]. Philadelphia: Churchill Livingstone; 2003:641–66. Available at: http://www.sciencedirect.com/science/article/pii/B9780443072017500473

28 Sather MD, Follett KA. Chapter 19 - Neurosurgical Management of Pain. In: Benzon HT, Rathmell JP, Wu CL, Turk DC, Argoff CE, editors. Raj's Practical Management of Pain (Fourth Edition) [Internet]. Fourth Edition Philadelphia: Mosby; 2008:401–11. Available at: http://www.sciencedirect.com/science/article/pii/B9780323041843500224

29 Jackson MB, Pounder D, Price C, Matthews AW, Neville E. Percutaneous cervical cordotomy for the control of pain in patients with pleural mesothelioma. Thorax 1999;54(03): 238–241

30 Steel D, Kirkman MA, Thompson DNP, Aquilina K. Open thoracic anterolateral cordotomy for pain relief in children: report of 2 cases. J Neurosurg Pediatr 2017;20(03):278–283

31 Bain E, Hugel H, Sharma M. Percutaneous cervical cordotomy for the management of pain from cancer: a prospective review of 45 cases. J Palliat Med 2013;16(08):901–907

32 Lewin J, Hugel H, Sharma ML. Percutaneous cervical cordotomy for non-cancer pain in a patient with terminal esophageal carcinoma. J Pain Symptom Manage 2012;43(03):e8–e9
33 Honey CR, Yeomans W, Isaacs A, Honey CM. The dying art of percutaneous cordotomy in Canada. J Palliat Med 2014;17(05):624–628
34 Crul BJP, Blok LM, van Egmond J, van Dongen RTM. The present role of percutaneous cervical cordotomy for the treatment of cancer pain. J Headache Pain 2005;6(01):24–29
35 Kanpolat Y, Ugur HC, Ayten M, Elhan AH. Computed Tomography-guided Percutaneous Cordotomy for Intractable Pain in Malignancy. Operative Neurosurgery 2009 Mar 1;64(suppl_1):ONS187–94.
36 Sanders M, Zuurmond W. Safety of unilateral and bilateral percutaneous cervical cordotomy in 80 terminally ill cancer patients. J Clin Oncol 1995;13(06):1509–1512
37 Kanpolat Y. Neurosurgical Management of Cancer Pain. In: Sindou M, editor. Practical Handbook of Neurosurgery [Internet]. Vienna: Springer Vienna; 2009 [cited 2020 Apr 7]. p. 1388–407. Available at: http://link.springer.com/10.1007/978-3-211-84820-3_82
38 Tasker RR, North R. Cordotomy and Myelotomy. In: North RB, Levy RM, editors. Neurosurgical Management of Pain [Internet]. New York, NY: Springer New York; 1997:191–220. Available at: https://doi.org/10.1007/978-1-4612-1938-5_15
39 Gybels JM. Indications for use of neurosurgical techniques in pain control. In: Bond MR, Charlton JE, Wolf J editors. Proceedings of the Sixt world Congress on Pain. Amsterdam: Elsevier; 475
40 Osenbach RK, Burchiel KJ. Percutaneous cordotomy. In: Kaye A, Black P (eds). Operative Neurosurgery, chapter 128. Philadelphia: ChurchillLivingstone; 1569–1579
41 Raslan AM. Percutaneous Computed Tomography-guided Radiofrequency Ablation of Upper Spinal Cord Pain Pathways for Cancer-Related Pain. Operative Neurosurgery 2008 Mar 1;62 (suppl_1):ONS226–34.
42 Kanpolat Y. Percutaneous stereotactic pain procedures: percutaneous cordotomy, extralemniscal myelotomy, trigeminal tractotomy-nucleotomy. In: Surgical Management of pain Burchiel K and editors. Stuttgart: Thieme; 2002:745–762
43 Kanpolat Y. Percutaneous destructive pain procedures on the upper spinal cord and brain stem in cancer pain: CT-guided techniques, indications and results. In: Pickard JD, Akalan N, Di Rocco C, Dolenc VV, Antunes JL, Mooij JJA, et al., editors. Advances and Technical Standards in Neurosurgery [Internet]. Vienna: Springer Vienna; 2007:147–73. Available at: https://doi.org/10.1007/978-3-211-47423-5_6
44 Syed ON, Komotar RJ, Winfree C. Cordotomy. In: Connolly S, Mc Khann GM, Huang J, Choudhri TF, Komotar RJ, Mocco J (eds). Fundamentals of Operative Techniques in Neurosurgery. New York: Thieme; 2010:635–638
45 Lahuerta J, Lipton S, Wells JC. Percutaneous cervical cordotomy: results and complications in a recent series of 100 patients. Ann R Coll Surg Engl 1985;67(01):41–44

A Simple Method to Avoid Brain Shift during Neuronavigation: Technical Note

Método simples para se evitar brain shift na neuronavegação: Nota técnica

Jair Leopoldo Raso[1]

[1] Faculdade de Ciências Médicas de Minas Gerais, Instituto Mineiro de Neurocirurgia, Vale do Sereno, Nova Lima, MG, Brazil

Arq Bras Neurocir 2021;40(1):78–81.

Address for correspondence Jair Leopoldo Raso, PhD, Faculdade de Ciências Médicas de Minas Gerais, Instituto Mineiro de Neurocirurgia, Alameda Oscar Niemeyer, 400/404, Vale do Sereno, Nova Lima, MG, 34006 049, Brazil (e-mail: jraso@uol.com.br).

Abstract

Introduction The precise identification of anatomical structures and lesions in the brain is the main objective of neuronavigation systems. Brain shift, displacement of the brain after opening the cisterns and draining cerebrospinal fluid, is one of the limitations of such systems.

Objective To describe a simple method to avoid brain shift in craniotomies for subcortical lesions.

Method We used the surgical technique hereby described in five patients with subcortical neoplasms. We performed the neuronavigation-guided craniotomies with the conventional technique. After opening the dura and exposing the cortical surface, we placed two or three arachnoid anchoring sutures to the dura mater, close to the edges of the exposed cortical surface. We placed these anchoring sutures under microscopy, using a 6–0 mononylon wire. With this technique, the cortex surface was kept close to the dura mater, minimizing its displacement during the approach to the subcortical lesion. In these five cases we operated, the cortical surface remained close to the dura, anchored by the arachnoid sutures. All the lesions were located with a good correlation between the handpiece tip inserted in the desired brain area and the display on the navigation system.

Conclusion Arachnoid anchoring sutures to the dura mater on the edges of the cortex area exposed by craniotomy constitute a simple method to minimize brain displacement (brain-shift) in craniotomies for subcortical injuries, optimizing the use of the neuronavigation system.

Keywords
- neuronavigation
- brain shift
- surgical technique
- brain surgery

Resumo

Introdução A identificação precisa de estruturas anatômicas e lesões no cérebro é o principal objetivo dos sistemas de neuronavegação. *Brain shift,* deslocamento do cérebro após abertura das cisternas e drenagem de líquor, é uma das limitações do método.

received
April 30, 2020
accepted
July 7, 2020
published online
November 26, 2020

DOI https://doi.org/10.1055/s-0040-1716560.
ISSN 0103-5355.

Thieme Revinter Publicações Ltda., Rua do Matoso 170, Rio de Janeiro, RJ, CEP 20270-135, Brazil

Objetivo Descrever um método simples para se evitar *brain shift* nas craniotomias para lesões subcorticais.

Método A técnica cirúrgica descrita foi utilizada em cinco casos de pacientes portadores de neoplasias subcorticais. As craniotomias guiadas por neuronavegação foram realizadas com a técnica habitual. Após abertura da dura-máter e exposição da superfície cortical, dois ou três pontos de ancoramento da membrana aracnoide foram realizados na dura-máter, junto às bordas da superfície cortical exposta. Estes pontos de ancoramento foram feitos sob microscopia utilizando-se mononylon 6–0. Com esta técnica, a superfície do córtex era mantida junto à dura-máter, minimizando seu deslocamento durante a abordagem da lesão subcortical. Nos cinco casos em que a técnica foi utilizada, a superfície cortical permaneceu próxima à dura-máter, ancorada pelas suturas da aracnoide. Todas as lesões foram localizadas com boa correlação entre a ponteira inserida na área cerebral desejada e o registro do sistema de navegação.

Conclusão Suturas de ancoramento da aracnoide na dura-máter junto às bordas da área de córtex exposta pela craniotomia constituem método simples para minimizar o deslocamento do cérebro (*brain-shift*) nas craniotomias para lesões subcorticais, otimizando a utilização do sistema de neuronavegação.

Palavras-chave
- neuronavegação
- brain shift
- técnica cirúrgica
- cirurgia cerebral

Introduction

Neuronavigation is a technology recently added to neurosurgical procedures for planning craniotomies and real-time pinpointing of intracranial lesions and their relationship with anatomical structures. The available systems use magnetic resonance imaging (MRI) or computed tomography (CT)-scan images taken before the procedure.[1] For subcortical lesions, such references may become inaccurate because of brain displacement caused by gravity and cerebrospinal fluid (CSF) drainage. This phenomenon, brain shift, may cause the surgeon to err, which is one of the limitations of this method. The present study aimed at describing a simple method to minimize the effects of brain shift in approaches to subcortical lesions, providing the surgeon with greater safety and confidence in the use of neuronavigation.

Method

We used the technique hereby described to operate five patients with subcortical neoplasms. We performed the craniotomy according to planning, aided by neuronavigation. We used two neuronavigator models (Medtronic, Minneapolis, Minnesota, USA; BrainLab, Munich, Germany), in which the record is obtained by correlating landmarks on the patient's skin and skull, and we used a handpiece tip to obtain the point-to-point correspondence. Neuronavigation was initially used to plan the extension of the craniotomy, keeping the subcortical lesion as the central target. After removing the bone flap, we anchored the dura to the bone, using the conventional technique. We then used neuronavigation to plan the dura mater opening around the projection of the lesion. After exposing the cortical surface and before opening the arachnoid over the area chosen for corticectomy, we anchored the arachnoid to the dura, close to the edges of the exposed area, using 2 or 3 6–0 mononylon sutures under microscopy (►**Fig. 1**). Next, we used neuronavigation on the surface to identify the ideal point for corticectomy and the trajectory to address the subcortical lesion. Then, we opened the arachnoid at the point chosen for corticectomy. We checked the trajectory of the approach in real time using neuronavigation, until we reached the subcortical lesion. Throughout the five cases in which we used this approach, the cortical surface remained close to the dura mater, anchored by the arachnoid sutures. All the lesions were located bearing a good correlation between the handpiece tip inserted in the desired brain area and what the navigation system displayed.

Discussion

Neuronavigation is a technology already incorporated in most neurosurgery services. It assists the surgeon in planning craniotomies and in the precise location of deep lesions and their relationship with anatomical landmarks. It is also useful in providing maximum safety in lesion resections.

Neuronavigation uses the same principles as stereotaxis, based on the Cartesian coordinate system. Any point in the brain can be reached by measuring the lesion to be addressed in the horizontal, frontal and sagittal planes. The neuronavigation system provides precise surgical guidance, paralleling the measurements obtained with MRI or CT scan data from the patient. This reconstruction is displayed on a computer workstation console, placed next to the surgical field. Thus, the resonance images displayed on the screen become maps, correlating points on the scanned image with corresponding locations within the brain in real time.

In subcortical lesions, the neuronavigation system assists in choosing the corticectomy location, in planning and

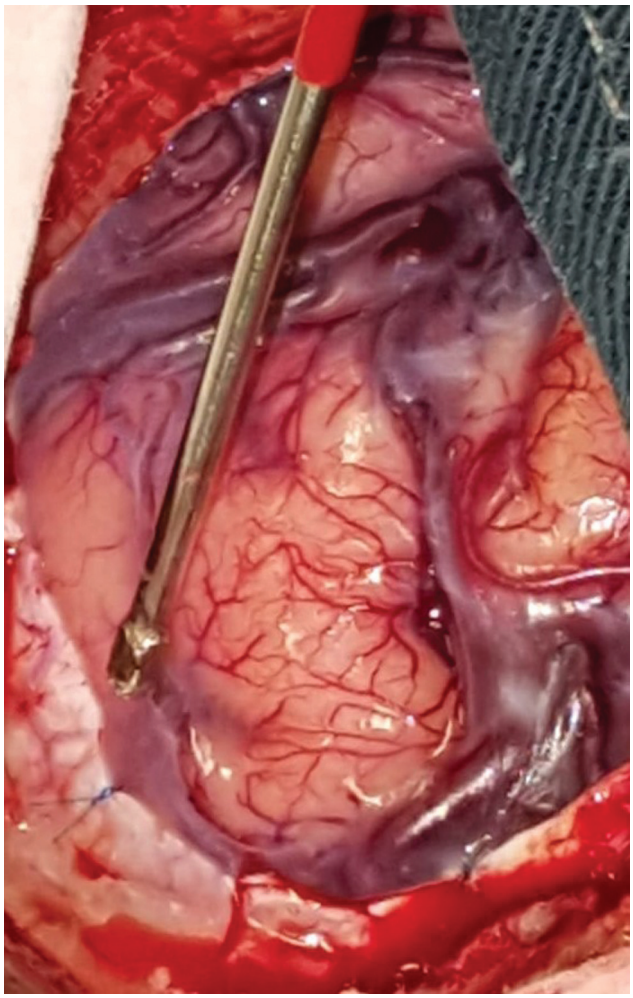

Fig. 1 Frontoparietal craniotomy. The suction tip points to the arachnoid anchorage suture to the dura-mater, close to the craniotomy edge.

executing the trajectory and, finally, in the precise location of the lesion.

However, the method has limitations. The navigation system handpiece tip used by the surgeon at a certain point in the brain correlates with MRI or CT images obtained prior to the surgical procedure. However, during the surgical procedure, the brain moves, either because of gravity or due to relaxation caused by the drainage of CSF (brain shift). Regular systems do not automatically correct for this brain shift and, therefore, the target to be reached. This displacement causes an error in the correlation between the structure shown on the console display and the exact brain region pointed out by the surgeon, making the navigation method inaccurate.

The error caused by brain shift is progressive and depends on several other factors such as head position, cerebral edema, bleeding, use of brain retractors, removal of the lesion and the effects of anesthetic drugs, diuretics or mechanical ventilation.

This correlation accuracy between the neuronavigation and the target structures was studied by Zinreich et al in a replica of the skull made of plastic, and subsequently in three patients.[2] In the model, the average error between the image and the actual location was between 1 and 2 mm. In surgical cases, the display error between the point shown on the system display and the true anatomical location varied from 0.3 to 2.2 mm.

The error caused by the brain shift was estimated by Golfinos et al[3] as being $<$ 2mm in 92% of the navigation systems using MRI images, and in 82% when CT scans were used. However, over time, the method becomes even more inaccurate. Errors $<$ 2mm can be found in 77% of cases using MRI and in 62% with CT scan images.

There are several technological solutions to correct the brain shift effects, updating the data obtained in real time. Among them are the electromagnetic systems and those based on ultrasound. However, these systems are not widely available.[4]

The accuracy of neuronavigation systems can be increased by using intraoperative MRI images, which provide real-time data, assessing the effects of brain shift during surgery and documenting residual lesions.

Nimsky et al used intraoperative MRI to quantify and correct brain shift.[5] There was great variability in measurements, reaching 24 mm of cortical surface shifting and $>$ 3 mm in the margins of deep lesions. Of the 64 study participants, intraoperative MRI scans were performed using a 0.2-T device, with an open setup, to correct and update navigation data.

In another study,[6] Nimsky et al described the use of a microscope integrated with the MRI machine in the operating room. The patients were placed on the MRI machine table with their heads fixed at $\sim$ 1.5 m from the center of the magnetic field by a head support made of compatible ceramics. For the acquisition of intraoperative images, the table was slid to the center of the resonance in $<$ 30 seconds, enhancing the acquisition of intraoperative images to correct for the brain shift.

Brain shifting can be quite distinct according to the brain region of interest. Furthermore, it is a dynamic process. Nabavi et al developed a software (3D Slicer) that makes a quantitative analysis of the degree and direction of the brain shift.[7] For this, they used a 0.5 T MRI device, vertically open, which enables the acquisition of multiple intraoperative images without the need to move the patient. With this method, they managed to optimize image acquisition for computational analysis of brain deformations during the surgical procedure.

Marreiros et al assessed a method for measuring and compensating for brain shift in an experimental study in rabbits.[8] For this, they used superficial blood vessels as reference points. The vessels were displayed by means of infrared cameras aligned with the central point of the vessels seen in the preoperative magnetic resonance angiogram. There was a good correlation between the volume shift seen in the system and the real state of the brain, with $\sim$ 4 mm displacements.

Following the same rationale, Jiang et al proposed a method to compensate for the brain shift that integrates vessel and groove sightings, using a phase-change three-dimensional (3D) measurement, which provides direct 2D image pixels and their corresponding 3D points.[9] The brain surface measurements

were tracked noninvasively in five pig brains, assessing the shifting caused by gravity or by direct compression.

Sun H et al developed a method capable of estimating the three-dimensional shape of the brain surface in real time.[10] They compared the shape with the cortical surface preregistered in the MRI. Cortical displacement was used to guide the whole brain model by updating the volumes obtained by preoperative MRI imaging. According to the authors, the accuracy of this system was $\sim$ 1mm.

In a two-part experimental study, Reinertsen et al compared the brain shift correction from intraoperative ultrasound images and preoperative MRI.[11] In the first part, they tested the technique using realistic simulation, comparing the results with previously measured brain shifts. In the second part of the study, they obtained MRI and ultrasound images from a pva-cryogel phantom model for three different deformations. On average, deformations of a 7.5 mm magnitude were corrected to 1.6 mm by the ultrasound recording, and to 1.07 mm using the MRI data.

The methods described to compensate for the effects of brain shift are sophisticated and are not available in most services.

Our arachnoid anchoring method, hereby described, is simple and easy to perform. The arachnoid anchorage sutures keep the cortical surface closer to the dura mater, decreasing the cortical surface displacement caused by gravity and CSF drainage. It can be used to approach subcortical lesions, minimizing the effects of brain shift vis-à-vis the location of the lesion. Its great merit is to facilitate the location of the lesion, avoiding errors in trajectory and distance from the surface caused by the brain shift. It does not prevent the effects of brain dislocation caused by the progressive exeresis of the lesion; thus, it is not useful for assessing the degree of lesion resection.

Conclusion

Arachnoid anchorage sutures to the dura near the edges of the cortex area exposed by the craniotomy constitute a simple method to minimize brain displacement (brain-shift) in craniotomies for subcortical lesions, optimizing the usage of the neuronavigation system.

Conflict of Interests
The authors have no conflict of interests to declare.

References

1 Spetzger U, Laborde G, Gilsbach JM. Frameless neuronavigation in modern neurosurgery. Minim Invasive Neurosurg 1995;38(04): 163–166
2 Zinreich SJ, Tebo SA, Long DM, et al. . Frameless stereotaxic integration of CT imaging data: accuracy and initial applications. Radiology 1993;188(03):735–742
3 Golfinos JG, Fitzpatrick BC, Smith LR, Spetzler RF. Clinical use of a frameless stereotactic arm: results of 325 cases. J Neurosurg 1995;83(02):197–205
4 Ganslandt O, Behari S, Gralla J, Fahlbusch R, Nimsky C. Neuronavigation: concept, techniques and applications. Neurol India 2002;50(03):244–255
5 Nimsky C, Ganslandt O, Cerny S, Hastreiter P, Greiner G, Fahlbusch R. Quantification of, visualization of, and compensation for brain shift using intraoperative magnetic resonance imaging. Neurosurgery 2000;47(05):1070–1079, discussion 1079–1080
6 Nimsky C, Ganslandt O, Kober H, Buchfelder M, Fahlbusch R. Intraoperative magnetic resonance imaging combined with neuronavigation: a new concept. Neurosurgery 2001;48(05):1082–1089, discussion 1089–1091
7 Nabavi A, Black PM, Gering DT, et al. . Serial intraoperative magnetic resonance imaging of brain shift. Neurosurgery 2001; 48(04):787–797, discussion 797–798
8 Marreiros FM, Rossitti S, Wang C, Smedby Ö. Non-rigid deformation pipeline for compensation of superficial brain shift. Med Image Comput Comput Assist Interv 2013;16(Pt 2):141–148
9 Jiang J, Nakajima Y, Sohma Y, Saito T, Kin T, Oyama H, Saito N. Marker-less tracking of brain surface deformations by non-rigid registration integrating surface and vessel/sulci features. Int J CARS 2016;11(09):1687–1701
10 Sun H, Lunn KE, Farid H, et al. . Stereopsis-guided brain shift compensation. IEEE Trans Med Imaging 2005;24(08):1039–1052
11 Reinertsen I, Descoteaux M, Siddiqi K, Collins DL. Validation of vessel-based registration for correction of brain shift. Med Image Anal 2007;11(04):374–388

Endonasal Endoscopic Pituitary Adenoma Resection in light of the COVID-19 Pandemic: A Technical Report

Cirurgia endoscópica endonasal para ressecção de macroadenoma hipofisário à luz da pandemia por COVID 19: Nota técnica

Danilo Talacimon Barbosa[1] Dan Zimelewicz Oberman[1] Alick Durão Moreira[1] Luisa Borges[1] Felipe Gonçalves[1] Gustavo Sereno Porto Cabral[1] Rafael Rego Barros[1] Rafael Vaitsman[1] Rodrigo Sodré[1] João Kleskoski[1] Orlando Maia[2] Jorge Luis Amorim Correa[1]

[1] Neurosurgery Service, Hospital de Força Aérea do Galeão (HFAG), Galeão, Rio de Janeiro, RJ, Brazil
[2] Departament of Endovascular Neurosurgery, Hospital de Força Aérea do Galeão (HFAG), Galeão, Rio de Janeiro, RJ, Brazil

Address for correspondence Dan Zimelewicz Oberman, MD, Estrada do Galeão 4101, Galeão, Rio de Janeiro, RJ, 21941-353, Brazil (e-mail: danzoberman@gmail.com).

Arq Bras Neurocir 2021;40(1):82–85.

Abstract

Introduction The endoscopic endonasal transsphenoidal approach (EETA) is routinely used to treat sellar and suprasellar tumors. It provides safe and direct access to tumors in these locations, with wide visualization of anatomical landmarks and great surgical results. With the COVID-19 pandemic, despite the high risk of transmission involved, various surgical procedures cannot be postponed due to their emergency.

Case Report A 62-year-old female presented in the previous two months with headaches, followed by bilateral severe visual loss. In 2016, she was submitted to subtotal resection of a non-secretory macroadenoma. Because of the progressive visual deficits, the EETA was used to the resect the pituitary adenoma.

Technical Note We developed a low-cost adaptation to the surgical fields, covering the patient's head and superior trunk with a regular surgical microscope bag with a tiny slit to enable the endoscope and surgical instruments to enter the nose, thus protecting the personnel in the operating room from the aerosolization of particles. This makes surgery safer for the surgical team and for the patient.

Conclusion In view of the lack of literature on this subject, except for some reports of experiences from some services around the world, we describe the way we have adjusted the EETA in the context of the COVID-19 pandemic.

Keywords
- endoscopic
- endonasal
- transsphenoidal
- skull base
- neurosurgery

Introduction

Currently, the COVID-19 pandemic is the most discussed topic worldwide. It has rapidly spread at an exponential rate, significantly affecting our practice as healthcare professionals and producing a huge global socioeconomic impact.[1–3]

The endoscopic endonasal transsphenoidal approach (EETA) is routinely used to treat sellar and suprasellar tumors. It provides safe and direct access to tumors in these locations, with wide visualization of anatomical landmarks and great surgical results. Besides, it obviates brain retraction and provides a quicker recovery of the

received
June 18, 2020
accepted
September 15, 2020
published online
November 26, 2020

DOI https://doi.org/10.1055/s-0040-1719123.
ISSN 0103-5355.

Thieme Revinter Publicações Ltda., Rua do Matoso 170, Rio de Janeiro, RJ, CEP 20270-135, Brazil

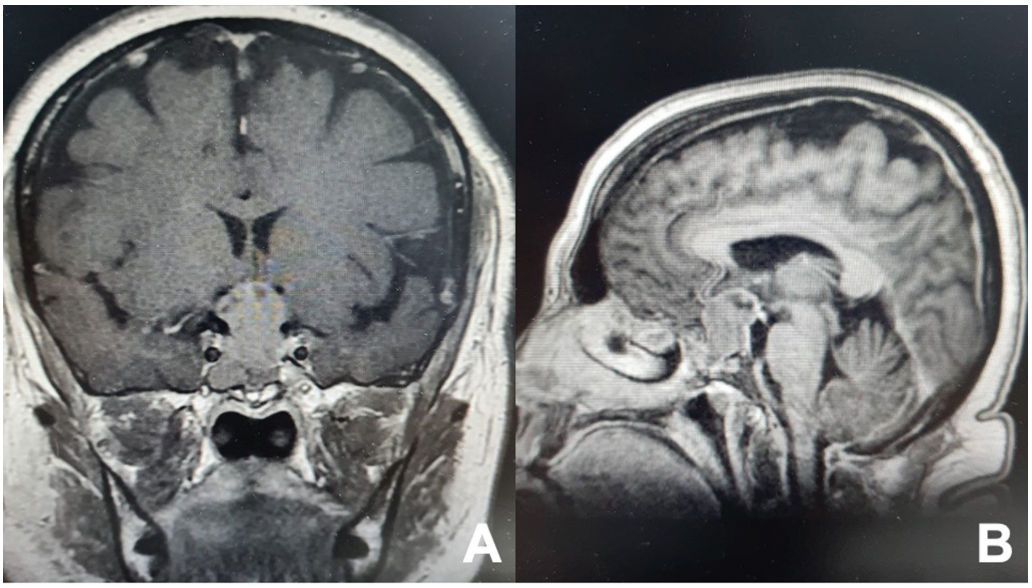

Fig. 1 Preoperative imaging studies. (**A**) Coronal preoperative magnetic resonance imaging (MRI) scan indicating a well-defined mass lesion in the sellar region with suprasellar extension, measuring 25 × 18 × 20 mm, and compressing the optic chiasm. (**B**) Sagittal reconstruction of a head MRI showing suprasellar extension and compression of the optic chiasm.

visual-field defects due to minimal manipulation of the optic apparatus.

Potential concerns during the EETA exist regarding the aerosolization of viral particles, which could theoretically spread throughout the operating room due to aggressive disruption of mucosa and the use of the drill and electrosurgical devices.[4]

We report the experience of performing an EETA in one case in our center during the COVID-19 pandemic.

Case Report

A 62-year-old female presented with headaches two months before hospital admission, followed by progressive bilateral severe visual loss. A campimetry examination detected blindness in the left eye and hemianopia in the right eye (►**Fig. 1**). The pituitary hormonal panel was normal. In 2016, the patient underwent subtotal resection of a nonsecretory macroadenoma through EETA.

A magnetic resonance imaging scan showed a well-delineated, dumbbell-shaped, sellar lesion with suprasellar extension and contrast enhancement, stretching the optic chiasm and optic nerve, measuring 25 mm craniocaudally, 18 mm anteroposteriorly and 20 mm transversely. (►**Fig. 2**)

Because of the progressive visual loss, the EETA with pituitary adenoma resection was performed.

Before the surgery, the patient was tested for COVID-19 following the protocol of our institution.

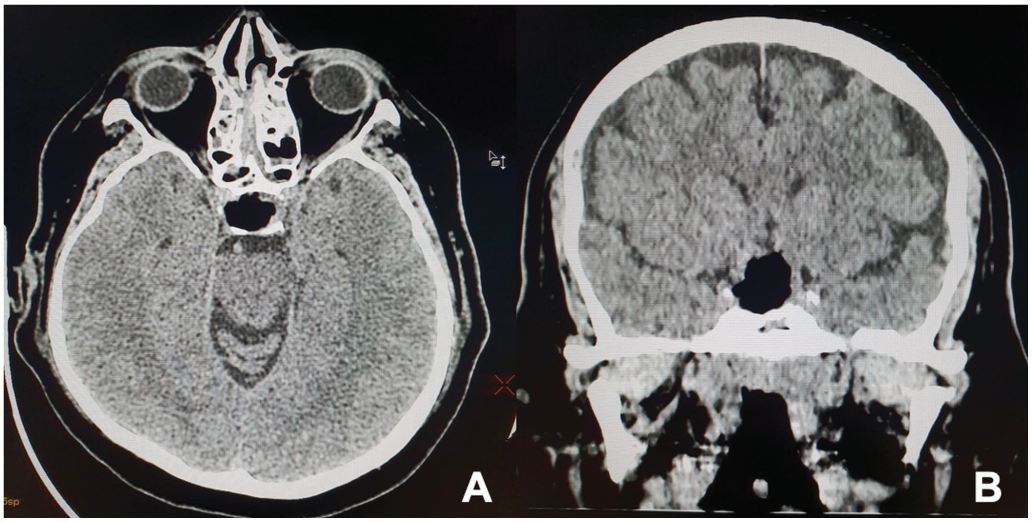

Fig. 2 Threshold plots of the Humphrey field analyser demonstrating (**A**) hemianopia in the right eye, and (**B**) loss of vision in the left eye.

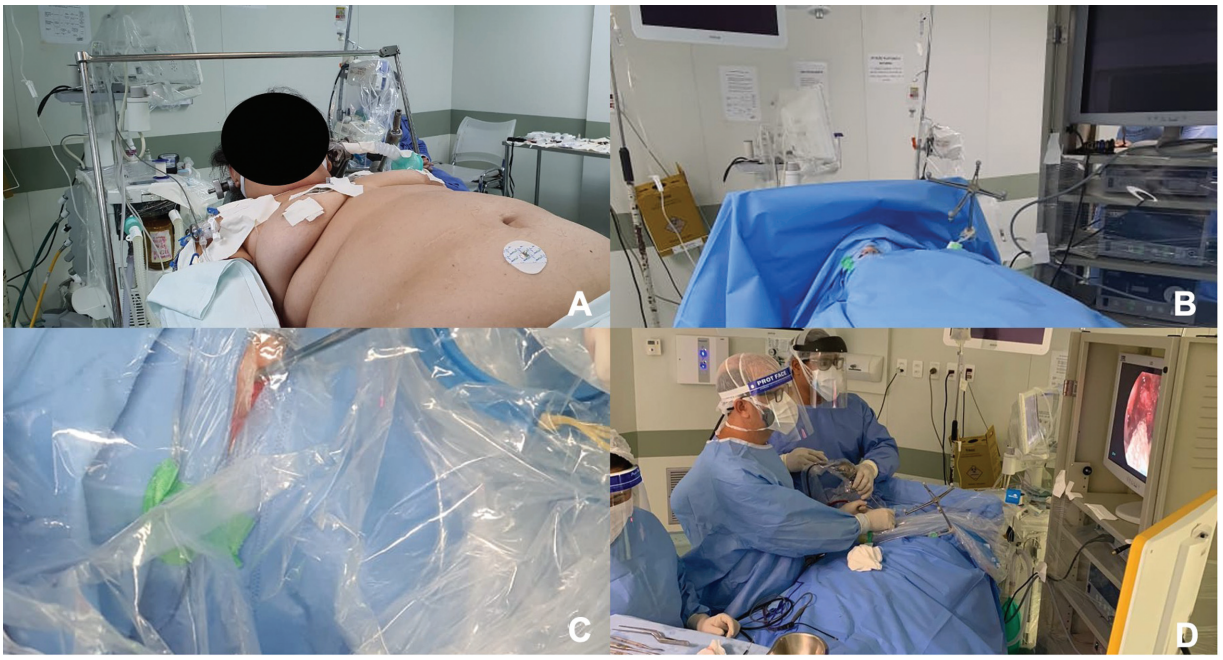

Fig. 3 Patient positioning in the surgical table: (**A**) with the metal arch above the head; (**B**,**C**) with the surgical fields in place before and after insertion of the microscope bag. (**D**) Photograph showing the layout of the room during the surgical procedure, and the use of personal protective equipment (PPE) by the surgical team.

Technical Note

Only essential personnel entered the operating room (OR), including two neurosurgeons, two anesthesiologists, one scrub nurse and one running nurse. All surgical and anesthetic teams used personal protective equipment (PPE), which included: tight-fitting N95/PFF-2 mask, 1 surgical mask over it, face shield, and standard sterile surgical gloves and gown, as recommended by our local infectious disease control team. During the intubation and extubation procedures, only the anesthesiologists were present in the OR. The running nurse stayed outside the OR, but right by entrance, with emergency supplies that might be necessary readily available.

We developed a low-cost adaptation to the surgical fields, using a setup with a regular surgical microscope bag sealed with sterile adhesive drapes around the head and superior trunk of the patient, with only a tiny slit on it to enable the insertion of the endoscope and surgical instruments through the nose. To support the microscope bag like a tent, a metal arch, normally used around the head to collect blood, was positioned over the head. This arrangement was designed to protect the OR personnel from aerosolized particles (►**Fig. 3**).

Under general anesthesia, the patient was positioned in a supine position with the trunk elevated 30°. The head, fixed with the 3-pin Mayfield head holder, was tilted back 20° and rotated 25° toward the right shoulder. Neuronavigation was used, following institutional protocol. The neurosurgeon was positioned on the right side of the patient. Additionally, during maneuvers that could increase aerosolization, such as using the high speed drill, we performed generous irrigation with saline and blocked the entry site of the endoscope and suction tube on the microscope bag, avoiding aerosolized particles from spreading to the OR (►**Fig. 3**).



Fig. 4 (**A**) Axial and (**B**) coronal postoperative computed tomography (CT) scans showing total resection of the lesion.

A postoperative computed tomography scan showed complete resection of the tumor, with decompression of the optic nerve and chiasma (►**Fig. 4**). The patient was discharged four days postoperatively with subjective improvement of the visual field and acuity.

Discussion

Developing safety protocols for EETA during the COVID-19 pandemic is an evolving topic. Emerging data demonstrate that the EETA is currently a high-risk procedure, due to the high viral load and replication within the nasal cavities. As an aerosol-generating procedure, it can promote nosocomial viral transmission.[5] High rates of infection due to viral charge have been reported in upper-airway procedures, including an outbreak among fourteen medical staff that were

confirmed infected after an EETA.[6] There are few papers discussing this subject, and most of them are case reports.[4,6]

Currently, the care for neurosurgical patients presents numerous challenges regarding not only the safety of the patient and of the community, but also that of physicians and OR personnel. This means that, to save resources and to avoid unnecessary exposure, there is a need to postpone all elective interventions. When that is not possible, even deviations from the standard EETA to transcranial approaches can be justified, in light of the present extraordinary circumstances. These decisions, however, are likely to be highly patient-, surgeon- and institution-specific. Urgent procedures, like the one herein described, cannot be delayed, and surgeons must provide the best available care to their patients, even with the risk of exposure to COVID-19.[4,7]

It has become clear that physicians of all specialties need to change the way they work, mainly those who deal with the nasal cavities, nasopharynx and oropharynx. Even asymptomatic patients have exhibited high viral loads at these sites.[8,9] We believe that the strategy performed in the present case is a feasible and cheap way to keep EETA in the surgical repertoire for sellar and suprasellar surgery, since microscope bags are available in many neurosurgical departments around the world, even in developing countries like Brazil.

Conclusion

The concerns regarding the potential spread of COVID-19 during EETAs remain high, even in asymptomatic patients or in those with negative tests, because of the possibility of false-negative results. Because endonasal surgery creates clouds of droplets and aerosols which may permeate the OR,[10,11] we recommend that all patients be tested preoperatively for COVID-19, and the use of PPE for all personnel in the surgical theater. Local guidelines are warranted. The strategy herein described can be an important adjunct to these guidelines.

Ethics Committee for Research Protocols

The protocol was approved by the local institutional Review Board (Ethics Committee for Research Protocols – CEPI).

Conflict of Interest

The authors have no conflict of interests to declare.

References

1 Lai C-C, Shih T-P, Ko W-C, Tang H-J, Hsueh P-R. Severe acute respiratory syndrome coronavirus 2 (SARS-CoV-2) and coronavirus disease-2019 (COVID-19): The epidemic and the challenges. Int J Antimicrob Agents 2020;55(03):105924. Doi: 10.1016/j.ijantimicag.2020.105924

2 Ge H, Wang X, Yuan X, et al. The epidemiology and clinical information about COVID-19. Eur J Clin Microbiol Infect Dis 2020; 39(06):1011–1019. Doi: 10.1007/s10096-020-03874-z [Internet]

3 Jean WC, Ironside NT, Sack KD, Felbaum DR, Syed HR. The impact of COVID-19 on neurosurgeons and the strategy for triaging non-emergent operations: a global neurosurgery study. Acta Neurochir (Wien) 2020;162(06):1229–1240. Doi: 10.1007/s00701-020-04342-5 [Internet]

4 Lo YT, Yang Teo NW, Ang BT. Editorial. Endonasal neurosurgery during the COVID-19 pandemic: the Singapore perspective. J Neurosurg 2020;•••:1–3

5 Tran K, Cimon K, Severn M, Pessoa-Silva CL, Conly J. Aerosol generating procedures and risk of transmission of acute respiratory infections to healthcare workers: a systematic review. PLoS One 2012;7(04):e35797

6 Zhu W, Huang X, Zhao H, Jiang X. A COVID-19 Patient Who Underwent Endonasal Endoscopic Pituitary Adenoma Resection: A Case Report. Neurosurgery 2020;87(02):E140–E146. Doi: 10.1093/neuros/nyaa147 [Internet]

7 Studdert DM, Hall MA. Disease Control, Civil Liberties, and Mass Testing - Calibrating Restrictions during the Covid-19 Pandemic. [Internet]N Engl J Med 2020;383(02):102–104. Doi: 10.1056/nejmp2007637

8 Zou L, Ruan F, Huang M, et al. SARS-CoV-2 Viral Load in Upper Respiratory Specimens of Infected Patients. N Engl J Med 2020; 382(12):1177–1179

9 Chen W-J, Yang J-Y, Lin J-H, et al. Nasopharyngeal shedding of severe acute respiratory syndrome-associated coronavirus is associated with genetic polymorphisms. Clin Infect Dis 2006;42(11):1561–1569

10 Patel ZM, Fernandez-Miranda J, Hwang PH, et al. In Reply: Precautions for Endoscopic Transnasal Skull Base Surgery During the COVID-19 Pandemic. Neurosurgery 2020;87(02):E162–E163. Doi: 10.1093/neuros/nyaa156 [Internet]

11 Huang X, Zhu W, Zhao H, Jiang X. In Reply: Precautions for Endoscopic Transnasal Skull Base Surgery During the COVID-19 Pandemic. Neurosurgery 2020;87(02):E160–E161. Doi: 10.1093/neuros/nyaa145 [Internet]

Gangliocytic Paraganglioma of the Filum Terminale. A Rare Entity

Paraganglioma gangliocítico do filum terminale. Uma entidade rara

Sofia Isabel Carneiro Pereira Guerra Tavares[1] Gonçalo Maria Sengo Agante Guerreiro Costa[1]

[1] Department of Neurosurgery, Centro Hospitalar e Universitário de Coimbra, Coimbra, Portugal

Arq Bras Neurocir 2021;40(1):86–90.

Address for correspondence Sofia Isabel Carneiro Pereira Guerra Tavares, MSc, Department of Neurosurgery, Centro Hospitalar e Universitário de Coimbra, Praceta Professor Mota Pinto, 3000-075 Coimbra, Portugal (e-mail: sofia.icpg.tavares@gmail.com).

Abstract

Paragangliomas are rare, benign and slow-growing neuroendocrine tumors that can arise from the adrenal medulla (85–90%) or from the extra-adrenal paraganglia.

In the central nervous system (CNS), they can be found at several sites, but more often at the *cauda equina* and *filum terminale* region, where they account for between 2.5 and 3.8% of total tumor cases of that region. There are only 8 cases described in the literature that mention the presence of the gangliocytic variant of this entity at the *filum terminale*.

We present the case of a 41-year-old man with chronic lumbar pain refractory to medical treatment, without any associated neurological deficits. Magnetic resonance imaging (MRI) revealed an intradural, extramedullar oval lesion with regular contours and homogeneous caption of contrast at L1 level.

He was submitted to surgical treatment, with complete resection of the lesion. The histological analysis revealed a gangliocytic paraganglioma of the *filum terminale*. At 5 years of follow-up, he remains asymptomatic and without any signs of relapse.

These are lesions with an overall good prognosis with gross total resection. Although the recurrence rate is extremely low, prolonged observation is recommended due to the slow-growing nature of the tumor, being estimated that between 1 and 4% can recur even after gross total removal.

Keywords
- paraganglioma
- gangliocytic
- filum terminale
- low back pain

Resumo

Os paragangliomas são tumores neuroendócrinos raros, benignos e de crescimento lento, que podem ter origem na medula adrenal (85–90%) ou nos paraganglia extra-adrenais.

Podem ser encontrados em diversas localizações no sistema nervoso central (SNC), mas mais frequentemente a nível da cauda equina ou no *filum terminale*, onde correspondem a entre 2,5 e 3,8% do número total de tumores dessa região. Existem

received
April 10, 2020
accepted
August 5, 2020
published online
October 16, 2020

DOI https://doi.org/10.1055/s-0040-1718426.
ISSN 0103-5355.

Thieme Revinter Publicações Ltda., Rua do Matoso 170, Rio de Janeiro, RJ, CEP 20270-135, Brazil

apenas 8 casos descritos na literatura que descrevem a presença da variante gangliocítica desta entidade no *filum terminale.*
Apresentamos o caso de um homem com 41 anos de idade com dor lombar crônica refratária ao tratamento médico, sem qualquer déficit neurológico associado. A ressonância magnética (RM) demonstrou uma lesão oval intradural e extramedular, de contornos regulares, com captação homogénea de contraste localizada ao nível de L1.
O paciente foi submetido a intervenção cirúrgica, tendo sido feita uma resseção completa da lesão. A análise histológica revelou um paraganglioma gangliocítico do *filum terminale*. Aos 5 anos de seguimento, o paciente permanece assintomático e sem sinais de recidiva.
Estas são lesões com um bom prognóstico após uma remoção macroscopicamente total. Embora a taxa de recidiva seja muito baixa, a vigilância prolongada é recomendada devido ao crescimento lento destes tumores, sendo estimado que entre 1 e 4% podem recidivar mesmo após uma remoção total.

Palavras-chave
- paraganglioma gangliocítico
- filum terminale
- dor lombar

Introduction

Paragangliomas are rare, benign and slow-growing neuroendocrine tumors that can arise from the adrenal medulla (85–90%) or from the extra-adrenal paraganglia.[1] They derive from the migration of neural crest cells that constitute the sympathetic and parasympathetic nervous system (CNS).[2] Sympathetic paragangliomas are usually secretory and produce catecholamines, while parasympathetic paragangliomas tend to be nonsecretory.

Extra-adrenal paragangliomas can arise anywhere in the sympathetic and parasympathetic chain of ganglia,[1] and occur commonly ($\sim$ 90%[3]) in the neck and head region (mainly from the carotid bodies or *glomus jugulare*[4] - predominantly of parasympathetic nature[1]). In the CNS, they can be found at several sites such as the *sella turcica*, the cavernous sinus, the pineal gland, the pituitary gland, the cerebellopontine angle and the petrous ridge,[5] but more often at the *cauda equina* and *filum terminale* region,[6] where they account for between 2.5 and 3.8% of the total tumor cases of that region.[5] The mean age of presentation is around between 40 and 60 years old with a slight male predominance.[5]

They are histologically characterized by an arrangement of chief cells with an abundance of neurosecretory granules, placed in lobules surrounded by sustentacular cells,[1] designated as a Zellballen pattern.

Extra-adrenal paragangliomas may develop a gangliocytic component (gangliocytic paragangliomas), which consist of ganglion cell components in addition to the sustentacular cells.[1] The diagnosis is confirmed with immunohistochemical staining of the specimens.[1]

The combination of their location at the *filum terminale* with the gangliocytic histological variant creates an extremely rare entity, with only 8 cases described in the literature until now, including the present one.

Case Description

We present a case of a 41-year-old man with recurrent episodes of low back pain irradiating to his lower limbs, with increasing frequency and intensity associated with a sensation of tingling in his legs, with nearly 1 year of evolution. At the physical examination, there was no evidence of bowel or bladder incontinence, sensitive or motor deficits or gait disturbances.

Magnetic resonance imaging (MRI) revealed a well-circumscribed, oval shaped, intradural extramedullar expansive lesion with $\sim$ 1,6 $\times$ 1,2 cm of diameter. It revealed isointense at T1-weighted images, and slightly heterogeneous at T2-weighted images with a discrete hyperintense core. After gadolinium administration, an intense and homogenous enhancement

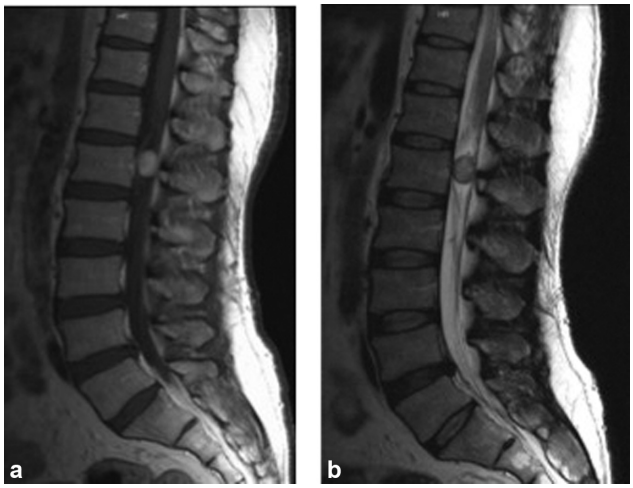

Fig. 1 Magnetic resonance imaging features an oval intradural lesion at L1 level: (a) T2-weighted showing an isointense, slightly heterogeneous well-circumscribed lesion at L1 with a discrete hyperintense core. (b) T1-weighted with gadolinium enhancement showing homogenous contrast-enhancement and a small serpentine upper pole vessel (blue arrow).

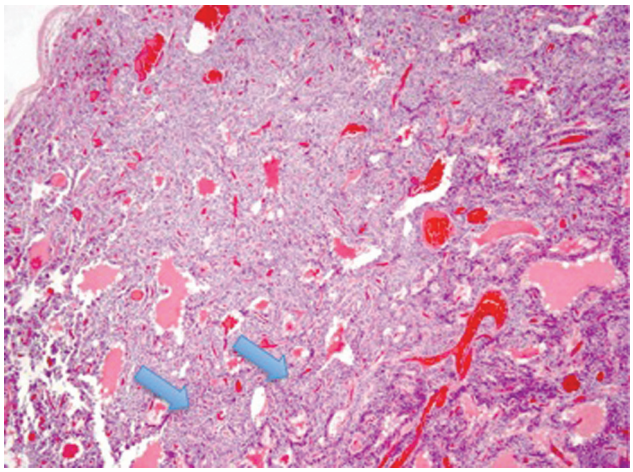

Fig. 2 Hematoxylin and eosin 40x amplification: Typical nested arrangement of cells in a Zellballen pattern (blue arrow), showing trabeculae and cords of cells within a fibrovascular stroma.

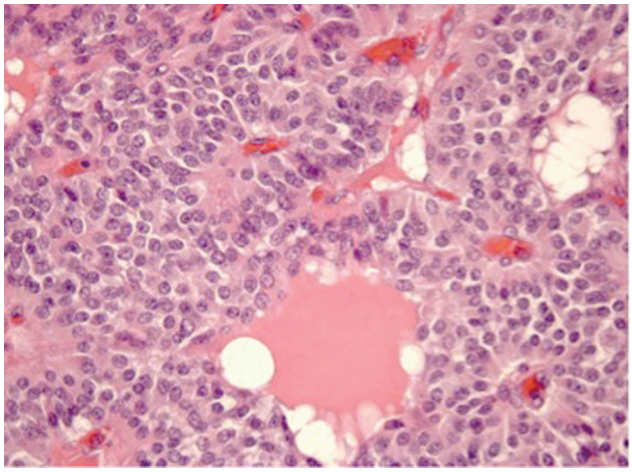

Fig. 3 Hematoxylin and eosin 400x amplification: Chief cells with a big cytoplasm area with an abundance of neurosecretory granules.

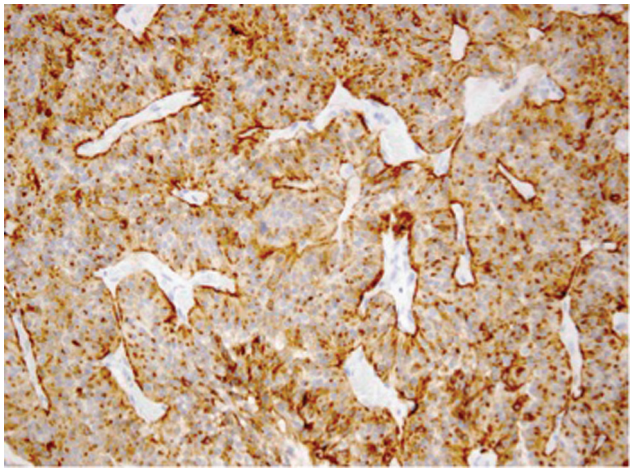

Fig. 4 Cromogranine A positive stain 200x amplification demarcating the cytoplasm of ganglion cells. The reticular organization can be seen.

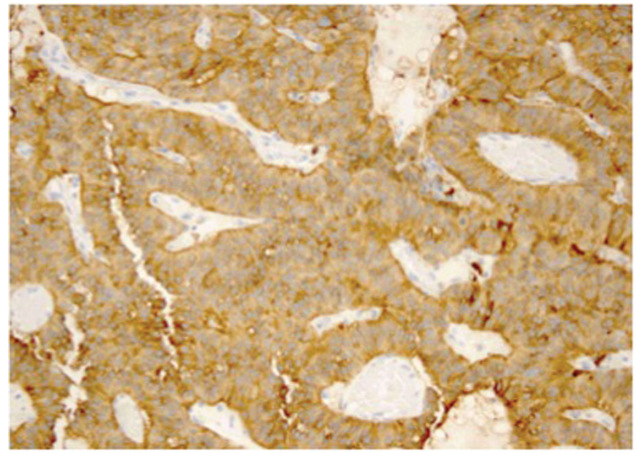

Fig. 5 Synaptophysin stain positive (brown) with 200x amplification.

was noted, as shown in ►**Fig. 1b**, where a small serpentine-like vessel can be observed on the upper pole of the tumor.

The patient was submitted to surgery, being performed a laminectomy of L1 and a microsurgical complete resection of the tumor. The lesion was an exophytic encapsulated intradural mass that distorted and expanded the nerve roots but was not attached to them. The *filum terminale* was easily identified by its distinct appearance and verified by neurostimulation. The tumor was undetachable from it, being needed its careful sectioning. There was no need for dural repair since the surgery was uneventful.

The patient referred an immediate relief of the paresthesias and lower limb pain in the postoperative period. As seems to be the rule for paragangliomas of this location, there was no clinical sign of any associated catecholamine release syndrome.[4]

The histologic analysis of the lesion revealed an arrangement of chief cells with an abundance of neurosecretory granules, organized in lobules surrounded by sustentacular cells,[1] forming a Zellballen pattern, typical of paragangliomas – ►**Figs. 2** and **3**. Additionally, immunopositivity for neuroendocrine markers — chromogranin A (►**Fig. 4**) and synaptophysin (►**Fig. 5**) — supported this histological diagnosis. The presence of ganglion cell components in addition to the sustentacular cells confirmed the diagnosis of a gangliocytic paraganglioma.

At 5 years postoperatively, the patient remains asymptomatic, maintaining imagiological surveillance without any signs of relapse.

Discussion

Paragangliomas are solid, well-encapsulated, highly vascular, slow-growing neuroendocrine tumors arising from specialized neural crest cells.[5]

The first case of a paraganglioma of the *cauda equina* region was published in 1970, even though the authors initially defined the lesion as a "secretory ependymoma"; so, the first authors to precisely define this tumor were Lerman et al in 1972.[3,12] Since then, ~ 220 cases have been reported.[3] However, only 8 cases with gangliocytic

Table 1 Described cases in the literature of gangliocytic paragangliomas of *cauda equine/filum terminale* from the most recent to the first one described

Reported cases in literature	Clinical Findings	Location	Degree of resection
Current case	Low back pain and sciatica; No neurological deficits	L1	Total gross resection
Akbik et al[1]	Temporary urinary incontinence, perineal paresthesias	S1-S2	Total gross resection
Vural et al[7]	Low back pain, sciatica	L4	Total gross resection
Llena et al[8]	Low back pain, LE weakness	L1	Total gross resection
Matschke et al[9]	Low back pain	Cauda equina	Total gross resection
Djindjian et al[4]	Low back pain, sudden paraplegia following sacral infiltration of medication	L2-L5	Total gross resection
Mishra et al[3]		Unknown	Unknown
Moran et al[10]		Unknown	Unknown

variations have been reported, including the present one, as summarized in ►**Table 1**.

Clinical Features

Spinal paragangliomas usually manifest with nonspecific symptoms.[11] Low back pain with or without radiculopathy is the most common presentation (50%) and motor or sensory deficits can be present in $<$ 10% of the patients.[5] Bowel or bladder incontinence is quite rare (3%) though some authors reported a higher frequency of sphincter and genital disturbance, compared with other tumors of this region.[5] Despite their neuroendocrine origin, they rarely have functional hormonal activity or manifestations.[3] However, there are some cases of paragangliomas with functional hormonal activity that can induce perioperative vital instability.[3]

No significant correlation was observed between the duration of symptoms and tumor dimension.[5] In the literature, there are only two described cases of an acute flaccid paraparesis/*cauda equine* syndrome secondary to an intratumoral hemorrhage.[5]

These lesions are commonly encountered at the 4th and 5th decades of life, with a male predominance, and they are sporadic neoplasms,[5] although $\sim$ 1% of cases are autosomal dominant.[2]

Paragangliomas are most worrisome when located in the head and neck region because of their ability to infiltrate cranial nerves in this area.[1] Paragangliomas in the *cauda equina* are similar in nature, but generally are well-demarcated intradural or extradural masses that do not infiltrate the spinal cord, soft tissues, or adjacent bone structures.[1]

The literature reports an extremely low recurrence rate, sometimes occurring 9 years after surgery,[1] and it is estimated that between 1 and 4% can recur following gross total removal.[5] This supports the need for prolonged observation due to the slow growing nature of the tumor. With subtotal resection, 10% of *cauda equina* paragangliomas will recur 1 year following surgery, which is why radiotherapy is recommended after a subtotal resection.[5]

Because of their benign natural history, observation can be a reasonable option in asymptomatic cases, and an overall good prognosis with gross total resection can be expected. However, close clinical follow-up is needed both to rule our more aggressive lesions and due to the potential for growth.[1]

Imagiological Features

Magnetic resonance imaging is the gold standard radiological exam for the diagnosis and follow-up of paragangliomas of the *cauda equina* or of the *filum terminale*.[5] They may appear as hypo- to isointense on T1-weighted images, hyperintense on T2-weighted images, and vividly enhancing on contrasted studies.[1]

These spinal tumors have no pathognomonic features, and other tumors of the *cauda equina*, including meningioma, schwannoma, and myxopapillary ependymoma, can have similar imaging profiles making histologic examination key to diagnosis.[1]

Paragangliomas are vascular tumors, and the identification of features reflecting this quality is crucial.[6] On T2-weighted sequences, intra and peritumoral flow-voids and a salt and pepper appearance may indicate hypervascularity.[6] In addition, hypointense tumor margins on T2-weighted sequences suggesting paramagnetic effects from hemosiderin may also be seen. A "polar sign" has been described in T1 contrast enhanced and T2 images, representing subacute to chronic intratumoral hemorrhages within the lesions superior and inferior poles.[6]

Given enough time, erosion of the adjacent boney structures secondary to chronic bone compression can be seen on plain X-rays or even MRI imaging.[1]

Histological Features

Paraganglionic and neural crest cells have a common origin, and during embryogenesis, they migrate along the neural tube.[5] Paragangliomas result from dysfunction of embryonic paraganglia cell migration or nonregression.[5]

The diagnosis of paragangliomas and the definition of their subtype is always made postoperatively from the histological study of the tumor.[4]

Paragangliomas are comprised of two cell types: chief cells and spindle shaped sustentacular cells, which are classically described as having a "Zellballen" or nesting pattern.[1] In this case, neurofilament staining in spindle cells is present along with ganglion cells confirming a gangliocytic variation of a paraganglioma.[1]

Conclusion

Being slow-growing tumors, paragangliomas do not usually present with characteristic clinical findings. Their imaging is inconclusive, with multiple differential diagnoses. The final diagnosis can only be made with resource to the histological examination of the lesion. Given their benign, slow-growing, noninfiltrative nature, prognosis is very good after total surgical resection, with a low estimated recurrence (4%). The insertion of the tumor on the *filum terminale* makes the surgical resection easier after the section of the *filum*, which guarantees a cure. However, there are reported cases of recurrence many years after surgical resection, supporting the need for a prolonged imagiological and clinical follow-up. When total resection isn't possible, adjuvant treatment with radiotherapy is recommended.

Conflict of Interests

The authors have no conflict of interests to declare.

References

1 Akbik OS, Floruta C, Chohan MO, SantaCruz KS, Carlson AP. Case Report A Unique Case of an Aggressive Gangliocytic Paraganglioma of the Filum Terminale. Case Rep Surg 2016
2 Hilmani S, Ngamasata T, Karkouri M, Elazahri A. Paraganglioma of the filum terminale mimicking neurinoma: Case report. Surg Neurol Int 2016;7(Suppl 5):S153–S155
3 Mishra T, Goel NA, Goel AH. Primary paraganglioma of the spine: A clinicopathological study of eight cases. J Craniovertebr Junction Spine 2014;5(01):20–24
4 Djindjian M, Ayache P, Brugières P, Malapert D, Baudrimont M, Poirier J. Giant gangliocytic paraganglioma of the filum terminale. Case report. J Neurosurg 1990;73(03):459–461
5 Murrone D, Romanelli B, Vella G, Ierardi A. Acute onset of paraganglioma of filum terminale: A case report and surgical treatment. Int J Surg Case Rep 2017;36:126–129
6 Méndez JC, Carrasco R, Prieto MA, Fandiño E, Blázquez J. Paraganglioma of the cauda equina: MR and angiographic findings. Radiol Case Rep 2019;14(10):1185–1187
7 Vural M, Arslantas A, Isiksoy S, Adapinar B, Atasoy M, Soylemezoglu F. Gangliocytic paraganglioma of the cauda equina with significant calcification: first description in pediatric age. Zentralbl Neurochir 2008;69(01):47–50
8 Llena JF, Wisoff HS, Hirano A. Gangliocytic paraganglioma in cauda equina region, with biochemical and neuropathological studies. Case report. J Neurosurg 1982;56(02): 280–282
9 Matschke J, Westphal M, Lamszus K. November 2004: intradural mass of the cauda equina in a woman in her early 60s. Brain Pathol 2005;15(02):169–170, 173
10 Moran CA, Rush W, Mena H. Primary spinal paragangliomas: a clinicopathological and immunohistochemical study of 30 cases. Histopathology 1997;31(02):167–173
11 London F, Mulquin N, Fervaille C, Lebecque O, Jankovski A. Radiologically atypical paraganglioma of the filum terminale as a rare cause of superficial siderosis of the central nervous system. Acta Neurol Belg 2020
12 Lerman RI, Kaplan ES, Daman L. Ganglioneuroma-paraganglioma of the intradural filum terminale. Case report. J Neurosurg 1972; 36:652–658

Trigeminal Ophthalmic Branch Schwannoma: Case Report and Literature Review

Schwannoma trigeminal de ramo oftálmico: Relato de caso e revisão da literatura

Luiza Rech Köhler[1,2] Paulo Moacir Mesquita Filho[1,2,3,4] Fabio Pires Santos[1,5] Renato Sawasaki[6] Richard Giacomelli[2,7] Rafael Cordeiro[2,7] Octavio Karam Ruschel[2,7] Daniela Schwingel[8]

[1] Medical School, Universidade de Passo Fundo, Passo Fundo, RS, Brazil
[2] Academic League of Neurology and Neurosurgery Service (LASNN), Passo Fundo, RS, Brazil
[3] Neurology and Neurosurgery Service (SNN), Passo Fundo, RS, Brazil
[4] Department of Neurosurgery, Hospital de Clínicas de Passo Fundo, Passo Fundo, RS, Brazil
[5] ENT surgeon, Hospital de Clínicas de Passo Fundo, Passo Fundo, RS, Brazil

Arq Bras Neurocir 2021;40(1):91–96.

Address for correspondence Luiza Rech Köhler, Departamento de Neurocirurgia, Hospital de Clínicas de Passo Fundo, Rua Tiradentes, 295, Passo Fundo, RS, 99010-260, Brazil (e-mail: luiza_kohler@hotmail.com).

[6] Department of Oral and Maxillofacial Surgery, Hospital de Clínicas de Passo Fundo, RS, Brazil
[7] Hospital de Clínicas de Passo Fundo, RS, Brazil
[8] Instituto de Patologia de Passo Fundo, Passo Fundo, RS, Brazil

Abstract

Schwannomas are the fourth most common primary neoplasms affecting the brain and cranial nerves. Central lesions commonly arise from sensory nerve roots, and a common intracranial site is the vestibular branch of the 8th nerve (>85%). We present the case report of a patient who has a schwannoma extending from the pterygopalatine fossa to the orbit, complaining about facial pain in the trajectory of the trigeminal ophthalmic branch. Schwannomas represent 1 to 2% of all neoplasms of the orbit, and trigeminal schwannomas are extremely rare, accounting for less than 0.5% of all intracranial tumors.

Keywords
- schwannoma
- orbital schwannoma
- ophthalmic schwannoma
- endoscopic transsphenoidal neurosurgery
- subciliary approach

Resumo

Schwannomas são a quarta neoplasia primária mais comum que afeta o cérebro e os nervos cranianos. As lesões centrais comumente surgem de raízes nervosas sensitivas, e um sítio intracraniano comum é o ramo vestibular do oitavo nervo (mais de 85% dos casos). Apresentamos o relato de caso de um paciente portador de schwannoma que se estende da fossa pterigopalatina até a órbita, com queixa de dor facial no trajeto do ramo oftálmico do nervo trigêmeo. Schwannomas representam 1–2% de todas as neoplasias da órbita e schwannomas trigeminais são extremamente raros, respondendo por menos de 0,5% de todos os tumores intracranianos.

Palavras-chave
- schwannoma
- schwannoma orbital
- schwannoma oftálmico
- neurocirurgia endoscópica Transesfenoidal
- abordagem subciliar

received May 8, 2020
accepted August 4, 2020
published online October 16, 2020

DOI https://doi.org/10.1055/s-0040-1718421.
ISSN 0103-5355.

Thieme Revinter Publicações Ltda., Rua do Matoso 170, Rio de Janeiro, RJ, CEP 20270-135, Brazil

Introduction

Schwannomas are the fourth most common primary neoplasms affecting the brain and cranial nerves. Central lesions commonly arise from sensory nerve roots, and a common intracranial site is the vestibular branch of the eighth nerve (> 85% of central schwannomas and 8–10% of all intracranial tumors.).[1–4] We present the case report of a patient who has a schwannoma extending from the pterygopalatine fossa to the orbit, complaining about facial pain in the trajectory of the trigeminal ophthalmic branch. Primary orbital tumors are very rare, with an overall incidence < 1 per 100,000/year;[5] schwannomas represent 1 to 2% of all neoplasms of the orbit,[4,6] and trigeminal schwannomas are extremely rare, accounting for 0.07 to 0.3% of all intracranial tumors.[7,8] The patient usually presents with facial pain, numbness, and paresthesia in the distribution of one or all the divisions of the trigeminal nerve depending on the location of the tumor.[7,9,10] Magnetic resonance imaging (MRI) is the gold standard for evaluation because of its multiplanar capabilities and better soft-tissue contrast, being useful for planning the surgical approach.[7,9]

Case Report

A 56-year-old female, diabetic, hypertense, who had a hemorrhagic stroke 7 years ago, sought the emergency service complaining about left hemicranial progressive headache, for 3 years. Neurological exam at the admission showed right spastic hemiparesis, Medical Research Council (MRC) grade III, right hyperreflexia and Wernicke-Mann posture. The patient underwent an MRI, which showed an expansive formation involving the left pterygopalatine fossa and the sphenoid bone, heterogeneously enhanced by gadolinium in T1 sequence, extending to the extraconal lateral region of the left orbit, with a rounded aspect measuring 1.9 cm in its largest diameter, hyperintense in T2 and without impregnation by gadolinium (►**Fig. 1**). The patient underwent a transsphenoidal surgery using an endonasal endoscopic

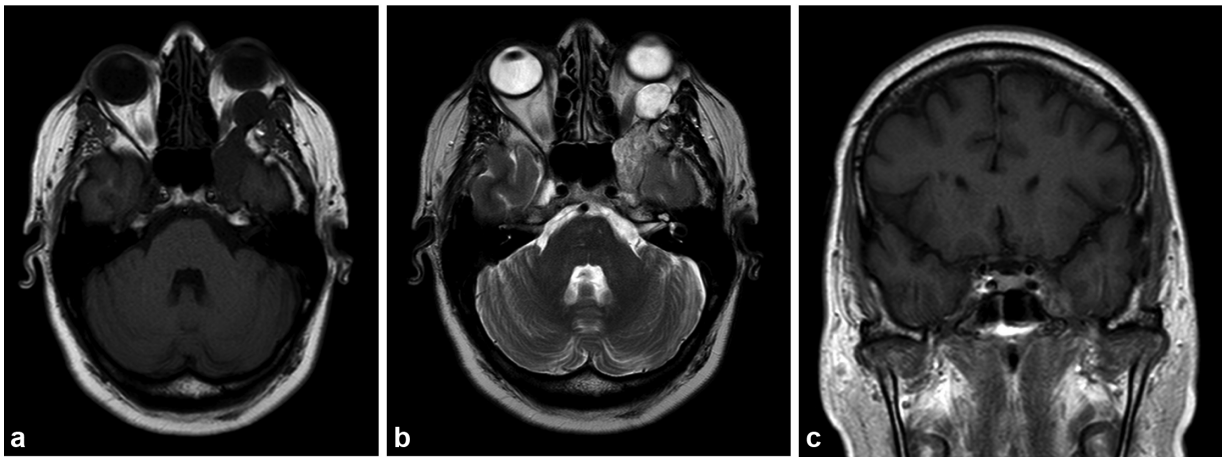

Fig. 1 Preoperative images. (**a**) Axial T1-weighted gadolinium-enhanced image with a rounded aspect measuring 1.9 cm in its largest diameter, without impregnation by the gadolinium. (**b**) Axial T2-weighted image, showing a hyperintense lesion. (**c**) Coronal T1-weighted gadolinium-enhanced image.

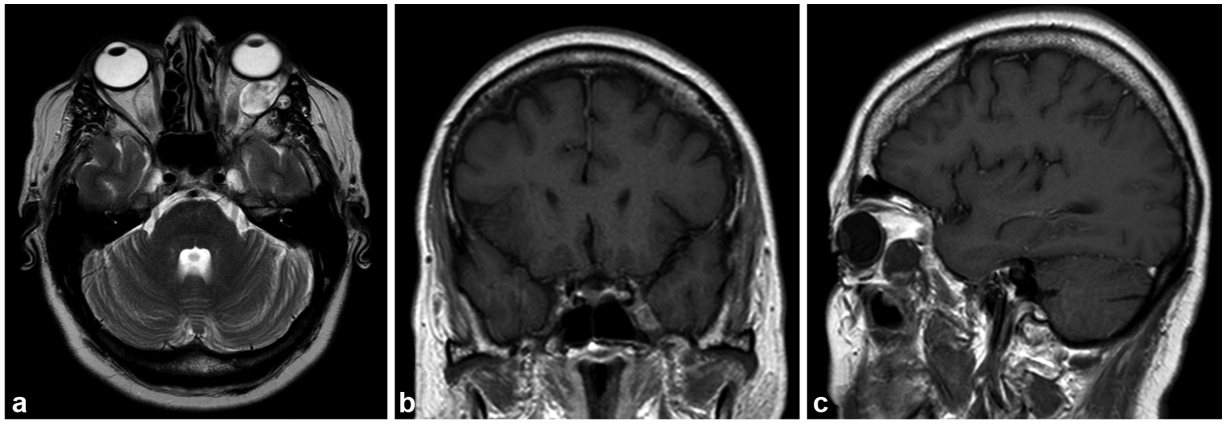

Fig. 2 Postoperative images, after the first surgery. Magnetic resonance imaging still shows an orbital lesion. (**a**) Axial T2-weighted image, still showing the hyperintense lesion in the extraconal lateral region of the left orbit. (**b**) Coronal T1-weighted gadolinium-enhanced image, showing the resection performed in the first surgery. (**c**) Sagittal T1-weighted gadolinium-enhanced image from tumor, measuring 1.9 cm in its largest diameter, without impregnation by the gadolinium.

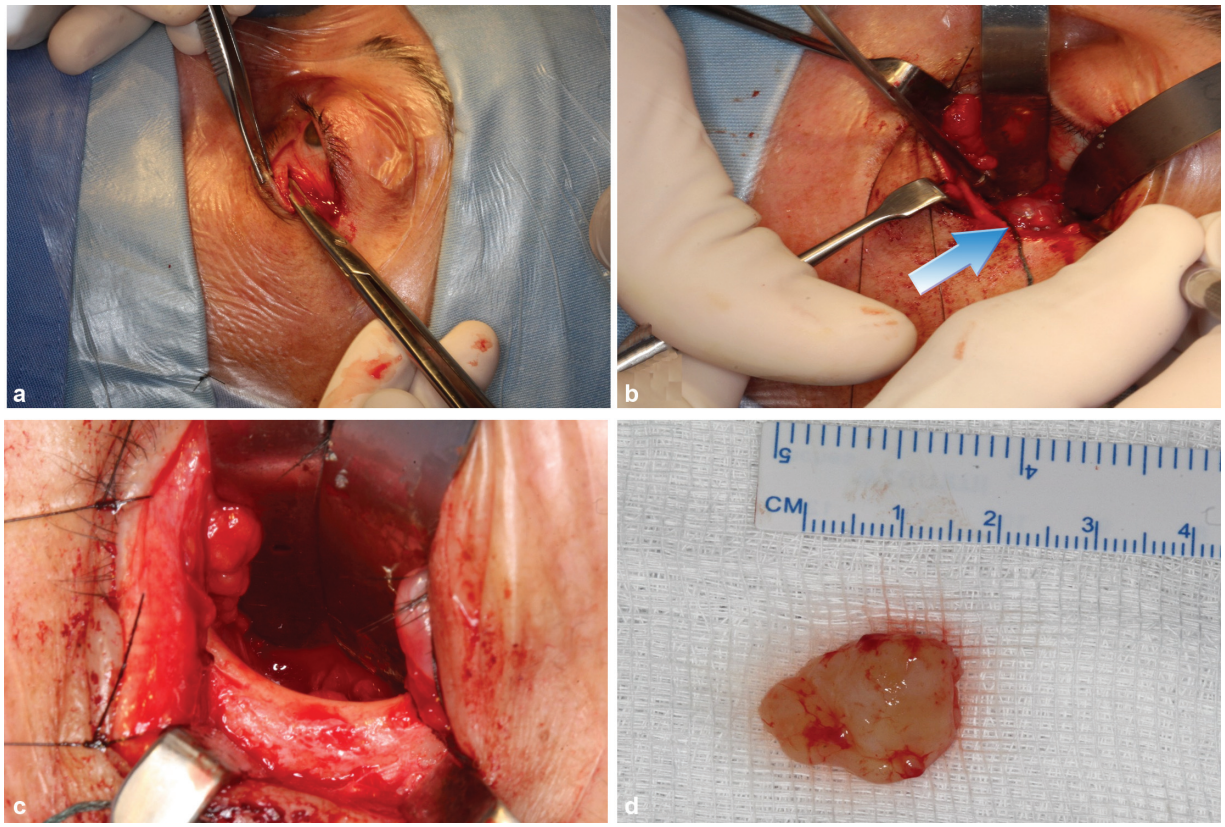

Fig. 3 Intraoperative images, from the second surgical procedure for resection of the orbital portion of the tumor. (**a**) Transconjunctival approach. (**b**) Lesion exposure (blue arrow) with partial resection (**c**) Revision of the tumor cavity evidencing complete resection of the tumor. (**d**) Surgical specimen measuring 1.8 cm × 1.2 cm × 0.5 cm.

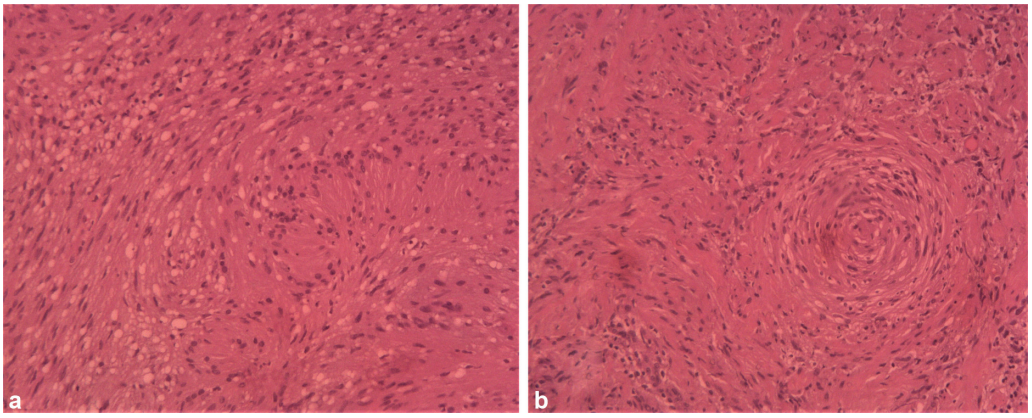

Fig. 4 Second histopathological examination, also conclusive for schwannoma. (**a**) Hematoxylin & Eosin stain (5x) – neoplasia consisting of fusocellular cells, Antoni A and Antoni B areas. (**b**) Hematoxylin & Eosin stain (10x) – neoplasia consisting of fusocellular and monomorphic cells, without atypia and without presence of mitosis.

approach for total resection of the sphenoidal portion of this lesion. The histopathologic examination was conclusive for schwannoma. The postoperative MRI showed the total resection of this portion, leaving just the orbital portion (►**Fig. 2**). After 2 years, the patient started to complain about pain in the trajectory of the ophthalmic branch of the trigeminal root and was submitted to a transconjunctival approach for resection of the orbital lesion, combined with an orbital reconstruction (►**Fig. 3**). The histopathologic examination was also conclusive for schwannoma (►**Fig. 4**). After this procedure, the patient became asymptomatic, with no referred facial pain, and without new deficits.

Discussion

According to the 2016 World Health Organization Classification of Tumors of the Central Nervous System, schwannomas include cellular, plexiform, and melanotic schwannomas, neurofibromas, perineuriomas, hybrid nerve sheath tumors

and malignant peripheral nerve sheath tumors.[11] They affect adults in the 3rd to the 7th decades of life[12] but are more commonly found in patients in their 4th decade, without sex predilection.[13] This type of tumor comprises the fourth most common primary neoplasm affecting the brain and cranial nerves.[14] The majority (~ 90%) of cranial nerve schwannomas arise from the vestibulocochlear nerve, with the next most commonly involved nerves being the trigeminal and facial nerves, followed by the lower cranial nerves.[15] The orbital nerves more commonly involved are the supratrochlear and supraorbital nerves.[16]

Schwannomas constitute 1 to 8% of all head and neck tumors.[17] When intraorbital, it is a rare tumor that accounts for ~ 1 to 2% of all neoplasms of the orbit.[4,6] They are known to originate from sympathetic and parasympathetic fibers, as well as from branches of the oculomotor, trochlear, trigeminal, and abducens nerves, with the ophthalmic division of the trigeminal nerve being the most common.[18] Trigeminal schwannomas are particularly rare, accounting for 0.07 to 0.3% of all intracranial tumors and 0.8 to 5% of intracranial schwannomas. Orbital schwannomas, most commonly, arise from the sensory branches of the trigeminal nerve.[4] They may arise from the cisternal segment (most commonly), the trigeminal/Gasserian ganglion in Meckel's cave, or from one of the three branches of the nerve. They tend to occur predominantly in the 4th to 6th decades of life and are slightly more common in females.[7] The oculomotor, ciliary, lacrimal, and zygomaticotemporal nerves have been reported as the nerves that the orbital schwannomas most commonly arise from.[17] The frontal nerve, in particular, is frequently affected due to the predominance of sensory nerve branches, namely the supraorbital and supratrochlear nerve.[17,18] Based on the work of Erdogmus et al, Irace et al proposed that the entry point of nerve fibers in the muscle (e.g., area nervosa or myoneural junction) is the zone where intraorbital schwannomas truly arise.[4] Motor root and sympathetic chain involvement is uncommon, and involvement of the brain or cord parenchyma is rare.[1] Also, it is unusual for orbital schwannomas to arise from extraocular muscles, with only a few reports in the literature to date.[12]

Schwannomas are benign tumors consisting of a clonal population of Schwann cells, which often undergo cystic and degenerative change.[1] They originate in a zone of transition of peripheral central myelin (Obersteiner-Redlich zone)[19] and are usually isolated, solitary, slow-growing, and well-encapsulated lesions, except when they are associated with neurofibromatosis. In the latter case, the patients can develop multiple schwannomas, in which case the condition is termed schwannomatosis.[13] Persons with neurofibromatosis type 2 characteristically develop bilateral vestibular schwannomas, but approximately half of them also have nonvestibular schwannomas, which most commonly involve the oculomotor and trigeminal nerves.[15] Although hereditary disorders predispose to nerve sheath tumors, the specific etiologies of schwannoma remain unknown. However, sporadic reports have suggested an association of formation of schwannomas with previous events of trauma.[13] Postradiation schwannomas, including acoustic schwannomas, appear with a latency of up to 50 years following treatment.[1] Besides, they are generally known to be slow-growing, benign masses. There have been clinical reports of rapidly growing schwannomas in pregnant women, attributed to progesterone receptors or intratumoral hemorrhage.[12]

When the imaging features and clinical signs are compatible with schwannoma, the presence of end organ compromise, such as denervation-induced muscle atrophy or sensory deficit, may aid in the identification of the cranial nerve (CN) of origin.[15] Since most of the tumors originate from the sensory nerves, they do not interfere with the eye movements or vision unless they are located in the orbital apex or compress the optic nerve.[17] Clinically, trigeminal schwannomas usually present with facial pain, numbness, and paresthesia in the distribution of one or all the divisions of the trigeminal nerve depending on the location of the tumor,[7,9,10] what seems to fit in our case report. Headache and diplopia can also be present.[20] Long-standing tumors may also present with motor symptoms like difficulty in chewing and deviation of the jaw.[7] Yoshida and Kawase showed 6.3% of asymptomatic patients (found incidentally).[21]

Both MR and CT images show evidence of the slow growth of schwannomas, including smooth expansion of the neural foramina, osseous remodeling, and/or deformation of adjacent brain tissue, with a disproportionately small amount of edema, given the size of the lesion.[15] Schwannomas have a characteristic appearance on MR imaging: on T2-weighted images, schwannomas appear heterogeneously hyperintense.[4,15,22,23] This heterogeneity is attributed to regions of compactly arranged cells (Antoni type A) mixed with regions of loosely arranged cells (Antoni type B), with variable cellularity and water content.[15] Usually, the central enhancement seems to represent the presence of hypercellular Antoni A-type cells in the central part of the tumor and hypocellular Antoni B-type cells in the periphery.[24] On T1-weighted images, these lesions have low or intermediate signal intensity and demonstrate avid enhancement after contrast material administration, with or without nonenhancing cystic spaces. Larger lesions commonly have heterogeneous enhancement, cystic spaces, and foci of hemosiderin due to internal hemorrhage.[15] On CT scan, they usually appear as uniformly enhancing masses with remodeling of the adjacent bone.[7,10]

Several classification systems have been proposed for a systematic approach in selecting the optimal surgical strategy. The most apt system was proposed by Wanibuchi et al based on 4 anatomical categories of tumor: peripheral, ganglion, root, and dumbbell. The peripheral type refers to tumor along V1 in the orbit, V2 in the pterygopalatine fossa (PPF) and maxilla, and V3 into the infratemporal fossa.[20,25] The Gasserian ganglion was the most frequent site described by Wanibuchi et al, and the most common type of extracranial extension (possibly corresponding peripheral or dumbbell by this classification) was from the third division described by Goel et al.[20,26]

Standard treatment for schwannomas consists of complete surgical resection, whereas subtotal resection is linked to an increased risk of recurrence,[25] which could reach 13-

fold higher.[23,27] Nevertheless, total tumor removal is not always feasible without neurological complications. In this circumstance, stereotactic radiation technique has emerged as an alternative treatment to surgical resection.[25,28] This has been shown to provide 5-year progression-free survival of 95% in selected patients.[25] With improvement of advanced surgical technique, total tumor removal is accomplished in 40 to 80% (Sharma et al, 2008; Zhang et al, 2009) of the cases, with tumor control rate of 81 to 100% (Lee et al, 2001; Al-Mefty et al, 2002; Goel et al, 2003; Kadri et al, 2004; Bulsara et al, 2008).[28] Surgical resection is also the best treatment for orbital schwannomas. Subciliary approach is the most preferred method for the masses inferior and medial to the optic nerve.[17] To access the medial inferior quadrant of the orbit, one option is endoscopic access, which is less invasive than the transcranial route. For small lesions located in the anterior half of the orbit, approaches without osteotomies, like eyelid superiorly or subciliary and orbital rim inferiorly can be tried, but anterior approaches give a restricted vision field, which promotes difficulties in locating and preserve the anatomical structures.[2,5,29]

Even so, the surgical approach must be determined case by case. Raza et al showed results suggesting that endoscopic transpterygoid approaches can help to achieve optimal resection rates with limited CN morbidity for tumors isolated to the Meckel's cave, with combined Meckel's cave peripheral extension, or primarily extracranial in location. According the Raza et al[25], endoscopic transpterygoid approaches provide safe access to Meckel's cave and disease extending along V2 into the Pterygopalatine fossa (PPF) and V3 into the infratemporal fossa without risking additional CN morbidity.[25] When complete resection is not possible, adjuvant radiotherapy can be considered.[2] The authors also reported significant rates of dry eye and corneal neurotrophic keratopathy that should be considered in those patients with either preoperative V1 neuropathy or tumor extending along this division. The presumed mechanism of these complications would be attributable to either vidian nerve injury (if the vidian is transected) or a V1 neuropathy. While an endoscopic transpterygoid approach to Meckel's cave is typically supravidian and does not require the nerve's sacrifice, transposition of the PPF contents could theoretically result in vidian nerve injury.[25] Pain ($>$ 90% of the patients), dysesthesia, and diplopia may be relieved after surgery; however, hypesthesia frequently remains or may be worsened by surgery.[20]

Conclusion

Schwannomas are benign and highly treatable lesions. When trigeminal, from the ophthalmic branch, they are extremely rare lesions, usually obeying the symptomatology of the nerve path. The approach should be individualized according to the morphology of the lesions and nerve involvement, always looking for total resection or subtotal in association with radiation therapy.

Conflict of Interests

The authors declare that there is no conflict of interests.

References

1 Hilton DA, Hanemann CO. Schwannomas and their pathogenesis. Brain Pathol 2014;24(03):205–220. Doi: 10.1111/bpa.12125
2 Caramanti RL, Goes MJ, Chaddad F, et al. Orbital Schwannoma: Case Report and Review. Arq Bras Neurocir Brazilian Neurosurg. 2019:10–13. Doi: 10.1055/s-0039-1693683
3 Mahore A, Ramdasi R, Chagla A, Tikeykar V. Intraconal optic sheath schwannoma: report of two cases. Br J Neurosurg 2019; 33(01):101–103
4 Iida Y, Sakata K, Kobayashi N, Tatezuki J, Manaka H, Kawasaki T. Orbital Abducens Nerve Schwannoma: A Case Report and Review of the Literature. NMC Case Rep J 2016;3(04):107–109. Doi: 10.2176/nmccrj.cr.2015-0259
5 Montano N, Lauretti L, D'Alessandris QG, et al. Orbital Tumors: Report of 70 Surgically Treated Cases. World Neurosurg 2018; 119:e449–e458. Doi: 10.1016/j.wneu.2018.07.181
6 Wang Y, Xiao LH. Orbital schwannomas: findings from magnetic resonance imaging in 62 cases. Eye (Lond) 2008;22(08):1034–1039. Doi: 10.1038/sj.eye.6702832
7 Agarwal A. Intracranial trigeminal schwannoma. Neuroradiol J 2015;28(01):36–41. Doi: 10.15274/NRJ-2014-10117
8 Pollack IF, Sekhar LN, Jannetta PJ, Janecka IP. Neurilemomas of the trigeminal nerve. J Neurosurg 1989;70(05):737–745. Doi: 10.3171/jns.1989.70.5.0737
9 Borges A, Casselman J. Imaging the trigeminal nerve. Eur J Radiol 2010;74(02):323–340. Doi: 10.1016/j.ejrad.2010.02.006
10 Bathla G, Hegde AN. The trigeminal nerve: an illustrated review of its imaging anatomy and pathology. Clin Radiol 2013;68(02): 203–213. Doi: 10.1016/j.crad.2012.05.019
11 Louis DN, Perry A, Reifenberger G, et al. The 2016 World Health Organization Classification of Tumors of the Central Nervous System: a summary. Acta Neuropathol 2016;131(06):803–820. Doi: 10.1007/s00401-016-1545-1
12 Young SM, Kim YD, Hwang SS, Woo KI. Orbital Schwannoma With Atypical Presentation. J Craniofac Surg 2018;29(03):e224–e226. Doi: 10.1097/SCS.0000000000004177
13 Albert P, Patel J, Badawy K, et al. Peripheral Nerve Schwannoma: A Review of Varying Clinical Presentations and Imaging Findings. J Foot Ankle Surg 2017;56(03):632–637. Doi: 10.1053/j.jfas.2016.12.003
14 Strowd RE III, Blakeley JO. Common Histologically Benign Tumors of the Brain. Continuum (Minneap Minn) 2017;23(06Neuro-oncology1680–1708. Doi: 10.1212/CON.0000000000000541
15 Skolnik AD, Loevner LA, Sampathu DM, et al. Cranial Nerve Schwannomas: Diagnostic Imaging Approach. Radiographics 2016;36(05):1463–1477. Doi: 10.1148/rg.2016150199
16 Kim KS, Jung JW, Yoon KC, Kwon YJ, Hwang JH, Lee SY. Schwannoma of the Orbit. Arch Craniofac Surg 2015;16(02):67–72. Doi: 10.7181/acfs.2015.16.2.67
17 Tezer MS, Ozcan M, Han O, Unal A, Ozlugedik S. Schwannoma originating from the infraorbital nerve: a case report. Auris Nasus Larynx 2006;33(03):343–345. Doi: 10.1016/j.anl.2005.11.015
18 Young SM, Kim YD, Jeon GS, Woo KI. Orbital Frontal Nerve Schwannoma-Distinctive Radiological Features. Am J Ophthalmol 2018;186:41–46. Doi: 10.1016/j.ajo.2017.11.012
19 Madrid-Sánchez AJ, Castillo-Rangel C, Contreras-Ayala ML, Ruiz-García E, Castillo-Castro AK, Ramírez-Aguilar R. Schwannoma trigeminal maxilar. Presentación de un caso y revisión de la literatura. Cir y Cir (English Ed) 2017;85(01):49–52. Doi: 10.1016/j.circir.2016.11.008
20 MacNally SP, Rutherford SA, Ramsden RT, Evans DG, King AT. Trigeminal schwannomas. Br J Neurosurg 2008;22(06):729–738. Doi: 10.1080/02688690802272172
21 Yoshida K, Kawase T. Trigeminal neurinomas extending into multiple fossae: surgical methods and review of the literature. J Neurosurg 1999;91(02):202–211. Doi: 10.3171/jns.1999.91.2.0202
22 Xu F, Pan S, Alonso F, Dekker SE, Bambakidis NC. Intracranial Facial Nerve Schwannomas: Current Management and Review of

Literature. World Neurosurg 2017;100:444–449. Doi: 10.1016/j.wneu.2016.09.082
23 Petersen J, Gilain L, Coutu A, Saroul N. Frontal sinus schwannoma. Eur Ann Otorhinolaryngol Head Neck Dis 2018;135(03):213–215. Doi: 10.1016/j.anorl.2018.03.001
24 Karaman İ, Öner M, Kafadar IH, Güney A, Argun M. Surgical excision of peripheral nerve schwannomas: analysis of 11 patients. Acta Orthop Traumatol Turc 2015;49(02):139–143. Doi: 10.3944/AOTT.2015.14.0119
25 Raza SM, Donaldson AM, Mehta A, Tsiouris AJ, Anand VK, Schwartz TH. Surgical management of trigeminal schwannomas: defining the role for endoscopic endonasal approaches. Neurosurg Focus 2014;37(04):E17. Doi: 10.3171/2014.7.FOCUS14341
26 Goel A, Shah A, Muzumdar D, Nadkarni T, Chagla A. Trigeminal neurinomas with extracranial extension: analysis of 28 surgically treated cases. J Neurosurg 2010;113(05):1079–1084. Doi: 10.3171/2009.10.JNS091149
27 Jacob JT, Carlson ML, Driscoll CL, Link MJ. Volumetric analysis of tumor control following subtotal and near-total resection of vestibular schwannoma. Laryngoscope 2016;126(08):1877–1882. Doi: 10.1002/lary.25779
28 Puataweepong P, Dhanachai M, Hansasuta A, et al. Clinical outcomes of intracranial nonvestibular schwannomas treated with linac-based stereotactic radiosurgery and radiotherapy. Asian Pac J Cancer Prev 2016;17(07):3271–3276. Doi: 10.1093/jrr/rrt235
29 Bachelet JT, Shipkov H, Breton P, Berhouma M, Jouanneau E, Gleizal A. [Surgical approaches of tumors of the posterior cone of the orbit]. Rev Stomatol Chir Maxillofac Chir Orale 2016;117(02):89–95. Doi: 10.1016/j.revsto.2016.01.005

An Unusual Dermoid Cyst of the Pineal Region: Case report in a Child

Cisto dermóide incomum da região da pineal: Relato de caso em uma criança

Mohammad Jamali[1] Iman Ahrari[1] Arash Saffarrian[1] Keyvan Eghbal[1] Abbas Rakhsha[1] Sulmaz Ghahramani[2]

[1] Department of Neurosurgery, Shiraz University of Medical Sciences, Shiraz, Iran
[2] Health Policy Research Center, Institute of Health, Shiraz University of Medical Sciences, Shiraz, Iran

Address for correspondence Sulmaz Ghahramani, MD, Shiraz University of Medical Sciences, Shiraz, Iran (e-mail: suli.ghahraman@gmail.com).

Arq Bras Neurocir 2021;40(1):97–100.

Abstract

Introduction The pineal gland is a common location for intracranial germ cells, but dermoids are not commonly observed in this area. In the present paper, we discuss the clinical and radiological features as well as the treatment and outcome of this cyst in a 6-year- old child with a pineal dermoid cyst.

Case Presentation The patient presented with chronic headache 6 months before admission in 2018. On the first admission, an enhanced lesion with a small cyst was detected in brain imaging. Magnetic resonance imaging (MRI) of the brain at follow-up (2 months after the first presentation) showed enlargement of the cyst size with compression on the adjacent structures. Radical excision of the tumor was performed after the endoscopic biopsy due to pressure exerted on the adjacent structures.

Conclusion Dermoid cyst should be considered as a differential diagnosis for enhanced lesions of the pineal region.

Keywords
- dermoid cyst
- pineal tumor
- hydrocephalus
- hairy structure

Resumo

Introdução A glândula pineal é uma localização comum para as células germinativas intracranianos, mas dermoids não são frequentemente observados nesta área. No presente artigo, discutimos as características clínicas e radiológicas, bem como o tratamento e a evolução desse cisto em uma criança de 6 anos com cisto dermóide pineal.

Apresentação do caso O paciente apresentou cefaleia crônica 6 meses antes da admissão em 2018. Na primeira admissão, uma lesão acentuada com um pequeno cisto foi detectada na imagem do cérebro. A ressonância magnética (RM) do cérebro no seguimento (2 meses após a primeira apresentação) mostrou aumento do tamanho do cisto com compressão das estruturas adjacentes. A excisão radical do tumor foi realizada após a biópsia endoscópica devido à pressão exercida nas estruturas adjacentes.

Conclusão O cisto dermóide deve ser considerado um diagnóstico diferencial para lesões acentuadas da região pineal.

Palavras-chave
- cisto dermoide
- tumores da região pineal
- hidrocefalia
- estrutura cabeluda

received July 21, 2020
accepted September 4, 2020
published online November 26, 2020

DOI https://doi.org/10.1055/s-0040-1719006.
ISSN 0103-5355.

Thieme Revinter Publicações Ltda., Rua do Matoso 170, Rio de Janeiro, RJ, CEP 20270-135, Brazil

Introduction

Dermoid cysts (benign congenital cysts) account for 0.1% to 0.7% of embryonal malformations, and arise from defects in the separation of the neuroectoderm during the neural tube formation. This leads to sequestration of ectodermal remnants.[1,2] It can arise in the posterior fossa, mostly in the midline position in the vermis, in nearby meninges or in the cavity of the 4th ventricle.[3–6] Although the pineal gland is a common location for intracranial germ cells and epidermoids (∼ 40–50%), dermoids are not commonly observed in this area.[7,8]

Patients with dermoid cysts are usually asymptomatic, although they may present symptoms related to local mass effect, seizures, or recurrent meningitis.[9] On computed tomography (CT) scans, dermoid cysts usually appear as rounded, well-circumscribed, non-enhancing, hypodense lesions. Moreover, on magnetic resonance images (MRI), they demonstrate increased T1- and variable T2-weighted signal.[10,11]

In the present paper, we discuss the clinical and radiological features, as well as the treatment and outcome of this cyst in a 6-year old child with a pineal dermoid cyst.

Case Presentation

The patient was a 6-year-old boy who presented with chronic headache 6 months before admission in 2018. His past medical and family histories were unremarkable for any childhood illnesses, malignancies or fetomaternal complications. Moreover, no documented developmental delays were observed in the patient and papilledema was found in his neurological examination. In addition, routine laboratory tests and markers of germ cell tumors were checked, and all were within normal limits.

Imaging. Brain MRI was performed with and without intravenous Gadolinium Contrast Medium (Gd), showing a well-defined extra axial 1×2 cm T1W hypointense, T2W hyperintense solid-cystic lesion and enhancement with contrast; the midline in the.cystic component of the pineal region was very small. Moreover, no significant pressure was observed on the adjacent structures (►**Fig. 1**).

Operation and Outpatient follow-up. In the first admission, the patient presented with drowsiness and headache. Due to the presence of hydrocephalus and nonprepared endoscopic setting at the admission time, a ventriculoperitoneal (VP) shunt was inserted. In the same admission, a brain MRI was performed. Assessment of tumor markers including Beta-Human Chorionic Gonadotropin (β-HCG) and Alpha Fetoprotein (AFP) was negative for germ cell tumor. Due to the improvement of his condition, the patient was discharged. Two months after the first presentation, the patient developed ataxia and upgaze palsy. A subsequent brain MRI revealed enlargement of the cystic lesion behind the solid mass with compressive effects on the adjacent structures and unilateral hydrocephalus.

An endoscopic transventricular approach was performed for biopsy. The endoscopic view revealed hair-like structures on both the outer surface of the cyst and the in solid lesion, in favor of a dermoid cyst (►**Fig. 2**). Histopathologic studies confirmed the diagnosis of dermoid cyst. A brain MRI showed enlargement of the cyst size with compression on the adjacent structures. Open surgery was performed using the infratentorial-supracerebellar approach for total resection of the lesion (►**Fig. 2**).

Histopathology: The histopathologic study of the specimens from both the first and second operations was in favor of the dermoid cyst (►**Fig. 3**).

Hospital course: Postoperatively, the neurological status of the patient was stable, but the upgaze palsy persisted. Follow-up: after 2 months, the patient was visited and showed reduced upgaze palsy. Moreover, he demonstrated no signs and symptoms of high intracranial pressure.

Discussion

The present study aimed to present a 6-year-old boy with a dermoid cyst of the pineal region. However, it is evident that epidermoid and dermoid cysts are well-differentiated benign cysts that may be rarely observed in the pineal region. Considering the inaccessibility of the pineal region, distinguishing benign, surgically resectable tumors such as teratomas as well as epidermoid and dermoid cysts from malignant ones is of utmost importance.[12]

The patient presented with headache, although most of the intracranial dermoid cysts are asymptomatic and are usually found incidentally. The clinical presentation is limited to vague symptoms, such as headache. Mass effects or rupture of the cyst may cause sudden clinical findings.[2,9]

The advent of CT scans and, more recently, of MRI, has facilitated the diagnosis of pineal-origin lesions. On CT scanning, dermoid cysts are shown as low-density lobulated masses with correspondent peripheral calcifications. Hyperdensity might rarely be demonstrated, due to a combination of saponification, microcalcification, and blood products. Although dermoid cysts may show variable signal characteristics on MRI in T1, they are typically hyperintense due to cholesterol components and usually do not enhance with Gd. However, extensive pial contrast enhancement may be present in chemical meningitis caused by ruptured cysts. On T2, various signals ranging from hypo- to hyperintense may be observed.[10,13] The brain MRI in this case is mystifying. In T1-weighted images, the mass is hypointense with enhancement of Gd.

The key point for surgical treatment of cysts is their radical excision. However, it is a challenging approach because it requires localization. In a reported series of epidermoid cysts, in some cases, the surgeon preferred to intentionally leave in situ fragments of the adherent capsule to the deep veins of this region to avoid any risk.[14,15] Operation approaches are more studied on epidermoid cysts than in dermoid cysts, considering their higher prevalence.[14]

The prognosis of patients with dermoid cysts appears appropriate after resection.[9] In this case, the 4- and 8-month outcome after total resection is favorable.

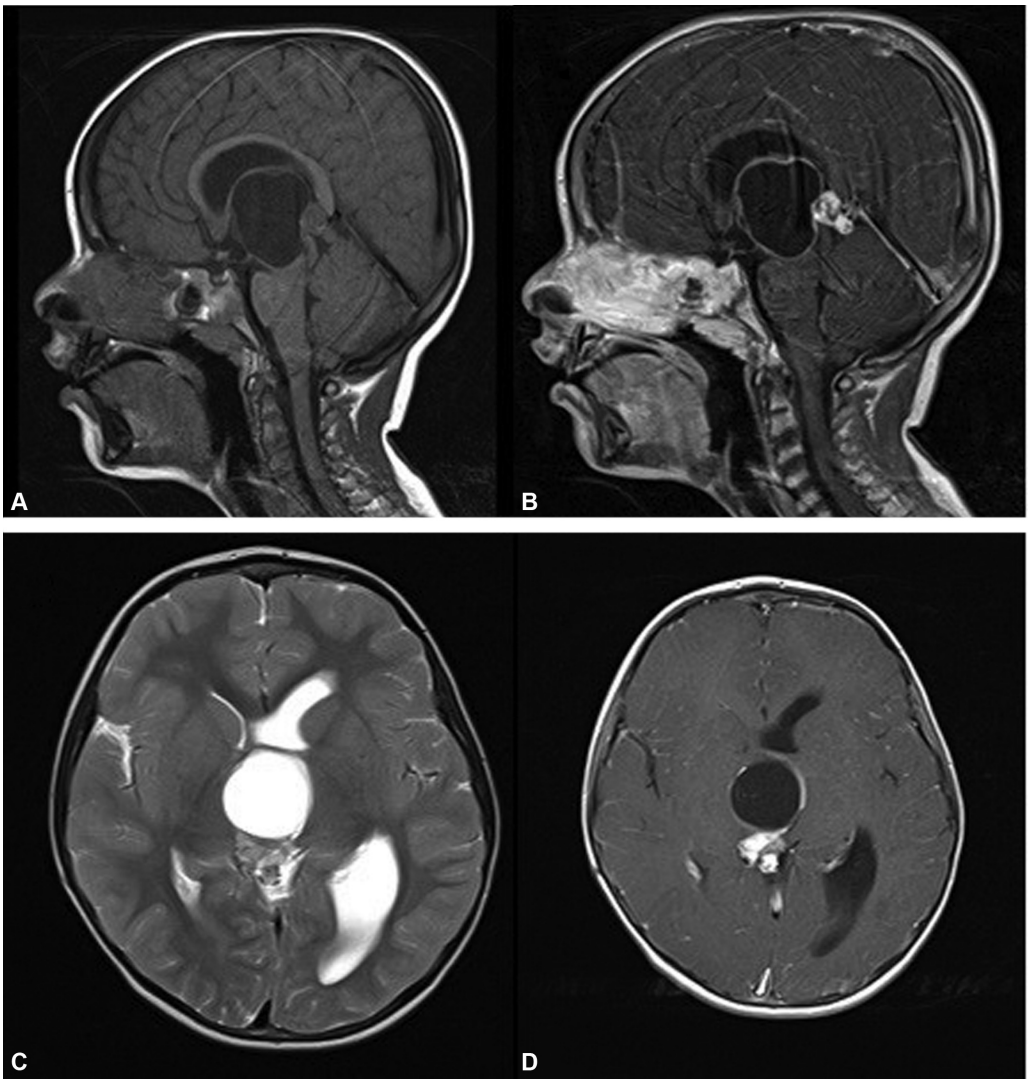

Fig. 1 Sequences of the lesion on performing magnetic resonance imaging showing low signal intensity on T1-weighted images (**A**) and heterogeneously high signal intensity on T2-weighted images (**B**) and enhancement after injection of intravenous contrast (**C, D**).

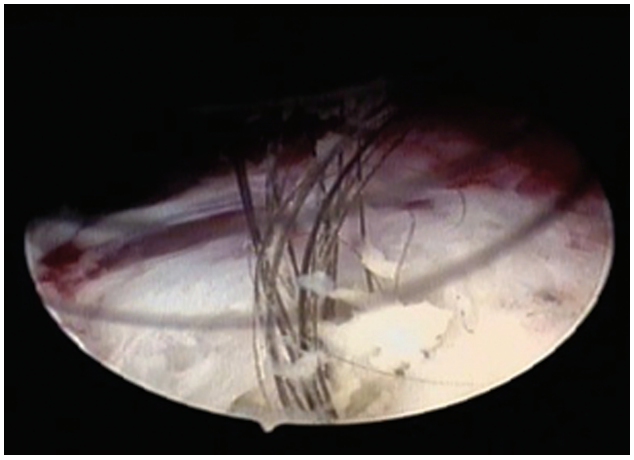

Fig. 2 Intraoperative gross appearance of cystic lesion with hair tissue.

In the present study, a case was presented with a pineal lesion surrounded by a huge cyst. Brain MRI of the case was not typical. A previous presentation of a dermoid cyst was reported in the posterior fossa, suprasellar and auricular areas.[9] However, emergence of a dermoid cyst in the pineal region is unusual, but it is always on a differential that a tumor of the pineal region may be a epidermoid or dermoid.[16] For the case, emergency VP shunting was performed due to hydrocephalus, and the endoscopic approach was used to drain the cyst and take biopsies from the lesion. Moreover, the total resection method was selected for the case due to the pressure effect of the lesion on the surrounding structures. The cyst was totally excised with no damage to the adjacent structures.

Conclusion

We reported an unusual case with a dermoid cyst in the pineal region. Radical removal of the cyst was performed after the endoscopic biopsy due to pressure exerted on the adjacent structures. The risk of injury to the cerebellar hemisphere and other structures should be considered.

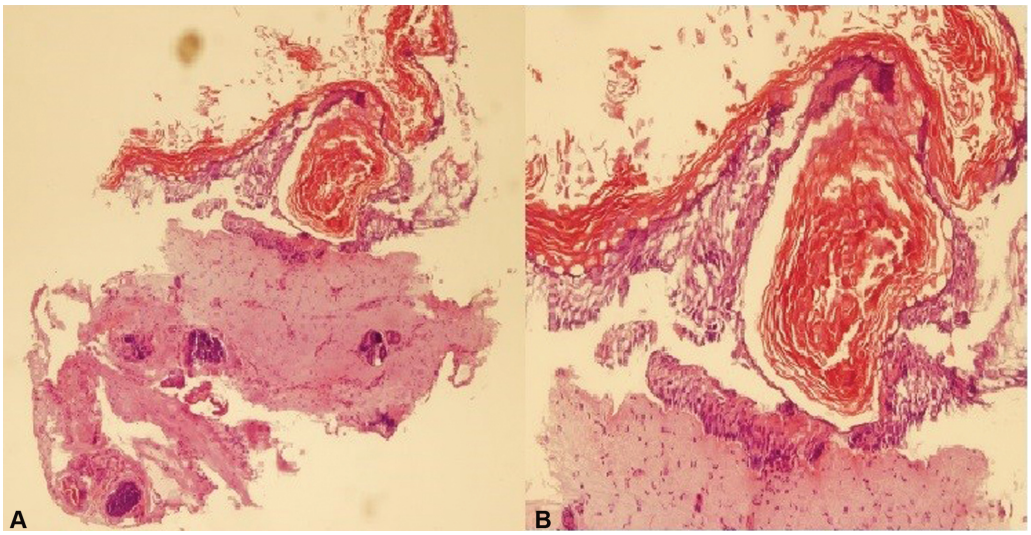

Fig. 3 (**A**) Cystic lesion with a fibrous wall partially lined by stratified epithelium and keratinized components that is consistent with the diagnosis of a dermoid cyst. (**B**) Higher magnification of the area shown in (**A**).

Therefore, we suggest stereotaxic or endoscopic approaches in the case of small lesions.

Conflict of Interests

The authors have no conflict of interests to declare.

References

1 Guidetti B, Gagliardi FM. Epidermoid and dermoid cysts. Clinical evaluation and late surgical results. J Neurosurg 1977;47(01): 12–18
2 Smirniotopoulos JG, Chiechi MV. Teratomas, dermoids, and epidermoids of the head and neck. Radiographics 1995;15(06): 1437–1455
3 Groen RJ, van Ouwerkerk WJ. Cerebellar dermoid tumor and occipital meningocele in a monozygotic twin: clues to the embryogenesis of craniospinal dysraphism. Childs Nerv Syst 1995;11 (07):414–417
4 Higashi S, Takinami K, Yamashita J. Occipital dermal sinus associated with dermoid cyst in the fourth ventricle. AJNR Am J Neuroradiol 1995;16(04):945–948
5 Logue V, Till K. Posterior fossa dermoid cysts with special reference to intracranial infection. J Neurol Neurosurg Psychiatry 1952;15(01):1–12
6 Akhaddar A, Jiddane M, Chakir N, El Hassani R, Moustarchid B, Bellakhdar F. Cerebellar abscesses secondary to occipital dermoid cyst with dermal sinus: case report. Surg Neurol 2002;58(3-4):266–270
7 Jennings MT, Gelman R, Hochberg F. Intracranial germ-cell tumors: natural history and pathogenesis. J Neurosurg 1985;63 (02):155–167
8 Baykaner MK, Ergun E, Cemil B, Bayik P, Emmez H. A mature cystic teratoma in pineal region mimicking parietal encephalocele in a newborn. Childs Nerv Syst 2007;23(05):573–576
9 Kahilogullari G, Yakar F, Bayatli E, Erden E, Meco C, Unlu A. Endoscopic removal of a suprasellar dermoid cyst in a pediatric patient: a case report and review of the literature. Childs Nerv Syst 2018;34(08):1583–1587
10 Brown JY, Morokoff AP, Mitchell PJ, Gonzales MF. Unusual imaging appearance of an intracranial dermoid cyst. AJNR Am J Neuroradiol 2001;22(10):1970–1972
11 Sanchez-Mejia RO, Limbo M, Tihan T, Galvez MG, Woodward MV, Gupta N. Intracranial dermoid cyst mimicking haemorrhage. J Neurosurg 2006;105(04):311
12 Shah A, Sadasivan B, Leng BM, Ho J. A teratocarcinoma developing after gross total excision of a pineal teratoma in a patient with systemic lupus erythematosus. Neurol Res 1995;17(03):229–232
13 Osborn AG, Preece MT. Intracranial cysts: radiologic-pathologic correlation and imaging approach. Radiology 2006;239(03):650–664
14 Hassani FD, Bouchaouch A, El Fatemi N, Gana R, El Abbadi N, Maaqili MR. Pineal epidermoid cyst: case report and review of the literature. Pan Afr Med J 2014;18(01):259
15 Konovalov AN, Spallone A, Pitzkhelauri DI. Pineal epidermoid cysts: diagnosis and management. J Neurosurg 1999;91(03): 370–374
16 Hudgins RJ, Hudgins PA. Pineal Region Tumors in Children. Contemp Neurosurg 1990;12(22):1

Traumatic Atlantoaxial Rotatory Subluxation in Adult: Case Report

Subluxação rotatória atlantoaxial traumática em adulto: Relato de caso

Rafaela Campos Alcântara[1] Jacks Alan Tenório de Souza[2] Andrei Fernandes Joaquim[3]

[1] Universidade Federal de Alagoas, Arapiraca, AL, Brazil
[2] Hospital de Emergência Dr. Daniel Houly, Arapiraca, AL, Brazil
[3] Department of Neurology, Universidade de Campinas (UNICAMP), Campinas, SP, Brazil

Address for correspondence Rafaela Campos Alcântara, School of Medicine, Avenida Manoel Severino Barbosa, Bom Sucesso (Complexo de Ciências Médicas - UFAL), Arapiraca, Al, Brazil (e-mail: rafaela.alcantara@arapiraca.ufal.br).

Arq Bras Neurocir 2021;40(1):101–106.

Abstract

Traumatic atlantoaxial rotatory subluxation (AARS) is generally found in pediatric patients, rarely found in adults, being a life-threatening condition especially when early diagnosis is not possible, which can lead to severe late neurological deficits. We describe a 38-year-old patient, victim of physical aggression caused by strangulation attempt who developed AARS, an uncommon traumatic cause. During the hospital care, the early diagnosis allowed us to institute a conservative treatment, which made the case uncommon, since most of the time surgical treatment is imperative. With the patient awake and under analgesia, a closed reduction was performed that promoted immediate pain relief, followed by a prescription of wearing a Philadelphia-type collar for 8 weeks. During the follow-up, cervical spine radiographies demonstrated no subluxation after removing the cervical collar. The patient was asymptomatic after 6 months of treatment. This case supports the importance of nonoperative management of AARS in selected cases.

Keywords
- atlantoaxial rotatory subluxation
- trauma
- adult

Resumo

A subluxação rotatória atlantoaxial (SRAA) é geralmente encontrada em pacientes pediátricos, sendo em adultos uma condição muito rara, ameaçadora à vida e que, quando não diagnosticada precocemente, pode levar a grave deterioração neurológica tardia. Descrevemos um caso de uma paciente de 38 anos, vítima de agressão física por tentativa de estrangulamento que desenvolveu uma SRAA, uma causa traumática incomum. No atendimento hospitalar, o diagnóstico precoce permitiu que o tratamento conservador fosse instituído, o que tornou o caso incomum, uma vez que, na maioria das vezes, o tratamento cirúrgico é imperativo. Com a paciente acordada e sob analgesia, foi realizada uma redução fechada que promoveu alívio imediato da dor, com prescrição de uso de colar tipo Philadelphia por 8 semanas. No seguimento, radiografias da coluna cervical não evidenciaram luxação após a retirada do colar, com manutenção da estabilidade. Em acompanhamento ambulatorial, a paciente permaneceu sem sintomas após 6 meses de seguimento. Este caso demonstra o sucesso do tratamento não cirúrgico em SRAA em adultos, que pode ser empregado em casos selecionados.

Palavras-Chave
- subluxação rotatória atlantoaxial
- trauma
- adulto

received
May 25, 2020
accepted
September 4, 2020
published online
November 26, 2020

DOI https://doi.org/10.1055/s-0040-1719007.
ISSN 0103-5355.

Thieme Revinter Publicações Ltda., Rua do Matoso 170, Rio de Janeiro, RJ, CEP 20270-135, Brazil

Introduction

The atlantoaxial joint comprehends the two first cervical vertebrae, also called atlas and axis, which are the central spot that supports the movements, mainly the rotation, in the craniovertebral junction[1] area.

Atlantoaxial rotatory subluxation (AARS) in adults is a rare condition that, if not treated, might threaten the life of the patient. It commonly occurs in children between 0 and 18 months old and can usually be observed in a C1-C2 pre-existent instability context, such as rheumatoid arthritis, Down syndrome and a variety of congenital cervical abnormalities.[2]

Cervical spine trauma is a common occurrence, comprehending nearly 2.4% of patients who are systemic trauma victims. These injuries vary regarding their gravity and affected structures as they can present themselves exclusively with muscle pain, or even subluxation, luxation and serious fractures.[3]

In this context, traumatic AARS is hardly documented in adults and, for that reason, not many cases could be found in the current literature.[4] It possibly presents itself through cervicalgia (neck pain), headache and neck stiffness, usually with no neurologic deficit. In addition to that, an ipsilateral head inclination, with a chin rotation toward the opposite side of the affected area (also known as "cock-robin" posture) [4] is observed. The treatment is personalized and can be conservative, done with a simple manual traction, or a surgery with fixation for more serious cases.

In the present article, we describe a rare AARS case in a young adult patient, victim of physical aggression caused by strangulation attempt, in which success was obtained through conservative treatment. We would like to point out that the early diagnosis and the correct approach are of primary importance to achieve the best prognosis and evolution of the patient.

Case Report

Patient, female gender, 38 years old, victim of physical aggression caused by strangulation attempt, was admitted in the trauma hospital complaining of intense cervical pain, presenting (during the physical exam) neck lateral flexion to the right, head rotation to the left with a discrete flexion, expressing pain while having her cervical muscle pressed, with no neurologic deficit. A cervical spine computed tomography (CT) scan was requested and an atlantoaxial subluxation type I (Fielding and Hawkins classification) was detected, with C1 right lateral mass anteriorly dislocated in relation to the C2 superior articulation (►**Fig. 1**). As an approach, the patient was kept awake and under anesthesia, and a submental traction, extension and contralateral rotation were chosen. The reduction was successfully achieved, presenting an immediate pain relief (►**Fig. 2**). The patient was released on the next day, with no symptoms and wearing a Philadelphia collar (which she was instructed to keep for 8 weeks). Her cervical spine radiography did not present any evidence of dislocation after the removal of the Philadelphia collar. During the outpatient follow-up, she did not present any new symptoms after 6 months of treatment.

Discussion

Atlantoaxial rotatory subluxation is a rotation deformity caused by the joint dislocation, partial and reducible, including the atlas and the axis. Even being a rare condition, it is life threatening, since it can possibly compromise the vascular structures (vertebral artery) and the nervous structures (upper cervical medulla).[5]

The craniovertebral junction presents a complex organization of bones and articulations structures, including the first and the second cervical vertebrae, and the occipital bone.[6] The atlas is the only vertebra that does not have a body and is not associated to an intervertebral disc: it has a ring format with bilaterally paired lateral mass, united by an anterior and a posterior bow. Its anterior bow has an articular surface for the axis odontoid process, forming the atlantoaxial articulation. Its lateral mass articulates with the occiput condyles in its superior part and with the C2 in its inferior part, forming the atlanto-occipital and atlantoaxial joints, respectively. The atlantoaxial joint is the main responsible for the axial rotation, somehow contributing with the flexion and extension movements. The superior aspect of the C1 lateral mass contains a groove that allows the vertebral artery passage before entering the foramen magnum. This mass might be compromised in cases of AARS with excessive rotation, mainly if combined with anterior dislocation.[1,5]

Epidemiologically, AARS is more commonly found in children, especially if an underlying disorder with ligament laxity is presented. However, AARS induced by trauma in adult patients is an extremely rare condition, as there are not many registers in the scientific literature. Its rareness is the main cause of many neglected cases registered and late diagnosis. Even so, these are the cases where there is a higher probability of more serious presentation and, sometimes, fatal ones, as the trauma mechanism is related to high-energy impact.[4]

Patients with AARS might present as clinic symptomatology: cervicalgia, neck movements limitation and the typical "cock-robin" posture, when the neck is bent to a side, rotated toward the contralateral side and in discrete flexion.[4] The sternocleidomastoid muscle spasm evaluation can distinguish, in severe cases, if the condition is related to rotation due to facet dislocation or neck stiffness due to muscle spasm. When the spasm is on the side where the neck of the patient is directed to, it indicates facet dislocation, while the spasm is found in the contralateral sternocleidomastoid[7] if related to neck stiffness. Nevertheless, the diagnosis can only be confirmed through computed tomography (CT) and magnetic resonance imaging (MRI). The cervical CT is usually used to evaluate the bones structure and classify the AARS. On the flipside, the MRI is more convenient to evaluate the ligaments structure, especially in cases where C1-C2 instability is presented.

Fielding and Hawkins, in the 1970s, in a series of cases consisting of 17 pediatric and adult patients aged 7 to 68 years old (mean 20.6 years old) who presented with irreducible AARS, classified the AARS in 4 types according to the injury level (►**Fig. 3**). In type I, a simple rotatory

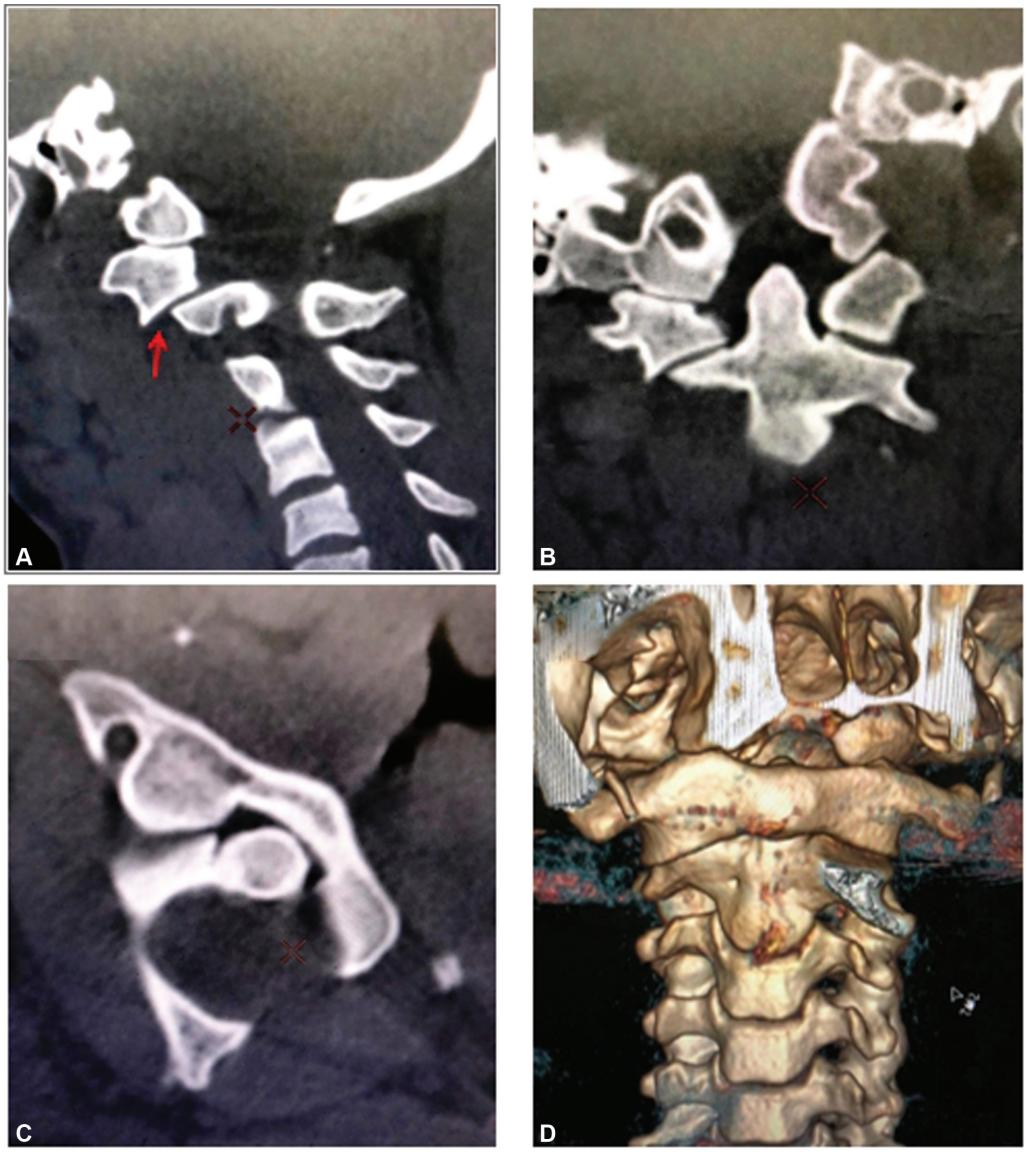

Fig. 1 Computed tomography before reduction: (**A**) Right C1-C2 injured articulation (check the arrow); (**B**) Coronal cut; (**C**) Axial cut with right C1-C2 rotatory luxation; (**D**) Tridimensional reconstruction showing the C1 lateral mass luxation on the right in relation to C2.

dislocation can be observed, $\leq$ 3 mm, with no anterior dislocation, presenting an intact transverse ligament. In type II, the anterior rotatory dislocation is between 3 and 5 mm, the transverse ligament is injured, and the intact articulations play a pivotal role. Meanwhile, in type III, the anterior rotatory dislocation is $>$ 5 mm with both lateral atlantoaxial articulations anteriorly subluxated, with the transversal ligament and the facet capsules injured. Finally, in type IV, a posterior subluxation of both lateral atlantoaxial articulations occurs, there is malfunctioning of the odontoid process and severe instability.[8]

The AARS etiology presents itself differently according to the age range. In pediatric patients, a connection with ligament laxity can be observed, anatomic abnormalities, Down syndrome, rheumatoid arthritis, infection or upper respiratory tract trauma resulting in Grisel syndrome. On the other side, in adult patients, high-energy traumas and injuries are the main causes.[9]

Many strategies to be used on the treatment of these superior cervical spine injuries are available: conservative treatment, reductions through plaster cast or surgery. Independently of the technical choice, the treatment must reduce the dislocation, protect the spinal canal, preserve the vertebral spine mobility as much as possible and, therefore, avoid permanent after-effects. In this way, the treatment choice depends on many criteria, such as the local stability of the injury, the transversal ligament integrity and the C1 posterior bow.[10]

The reducible AARS are usually of the incomplete type, when one of the C1 facet parts keeps contact with the C2 facet. Complete rotations can be reducible under traction, but this is a much lower possibility. Fielding and Hawkins suggested that the reduction during the severe phase is probably complicated due to the capsular and synovial tissue edema and the related muscle spasm. If the abnormal position persists due to a reduction attempt failure, a ligament

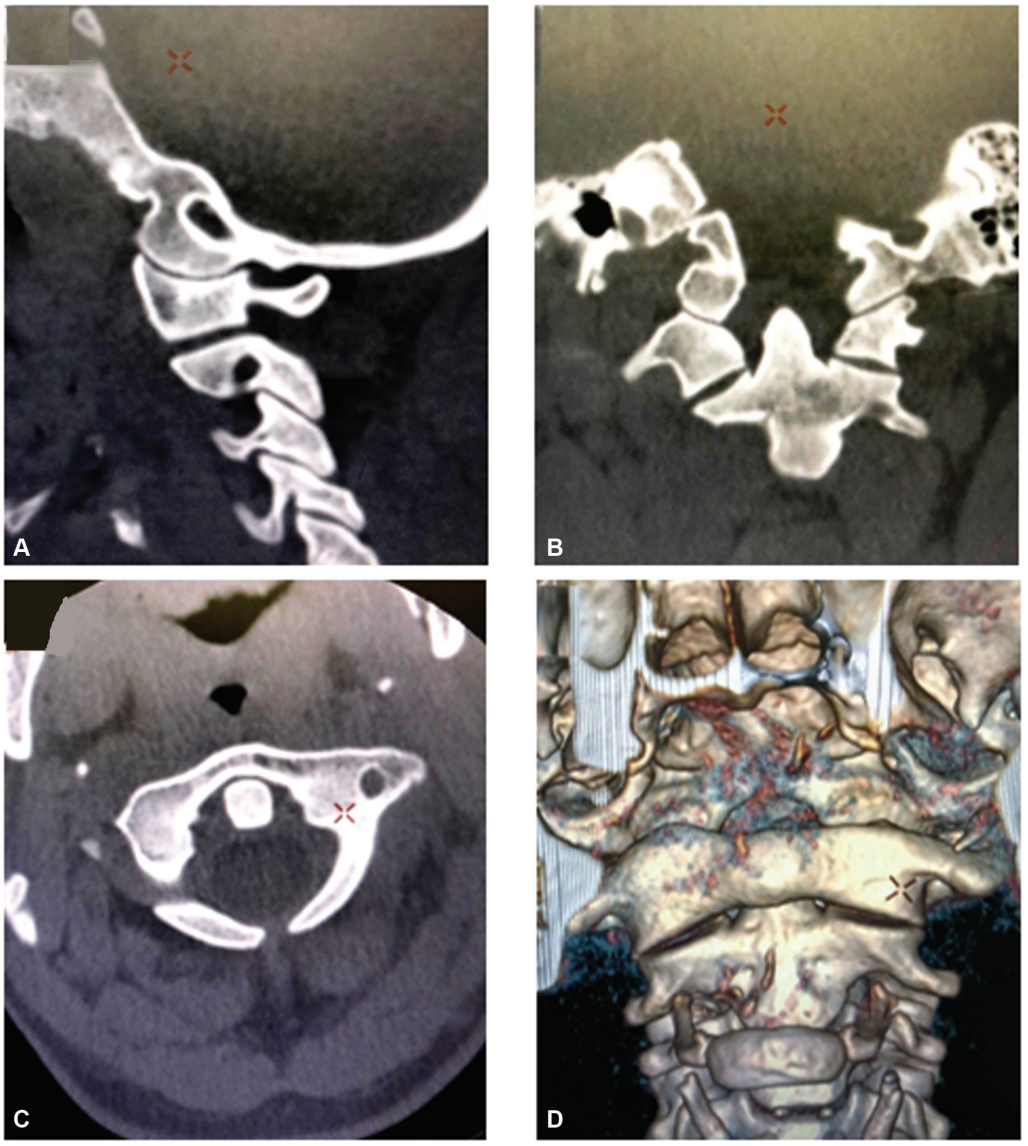

Fig. 2 Computed tomography after reduction: (**A**) Right C1-C2 articulation; (**B**) Coronal cut; (**C**) Axial cut; (**D**) Tridimensional reconstruction of the reduced C1-C2 articulation.

and a capsule contracture are developed, which cause the "fixation" in the dislocated position.[7]

The surgical treatment is indicated for cases in which the subluxation cannot be reduced or for cases when it recurs even after reduction.

The usual fusion is from C1 and C2, unless the patient presents other fractures or conditions, and can be conducted even if the rotation between C1 and C2 is not completely reduced.

In irreducible cases, a transoral atlantoaxial complex release[11,12] accessed through the extreme lateral of the neck,[13] or a direct manipulation of the articulation through the posterior part of the neck,[7] followed or not by cervical serial traction, can be conducted in the first step and, in the second step, the posterior fusion of C1 and C2[14] can be performed.

If treated within the first months, the subluxation can usually be reduced with soft traction and/or cervical manipulation. If the condition has been present for over a month, the traction treatment will have less chances of success. The neck active rotation from the left to the right is stimulated at the moment of the traction. If it is reducible, the traction immobilization is kept for ~ 3 months, with a time variation between 6 and 12 weeks.[14] In our case, despite the age of the patient, a successful nonoperative management was achieved.

The advantages of using the nonoperative treatment are fast subluxation correction, shorter hospitalization and recovery time, absence of surgical procedure, intraoperative injuries and postoperative risks. Overall, atlantoaxial injuries are rare and the treatment is still a challenge. It denotes the importance of an early diagnosis with a proper choice of treatment to be instituted, aiming to a better recovery process and a lower risk of neurological injuries.

Conclusion

In summation, AARS in adults is a rare condition and, in the majority of times, it is related to high-energy traumas, as was the case presented above. The best treatment to be considered

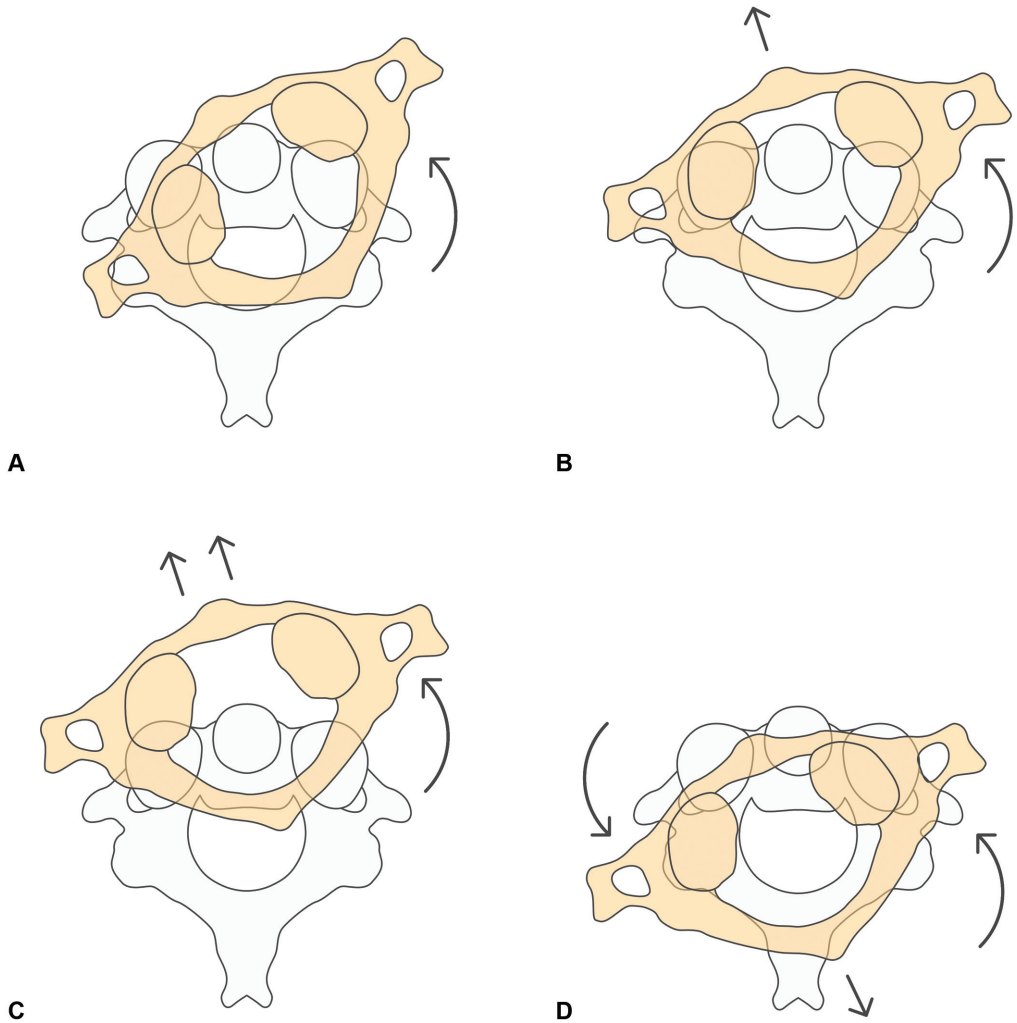

Fig. 3 Fielding and Hawkins classification: (**A**) Type I; (**B**) Type II; (**C**) Type III; (**D**) Type IV.

in this case is the conservative one, taking the early diagnosis and strong power of solvability into account. An early diagnosis is a requirement of extreme importance, due to the fact that a nonsurgical subluxation reduction can be achieved through it, which guarantees a higher level of comfort for the patient and a faster recovery process, also decreasing the complication rates related to late diagnosis.

Patient's Consent

The patient has agreed to the disclosure of her case, as well as of the exam images presented in this document, through a written agreement term.

Conflict of Interests

The authors have no conflict of interests to declare.

References

1 Riascos R, Bonfante E, Cotes C, Guirguis M, Hakimelahi R, West C. Imaging of atlanto-occipital and atlantoaxial traumatic injuries: what the radiologist needs to know. Radiographics 2015;35(07): 2121–2134

2 Tarantino R, Donnarumma P, Marotta N, et al. Atlanto axial rotatory dislocation in adults: a rare complication of an epileptic seizure–case report. Neurol Med Chir (Tokyo) 2014;54(05): 413–416

3 Barimani B, Fairag R, Abduljabbar F, et al. A missed traumatic atlanto-axial rotatory subluxation in an adult patient: case report. Open Access Emerg Med 2019;11:39–42

4 Eghbal K, Rakhsha A, Saffarrian A, Rahmanian A, Abdollahpour HR, Ghaffarpasand F. Surgical Management of Adult Traumatic Atlantoaxial Rotatory Subluxation with Unilateral Locked Facet; Case Report and Literature Review. Bull Emerg Trauma 2018;6 (04):367–371

5 Meyer C, Eysel P, Stein G. Traumatic atlantoaxial and fracture-related dislocation. BioMed Res Int 2019;2019:5297950

6 Goel A, Jain S, Shah A. Management of a case of neglected atlantoaxial rotatory dislocation. Neurol India 2017;65(05):1170–1173

7 Goel A. Torticollis and rotatory atlantoaxial dislocation: A clinical review. J Craniovertebr Junction Spine 2019;10(02):77–87

8 Fielding JW, Hawkins RJ. Atlanto-axial rotatory fixation. (Fixed rotatory subluxation of the atlanto-axial joint). J Bone Joint Surg Am 1977;59(01):37–44

9 Hawi N, Alfke D, Liodakis E, et al. Case report of a traumatic atlantoaxial rotatory subluxation with bilateral locked cervical facets: management, treatment, and outcome. Case Rep Orthop 2016;2016:7308653

10 Peyriere H, Graillon T, Pesenti S, Tropiano P, Blondel B, Fuentes S. Surgical management of post-traumatic atlantoaxial rotatory fixation due to C2 facet fracture: 5 clinical cases. Orthop Traumatol Surg Res 2017;103(01):67–70
11 Schmidek HH, Smith DA, Sofferman RA, Gomes FB. Transoral unilateral facetectomy in the management of unilateral anterior rotatory atlantoaxial fracture/dislocation: a case report. Neurosurgery 1986;18(05):645–652
12 Goto S, Mochizuki M, Kita T, Murakami M, Nishigaki H, Moriya H. Transoral joint release of the dislocated atlantoaxial joints combined with posterior reduction and fusion for a late infantile atlantoaxial rotatory fixation. A case report. Spine 1998;23(13): 1485–1489
13 Crockard HA, Rogers MA. Open reduction of traumatic atlantoaxial rotatory dislocation with use of the extreme lateral approach. A report of two cases. J Bone Joint Surg Am 1996;78(03): 431–436
14 Greenberg MS. Handbook of Neurosurgery. 8ª ed. New York: Thieme; 2016

Deep Vein Thrombosis in the Setting of Neurofibromatosis Type 1: Case Report

Trombose venosa profunda em neurofibromatose tipo 1: Relato de caso

Fernando Guedes[1] Francisco Torrão[1] Gabriel E. Sanches[1] Ana Caroline Siquara-de-Sousa[2] Arno von Ristow[3] Paulo Niemeyer Filho[4]

[1] Department of Surgery, Division of Neurosurgery, Hospital Universitário Gaffrée e Guinle, Escola de Medicina e Cirurgia, Universidade Federal do Estado do Rio de Janeiro (Unirio), Rio de Janeiro, Brazil
[2] Department of Pathology, Hospital Universitário Antônio Pedro, Faculdade de Medicina, Universidade Federal Fluminense (UFF), Niterói, Brazil
[3] Vascular and Endovascular Surgery, Pontifícia Universidade Católica do Rio de Janeiro, (PUC-Rio), Rio de Janeiro, Brazil
[4] Department of Neurosurgery, Instituto Estadual do Cérebro Paulo Niemeyer, Rio de Janeiro, Brazil

Address for correspondence Fernando Guedes, MD PhD, Divisão de Neurocirurgia, Hospital Universitário Gaffrée e Guinle, Escola de Medicina e Cirurgia, Universidade Federal do Estado do Rio de Janeiro (Unirio), Rua Mariz e Barros, 775, Rio de Janeiro, RJ, 20270-901, Brazil (e-mail: neuroguedes@yahoo.com.br).

Arq Bras Neurocir 2021;40(1):107–112.

Abstract

Neurofibromatosis type 1 (NF1) is a genetic syndrome which typically presents with neurological manifestations. Some of the patients may also present with vasculopathies, among which arterial aneurysms and stenosis are the most common. Deep vein thrombosis (DVT) has rarely been described, and, to the best of our knowledge, the present is the first report of DVT due to venous compression by a neurofibroma in the setting of NF1.

This is the case of a 23-year-old male with NF1 who experienced DVT due to compression of the left posterior tibial veins by a large tumor arising from the tibial nerve. The DVT was acutely treated with enoxaparin and then with rivaroxaban. Two months after the diagnosis, Doppler ultrasonography showed partial recanalization and persistence of the DVT. The patient was then referred to neurosurgery for surgical resection of the tumor. There were no complications during the procedure, and the patient did not present postoperative neurological deficits. The final histopathological diagnosis was of a benign neurofibroma. After one year of follow-up with vascular surgery, the patient presented no more episodes of DVT.

In case there is a tumor compressing the deep vessels of the leg and promoting DVT, surgical resection with microsurgical techniques may be curative.

Keywords
- neurofibromatosis 1
- neurofibroma
- venous thrombosis

received August 19, 2020
accepted November 16, 2020
published online January 18, 2021

DOI https://doi.org/10.1055/s-0040-1722244.
ISSN 0103-5355.

Thieme Revinter Publicações Ltda., Rua do Matoso 170, Rio de Janeiro, RJ, CEP 20270-135, Brazil

Resumo

A neurofibromatose tipo 1 (NF1) é uma síndrome genética classicamente associada a manifestações neurológicas. Contudo, alguns dos pacientes apresentam também manifestações vasculares, dentre as quais aneurismas e estenoses arteriais são as mais comuns. Trombose venosa profunda (TVP) associada a NF1 raramente foi descrita, e, pelo que sabemos, este é o primeiro relato de TVP devido a compressão venosa por neurofibroma no contexto de NF1.

Este é o caso de um paciente masculino de 23 anos, com NF1, que apresentou um episódio de TVP devido a compressão das veias tibiais posteriores esquerdas por um grande neurofibroma que surgia do nervo tibial. A TVP foi tratada de forma aguda, com enoxaparina e rivaroxabana. Dois meses após o diagnóstico, a ultrassonografia com Doppler demonstrou recanalização parcial com persistência da TVP. O paciente foi então referido à neurocirurgia para ressecção da massa. Não houve complicações devido ao procedimento, e o paciente não apresentou déficits neurológicos. O diagnóstico histopatológico final foi de um neurofibroma. Após um ano de seguimento com a cirurgia vascular, o paciente não apresentou mais episódios de TVP.

Caso haja um tumor comprimindo os vasos profundos da perna e promovendo TVP, a ressecção cirúrgica com técnicas microcirúrgicas pode ser curativa.

Palavras-chave

- ► neurofibromatose 1
- ► neurofibroma
- ► trombose venosa

Background

Neurofibromatosis type 1 (NF1) is a complex genetic syndrome, in which the gene for neurofibromin (a tumor suppressor protein) suffers a wide range of mutations,[1] resulting in decreased neurofibromin synthesis. The prevalence of NF1 is around 1/3,000,[2,3] and it presents as a systemic disease, with dermatological, cardiovascular, gastrointestinal, orthopedic, central, and peripheral nervous system manifestations.[4,5] One of the cardinal features of NF1 is the predisposition toward the development of certain peripheral nerve sheath tumors (PNSTs). These may be benign, such as neurofibroma, or malignant, such as the malignant peripheral nerve tissue tumor (MPNST).[1] Among the systemic complications of NF1, there is a series of vascular abnormalities, of which arterial manifestations are the most common. Those mostly comprise aneurysms and stenoses of renal, aortic, and mesenteric arteries,[6] with hypertension as the most common clinical feature secondary to these.[4,6,7] Venous manifestations are, in turn, exceedingly rare, and may include venous thrombosis (VT).[8–13]

Literature Search

To investigate previous cases of NF1 with VT, we searched the MEDLINE database for articles written in English with the following MesH keywords and Boolean operators: ("*Neurofibromatosis 1*" AND "*Venous thrombosis*") OR ("*Neurofibromatosis 1*" AND "*Vascular disease*" AND "*Vein*"). While applying article-type filters to select case reports, clinical studies, observational studies, reviews, and systematic reviews, the search yielded 29 individual results, all case reports. In total, there were six case reports of NF1-associated VT.[9–12,14,15] By searching the references of each of these studies, we were able to find another case.[8] In these reports, five patients had aneurysms correlated to the formation of thrombus[9,11,12,14,15] and two did not,[8,10] one of which was secondary to compression by an exostosis.[10] The other 23 articles reported arterial manifestations, vascular malformations, and NF1-associated vascular retinopathy. Some of these cases also presented with venous manifestations,[13,16–23] yet none with thrombosis.

Case Presentation

History and Examination

One year before surgery, a 22-year-old male with NF1 presented with swelling on the left leg, accompanied by pain on walking. Doppler ultrasonography (USG) was performed and showed a large mass over the course of the left tibial nerve. There was no DVT, and the left saphenous veins were tortuous. We decided not to resect the tumor at that moment. The patient was treated with 0.5 g of metamizole twice a day for 1 week, with improvement of the pain.

Ten months later, the patient presented with an acute episode of edema and pain in the left leg. Doppler USG was performed, and showed DVT of the posterior tibial veins and thrombophlebitis of one collateral of the saphenous vein. The patient was hospitalized for 3 days, and underwent treatment with enoxaparin (1.5 mg/kg once a day). A computed tomography angiogram (angio-CT) was performed, and it showed compression of the left fibular and posterior tibial veins by a large tumor arising from the tibial nerve (►**Fig. 1**). Given the setting of NF1, the lesion was presumed to be a neurofibroma. The patient continued treatment with 15 mg of rivaroxaban twice a day for 21 days, and then 20 mg once a day. Doppler USG was again performed two months after the initial diagnosis of DVT, and it showed partial recanalization with persistence of a thrombus (►**Fig. 2**). The saphenous veins were congested and tortuous. The patient was then referred to the authors' care for evaluation by vascular and peripheral nerve surgery.

Upon physical examination, he presented with pain on the left leg (visual analog scale [VAS] = 6), M4+ left foot flexion on the British Medical Research Council (BMRC) scale, and

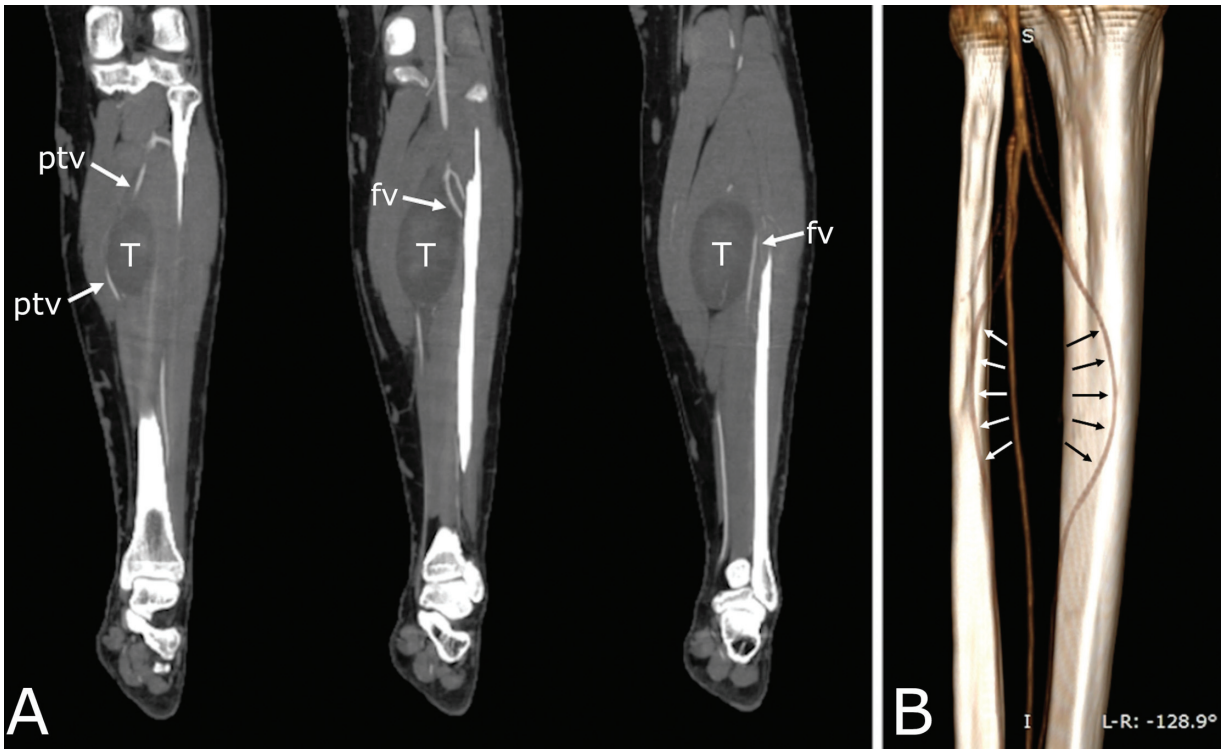

Fig. 1 (A) Three coronal slices of a computed tomography angiogram (angio-CT) showing the compression of the posterior tibial veins by the tumor (T) arising from the tibial nerve. Note the deviation of the course of one of the posterior tibial veins (ptv), compressed against the muscles of the posterior compartment of the leg. One of the fibular veins (fv) appears to be compressed against the fibula. (**B**) 3D reconstruction of an angio-CT from a posterior-medial point of view showing the mass effect of the tumor onto the posterior tibial veins. The white arrows show one of the deviated fibular veins. The black arrows show one of the deviated posterior tibial veins.

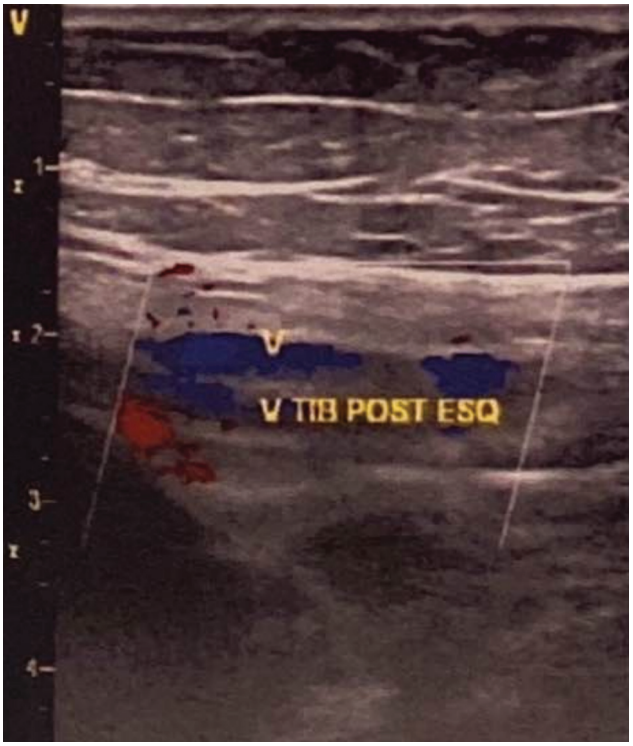

Fig. 2 Doppler ultrasonography of the left posterior tibial veins, performed two months after hospitalization for the treatment of deep vein thrombosis. There is partial recanalization, yet the thrombus is still present. Abbreviation: V TIB POST ESQ, left posterior tibial veins.

plantar hypesthesia. The mass was not palpable, yet the left leg was edematous. There was also a positive Tinel sign over the course of the left tibial nerve.

Electroneuromyography was performed, and it showed a delay in motor conduction with a reduction of amplitude (3.7 µV), and a minor delay in the distal sensitive response of the left sural nerve. Magnetic resonance imaging (MRI) was then also performed to better evaluate the tumor's relationship to neighboring structures and to help in the preoperative planning (►**Fig. 3**). Even though the lesion was large (96 mm on its largest axis), it presented predominantly high ($> 1.3 \times 10^{-3}$ mm/s^2) apparent diffusion coefficient (ADC) values on diffusion-weighted imaging (DWI). This, along with the absence of features suggestive of malignancy (that is, peripheral enhancement, perilesional edema, intratumoral cystic changes), favored the hypothesis of a benign neurofibroma.[24,25] There were no signs of muscle denervation.

Surgery

Given the presence of a large tumor inside the left tibial nerve, and the evidence of the persistence of DVT on Doppler USG, surgical resection of the tumor with decompression of the vessels was then decided. With the aid of loupes, a classic approach to the left tibial nerve through the medial aspect of the leg was performed, with mobilization of the gastrocnemius and soleus muscles. Gentle progressive dissection was then performed, with individualization of the compressed deep

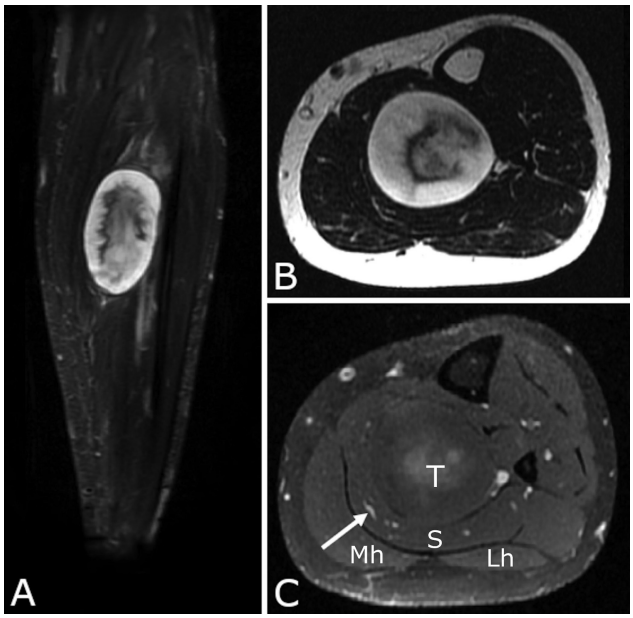

Fig. 3 (**A**) Coronal Short tau inversion recovery weighted (STIR-weighted) magnetic resonance imaging (MRI) without contrast of a large heterogeneous lesion (96 × 56 × 49 mm) arising from the left tibial nerve and compressing the deep vessels of the posterior compartment of the left leg. The lesion presents with well-defined borders, and there are no apparent signs of tissue invasion or perilesional edema. (**B**) Axial T2-weighted MRI without contrast of the lesion showing predominantly high signal intensity and a central region with lower signal intensity. (**C**) T1-weighted MRI with contrast showing discrete and heterogeneous central enhancement. The arrow shows one of the posterior tibial veins compressed against the soleus muscle fascia. Abbreviations: Lh, lateral head of the gastrocnemius; Mh, medial head of the gastrocnemius; MRI, magnetic resonance imaging; S, soleus muscle; T, tumor..

vessels of the leg. After the complete exposure of the tumor (and of the healthy tibial nerve proximally and distally to the mass), electrical mapping of its surface was conducted with the aid of intraoperative electrical stimulation to identify an area devoid of functional fascicles. With the aid of microsurgical techniques under microscopy, a sharp opening of the pseudotumoral capsule was performed in this "electrically-silent" area. An intraoperative biopsy was then performed, and it revealed a probable neurofibroma, without characteristics of malignancy. The pseudotumoral capsule could be differentiated from the true tumor capsule by its color and consistency (respectively white-grayish and tough, against yellowish and soft), and a cleavage plane was established in a fascicle-free corridor. A circumferential dissection was performed with complete isolation of the tumor toward its proximal and distal poles to identify the tumor's fascicle of origin (in this case, only one). The fascicles that entered and exited the tumor were not functional, and they were sectioned. The huge tumoral mass was resected en bloc, with the preservation of the functional fascicles. The borders of the nerve were gently everted to look for any residual tumor inside the nerve ("open book" maneuver) (►**Fig. 4**).

Follow-up

No postoperative complications were observed. The patient left the hospital with the same deficit as before (M4+ foot flexion) and reduction of pain (VAS = 3). He was treated with pregabalin as soon as was discharged (75 mg 3 times a day during the first month; twice, during the second month; and once, during the third month), and was directed to physiotherapy treatment after the stitches were removed. He was followed up in the outpatient clinic, and, after 3 months, recovered to M5 foot flexion and presented with no more

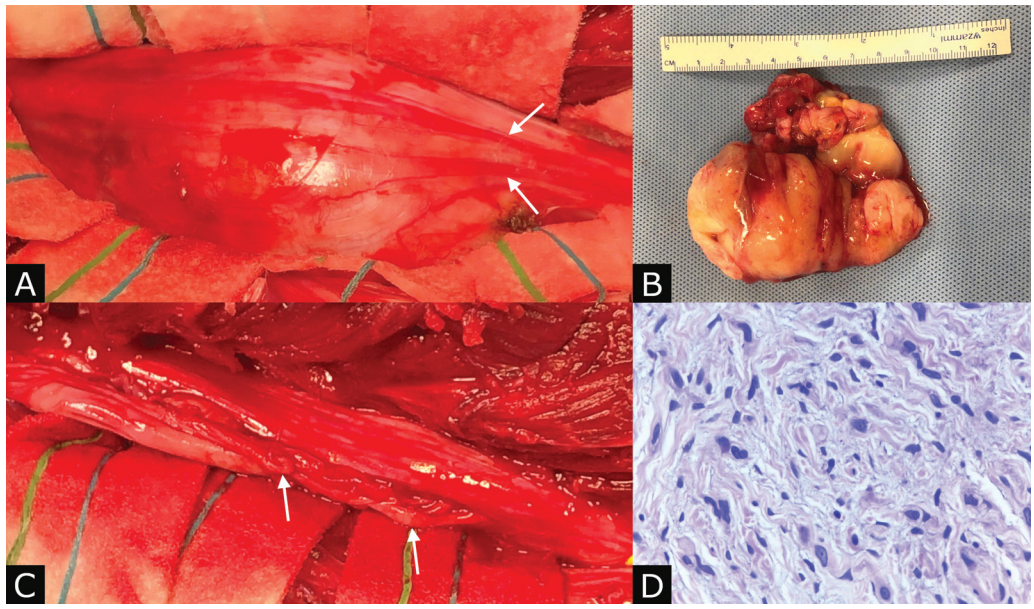

Fig. 4 (**A**) Exposure of the tumor. The arrows show functional fascicles dislocated by the mass. (**B**) Surgical aspect after resection of the lesion. The arrows show the preserved functional fascicles inside the tibial nerve. (**C**) Tumor resected en bloc. (**D**) Hematoxylin and eosin, 400x. Benign neurofibroma showing hypocellular proliferation of slightly elongated spindle cells, with wavy and hyperchromatic nuclei; in some, the nucleolus is evident. Collagen and a slight amount of mucoid material are observed among the neoplastic cells, as well as rare mononuclear inflammatory cells. The specimen presented no necrosis, and there were rare nuclear atypia.

pain, so that pregabalin was discontinued. Six months after the surgery, the patient was also evaluated by vascular surgery, and no further episodes of DVT were observed.

Discussion

In the present study, we report a case of a patient with NF1 who experienced DVT due to compression of posterior tibial veins by a neurofibroma in the posterior compartment of the leg. To the best of our knowledge, the present is the first report of VT secondary to external compression by neurofibroma in the setting of NF1.

The prevalence of NF1 vasculopathy has been estimated to be of at least 8% in a study[26] conducted with 181 pediatrics patients with NF1. Its mechanisms are yet not completely understood.[4,27–29] The vascular manifestations of NF1 appear to increase morbidity and mortality. A nationwide study[30] conducted in the United States with death certificates showed that NF1 patients younger than 30 years of age who died were more than twice as likely to have been diagnosed with vascular disease when compared with those without NF.

The vasculopathy pathogenesis of NF1 has been shown to involve a series of events caused by dysfunction of the synthesis of neurofibromin (the encoded protein of the NF1 gene), which physiologically works as a downregulator of the Ras cascade signaling. Without the downregulation, the Ras signaling pathway augments cell proliferation in the vascular endothelium (with enhanced expression of cyclin D and cells more frequently entering the cell cycle).[28] It also causes smooth-muscle hyperplasia[7] and inflammation.[29] The cell lineage that appears to be key in this pathogenesis is the bone-marrow-derived cell (BMDC). It has been shown that the inactivation of the NF1 gene in this cell lineage in mice was both sufficient and necessary to cause neointima formation and evidence of vascular inflammation similar to that observed in NF1 knockout mice.[29]

Although the manifestations of NF1 vasculopathy are mostly arterial, patients may also present with venous rupture, venous aneurysms, and/or VT.[8–12,31] It has been shown that the absence of NF1 in vitro is sufficient for human venous endothelium cells to undergo autonomous proliferation.[28] This endothelial dysfunction has been extensively implicated in the pathogenesis of VT.[32–35] In this setting, the venous endothelium also shows altered vascular morphogenesis, which helps to explain the vascular morphological alterations in NF1 patients (that is, stenosis and aneurysms),[6,9,12,14,19,31] some of which may further increase the risk of VT (that is, venous aneurysm).[36–38]

We have found four reports of NF1 patients presenting with venous aneurysm and an associated VT. Seinturier et al.[12] presented a case in which a 64-year-old woman, with NF1, developed pulmonary embolism secondary to a thrombosed venous femoral aneurysm. There are other 3 case reports of NF1 patients younger than 50 years of age who presented with internal jugular thrombosis secondary to aneurysmal degeneration.[9,11,14]

Lehrnbecher et al.[8] reported a case in which a 4-year-old boy was diagnosed with NF1 systemic vasculopathy, including thrombosis of the right posterior tibial vein, without evidence of a correlated aneurysm or compression/infiltration by a tumor.

None of the seven reports described compression or infiltration of venous structures by a neurofibroma. Nonetheless, DVT in NF1 patients may also be caused via extrinsic compression by these tumors, as blood stasis has also been implicated in thrombogenesis.[33,39] This, we think, contributed to the process of thrombogenesis in the present case, given that the tumor arose from the tibial nerve, in a tight region in the posterior compartment of the leg.

Deep vein thrombosis secondary to external compression by tumors has been reported in other settings such as the superior vena cava, and pulmonary and iliofemoral veins.[40–42] It has been reported once in the setting of NF1, by an exostosis, in the popliteal vein.[10] One study[43] conducted with patients harboring high-grade non-Hodgkin lymphoma showed that venous compression by the tumor was present in 51% of patients with DVT. Given the higher prevalence of neurofibromas in NF1 patients, it is thus reasonable to assume that DVT secondary to tumoral compression may also have a higher prevalence in this population.

Conclusion

Clinicians should be alert to signs and symptoms suggestive of DVT in NF1 patients, as NF1 seems to favor venous endothelium dysfunction. Tumors may also compress or infiltrate the veins, promoting VT through blood stasis, when there is venous compression; or through endothelial damage, when infiltration occurs. In case there is a tumor compressing venous structures and promoting DVT, surgical resection with microsurgical techniques may be curative and able to preserve neurological function.

Conflict of Interests
The authors have no conflict of interests to declare.

References

1 Rosenbaum T, Wimmer K. Neurofibromatosis type 1 (NF1) and associated tumors. Klin Padiatr 2014;226(6-7):309–315
2 Friedman JM. Epidemiology of neurofibromatosis type 1. Am J Med Genet 1999;89(01):1–6
3 Uusitalo E, Leppävirta J, Koffert A, et al. Incidence and mortality of neurofibromatosis: a total population study in Finland. J Invest Dermatol 2015;135(03):904–906
4 Hirbe AC, Gutmann DH. Neurofibromatosis type 1: a multidisciplinary approach to care. Lancet Neurol 2014;13(08):834–843
5 Gutmann DH, Ferner RE, Listernick RH, Korf BR, Wolters PL, Johnson KJ. Neurofibromatosis type 1. Nat Rev Dis Primers 2017;3(01):17004
6 Oderich GS, Sullivan TM, Bower TC, et al. Vascular abnormalities in patients with neurofibromatosis syndrome type I: clinical spectrum, management, and results. J Vasc Surg 2007;46(03):475–484
7 Friedman JM, Arbiser J, Epstein JA, et al. Cardiovascular disease in neurofibromatosis 1: report of the NF1 Cardiovascular Task Force. Genet Med 2002;4(03):105–111
8 Lehrnbecher T, Gassel AM, Rauh V, Kirchner T, Huppertz HI. Neurofibromatosis presenting as a severe systemic vasculopathy. Eur J Pediatr 1994;153(02):107–109

9 Belcastro M, Palleschi A, Trovato RA, Landini R, Di Bisceglie M, Natale A. A rare case of internal jugular vein aneurysmal degeneration in a type 1 neurofibromatosis complicated by potentially life-threatening thrombosis. J Vasc Surg 2011;54(04):1170–1173
10 Kwiatkowska W, Ferenc S, Romaszkiewicz P, et al. Deep vein thrombosis caused by an exostosis in an adolescent patient with peripheral neurofibromatosis type 1. Vasa 2015;44(03): 233–236
11 Dova S, Ktenidis K, Karkos P, et al. A rare case of a spontaneous neck hematoma in a patient with type 1 neurofibromatosis. Auris Nasus Larynx 2016;43(05):591–594
12 Seinturier C, Blaise S, Thony F, Magne JL, Pernod G. A Femoral Common Vein Aneurysm in a Patient with Neurofibromatosis Syndrome Type 1. Ann Vasc Surg 2017;40:299.e7–299.e9
13 Mori F, Kawai M, Sato E, Igarishi S, Hikichi T, Yoshida A. Branch retinal vein occlusion in a Japanese patient with neurofibromatosis 1. Jpn J Ophthalmol 2001;45(06):634–635
14 Nopajaroonsri C, Lurie AA. Venous aneurysm, arterial dysplasia, and near-fatal hemorrhages in neurofibromatosis type 1. Hum Pathol 1996;27(09):982–985
15 Hiraki T, Higashi M, Goto Y, et al. A rare case of internal jugular vein aneurysm with massive hemorrhage in neurofibromatosis type 1. Cardiovasc Pathol 2014;23(04):244–247
16 Valdivia AR, Gandarias C. Neck Swelling in a Type 1 Neurofibromatosis Patient. Eur J Vasc Endovasc Surg 2019;58(03):414
17 Imahori T, Fujita A, Hosoda K, Kohmura E. Endovascular Internal Trapping of Ruptured Occipital Artery Pseudoaneurysm Associated with Occipital-Internal Jugular Vein Fistula in Neurofibromatosis Type 1. J Stroke Cerebrovasc Dis 2016;25(05):1284–1287
18 Bartline PB, McKellar SH, Kinikini DV. Resection of a Large Innominate Vein Aneurysm in a Patient with Neurofibromatosis Type 1. Ann Vasc Surg 2016;30:157.e1–157.e5
19 Jun YJ, Kim JM, Kim JA, Lee JH, Kim SM, Kim YJ. Venous malformation associated with type 1 neurofibromatosis: a case report. ANZ J Surg 2017;87(11):945–946
20 De Caridi G, Massara M, Spinelli F. Uncommon case of symptomatic left renal vein compression caused by neurofibroma. Asian Cardiovasc Thorac Ann 2016;24(05):492–492
21 Ku Y-K, Chen H-W, Chen H-W, Fu C-J, Chin S-C, Liu Y-C. Giant extracranial aneurysms of both internal carotid arteries with aberrant jugular veins in a patient with neurofibromatosis type 1. AJNR Am J Neuroradiol 2008;29(09):1750–1752
22 Hinsch N, Kriener S, Ritter R-G, Holzer K. Fatal haemorrhage due to extensive fragility of medium- and large-sized arteries and veins in a young patient with neurofibromatosis 1. Cardiovasc Pathol 2008; 17(02):108–112
23 Zaret CR, Choromokos EA, Meisler DM. Cilio-optic vein associated with phakomatosis. Ophthalmology 1980;87(04):330–336
24 Wasa J, Nishida Y, Tsukushi S, et al. MRI features in the differentiation of malignant peripheral nerve sheath tumors and neurofibromas. AJR Am J Roentgenol 2010;194(06):1568–1574
25 Ahlawat S, Blakeley JO, Rodriguez FJ, Fayad LM. Imaging biomarkers for malignant peripheral nerve sheath tumors in neurofibromatosis type 1. Neurology 2019;93(11):e1076–e1084
26 Kaas B, Huisman TAGM, Tekes A, Bergner A, Blakeley JO, Jordan LC. Spectrum and prevalence of vasculopathy in pediatric neurofibromatosis type 1. J Child Neurol 2013;28(05):561–569
27 Lin AE, Birch PH, Korf BR, et al. Cardiovascular malformations and other cardiovascular abnormalities in neurofibromatosis 1. Am J Med Genet 2000;95(02):108–117
28 Bajaj A, Li Q, Zheng Q, Pumiglia K. Loss of NF1 Expression in Human Endothelial Cells Promotes Autonomous Proliferation and Altered Vascular Morphogenesis. Pizzo SV, editor. PLoS One 2012; 7(11):e49222
29 Lasater EA, Li F, Bessler WK, et al. Genetic and cellular evidence of vascular inflammation in neurofibromin-deficient mice and humans. J Clin Invest 2010;120(03):859–870
30 Rasmussen SA, Yang Q, Friedman JM. Mortality in neurofibromatosis 1: an analysis using U.S. death certificates. Am J Hum Genet 2001;68(05):1110–1118
31 Delvecchio K, Moghul F, Patel B, Seman S. Surgical resection of rare internal jugular vein aneurysm in neurofibromatosis type 1. World J Clin Cases 2017;5(12):419–422
32 Blann AD. How a damaged blood vessel wall contibutes to thrombosis and hypertenasion. Pathophysiol Haemost Thromb 2003;33(5-6):445–448
33 Mackman N. New insights into the mechanisms of venous thrombosis. J Clin Invest 2012;122(07):2331–2336
34 Poredos P, Jezovnik MK. Endothelial Dysfunction and Venous Thrombosis. Angiology 2018;69(07):564–567
35 Wang M, Hao H, Leeper NJ, Zhu LEarly Career Committee. Thrombotic Regulation From the Endothelial Cell Perspectives. Arterioscler Thromb Vasc Biol 2018;38(06):e90–e95https://www.ahajournals.org/doi/10.1161/atvbaha.118.310367 [Internet]
36 Chahlaoui J, Julien M, Nadeau P, Bruneau L, Roy P, Sylvestre J. Popliteal venous aneurysm: a source of pulmonary embolism. AJR Am J Roentgenol 1981;136(02):415–416
37 Calligaro KD, Ahmad S, Dandora R, et al. Venous aneurysms: surgical indications and review of the literature. Surgery 1995; 117(01):1–6
38 Gillespie DL, Villavicencio JL, Gallagher C, et al. Presentation and management of venous aneurysms. J Vasc Surg 1997;26(05): 845–852
39 Esmon CT. Basic mechanisms and pathogenesis of venous thrombosis. Blood Rev 2009;23(05):225–229
40 Liaw C-C, Chang H, Yang T-S, Wen M-S. Pulmonary Venous Obstruction in Cancer Patients. J Oncol 2015;2015:210916
41 Liao T-Y, Hsu H-C, Wen M-S, Juan Y-H, Hung Y-H, Liaw C-C. Iliofemoral Venous Thrombosis Mainly Related to Iliofemoral Venous Obstruction by External Tumor Compression in Cancer Patients. Case Rep Oncol 2016;9(03):760–771
42 Friedman T, Quencer KB, Kishore SA, Winokur RS, Madoff DC. Malignant Venous Obstruction: Superior Vena Cava Syndrome and Beyond. Semin Intervent Radiol 2017;34(04):398–408
43 Ottinger H, Belka C, Kozole G, et al. Deep venous thrombosis and pulmonary artery embolism in high-grade non Hodgkin's lymphoma: incidence, causes and prognostic relevance. Eur J Haematol 1995;54(03):186–194

ISSN 0103-5355

Instructions to Authors

Thank you for contributing to Brazilian NeuroSurgery (BNS). Please read the instructions carefully and observe all the directions given. Failure to do so may result in unnecessary delays in publishing your article. There are no submission charges to submit your manuscript to this journal..

Brazilian Neurosurgery (Arquivos Brasileiros de Neurocirurgia), an official journal of the Brazilian Society of N**eurosurgery (Sociedade Brasileira de Neurocirurgia) and Portuguese Language Neurosurgery Society (Sociedades de Neurocirurgia de Língua Portuguesa)**, aims to publish scientific works in Neurosurgery and related fields, unpublished and exclusive. As from January 2018, the journal **only publishes papers written in English with English and Portuguese abstracts**. Manuscripts must conform to acceptable English usage.

Submitted articles shall be placed as one of the following categories:

- ***Original:*** result of clinical, epidemiological or experimental research. Abstracts of theses and dissertations.
- ***Review:*** review and update synthesis of specific themes, with critical analysis and conclusions. Databases and the period range must be specified.
- ***Case Report:*** presentation, analysis and discussion of cases that present relevant interest.
- ***Technical Note:*** note on surgery techniques and/or surgical instruments.
- ***Miscellaneous:*** neurosurgery history, professional practice, medical ethics and other pertinent matters to the journal purpose.
- ***Letter to the Editor:*** critics and comments presented in a brief ethical and instructive manner about published content in this journal. The copyright is safe to authors of the aimed subject. Letters, when accepted, will be published with authors reply.

General standards for publishing

- Article files for publishing must be submitted to the Editor, via https://www.editorialmanager.com/bns/.
- All articles will have a double blinded peer-review process, and no Article Publishing Charge (APC) – society funded. More about Open Access at http://open.thieme.com.
- Only new unpublished manuscripts will be acceptable. Submitted articles **must not be** fully or partially submitted to any other journal.
- The editorial board may reject or suggest changes in order to improve the clarity and structure of the text and maintain uniformity with the journal policy.
- Copyrights of articles published in the journal will belong exclusively to the **Brazilian Neurosurgery and Thieme Revinter Publicações Ltda**. The reproduction of articles or illustrations without prior consent is prohibited.

Standards for submission

Authors must send the following files:

1. Pub Letter (formal text file) stating the article has not yet been published partially or fully or submitted concomitantly to other journal. Must contain Article Title, authors names in full (without abbreviations) and affiliations in ascending order of hierarchy and corresponding author (full address for correspondence, email, telephone).

2. Blind Manuscript (text file must contain article name in English, article name in Portuguese, abstracts in English and Portuguese, without identification of authors and affiliations).

3. Figures (*Tiff, Jpeg, Pdf, Indd*) sent in separate files with minimum resolution of 300 dpi.

4. Tables, charts and graphics (text file) sent separately.

Standards for articles structure

Articles must be structured with all the following items and paginated accordingly:

1. Title page: article title both in Portuguese and English; full name of all authors; academic or professional affiliation of each author; institutions names where the study took place; running title; corresponding author name, degree, full address, e-mail and phone number; followed by **ICMJE COI forms** (COI forms are available at: http://www.icmje.org/conflicts-of-interest/).

2. Abstract: original articles need structured abstract with 250 words at the most: **objective, methods, results and conclusions**; review articles, case reports, technical notes and miscellaneous need no structured abstract. Following the abstract comes keywords (six at the most), based on MeSH (Medical Subject Headings), published in Medline and available at: www.ncbi.nlm.nih.gov/mesh/.

3. Portuguese abstract: Portuguese version of title, abstract and keywords based on DeCS (Descritores em Ciências da Saúde, http://decs.bvs.br).

4. Main text: introduction; casuistry or material and methods; results; discussion; conclusion; acknowledgments.

5. References: number references as they are **first cited** in the text with Arabic numerals. Use Vancouver style; list all authors until the sixth, using *et al*. after the third when more than six; when reference authors are cited in the text cite the first and et al. for references with more that two authors; unpublished data or personal communication must be cited as such between parentheses and cannot be listed as reference; use journal abbreviation from *Index Medicus*; use the following examples:

Journal Article

Agner C, Misra M, Dujovny M, Kherli P, Alp MS, Ausman JI. Experiência clínica com oximetria cerebral transcraniana. Arq Bras Neurocir 1997;16(1):77–85

Book Chapter

Peerless SJ, Hernesniemi JA, Drake CG. Surgical management of terminal basilar and posterior cerebral artery aneurysms. In: Schmideck HH, Sweet WH, editors. Operative neurosurgical techniques. 3rd ed. Philadelphia: WB Saunders; 1995:1071–86.

Book

Melzack R. The puzzle of pain. New York: Basic Books Inc Publishers; 1973.

Theses and dissertations

Pimenta CAM. Aspectos culturais, afetivos e terapêuticos relacionados à dor no câncer. [thesis]. São Paulo: Escola de Enfermagem da Universidade de São Paulo; 1995.

Annals and other congresso publications

Corrêa CF. Tratamento da dor oncológica. In: Corrêa CF, Pimenta CAM, Shibata MK, editores. Arquivos do 7º Congresso Brasileiro e Encontro Internacional sobre Dor; 2005 outubro 19–22; São Paulo, Brasil. São Paulo: Segmento Farma. pp. 110–20.

Available Article in ahead of print

International Committee of Medial Journal Editors. Uniform requirements for manuscripts submitted to biomedical journals. Writing and editing for biomedical publication. Updated October 2007. Available at: http://www.icmje.org. Access in: June 12, 2008.

6. Tables and charts: numbered by Arabic numerals according to its citation in the text; edited in double space, using separate sheets per table/chart; title right above; note, abbreviations, legends must follow right under; introduce only essential tables and charts; files must come separately.

8. Figures: digital formats (TIFF, JPEG, PDF, Indd) with minimum resolution of 300 dpi (trim 7.5 or 15 cm).

9. Legends and captions: numbered by Arabic numerals according to its citation in the text; edited in double space, using separate files; identify eventual labels present in the figure (ar-

rows, characters, lines etc.); image previously published must have publisher authorization and credits.

10. Ethics standards: No data or image identifying a patient can be used without ***formal consent*** (**patient permission forms are available at: www.thieme.com/journal-authors**); studies using human beings or animal trials must follow ethical standards from the International Committee of Medical Journals Editors – ICMJE, as well as approval of original institution's Ethics Committee; conflicts of interest must have a ICMJE form filled in by all authors (available at: http://www.icmje.org/conflicts-of-interest/); commercial marks should be avoided; authors are the sole responsible for opinions and concepts in the published articles, as well as for the reference accuracy.

11. The editors and Thieme combat plagiarism, double publication, and scientific misconduct with the software CrossCheck powered by iThenticate. Your manuscript may be subject to an investigation and retraction if plagiarism is suspected.

12. Authors must disclose any financial relationship(s) at the time of submission, and any disclosures must be updated by the authors prior to publication. Information that could be perceived as potential confl ict(s) of interest must be stated. This information includes, but is not limited to, grants or funding, employment, affiliations, patents, inventions, honoraria, consultancies, royalties, stock options/ownership, or expert testimony.

13. Other information: PDF proof will be sent to corresponding author for eventual queries and/or approval within 72 hours; except measure units, acronyms must be spelled out after its first time mentioned.

Editorial Contacts:

Thieme Publishers - Production Coordinator
Leonardo Vidal
Leonardo.vidal@thieme.com.br
T: +55 21 2563 9734

Thieme Publishers - Acquisitions Editor
Ana Paula Canel Bluhm, MSc., PhD
Ana.Bluhm@thieme.com.br
T: +55 11 3362 2464